

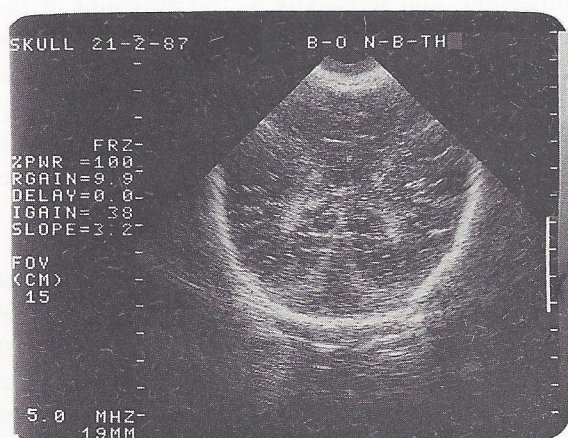
Answers To Medical Quiz

CASE No. 1

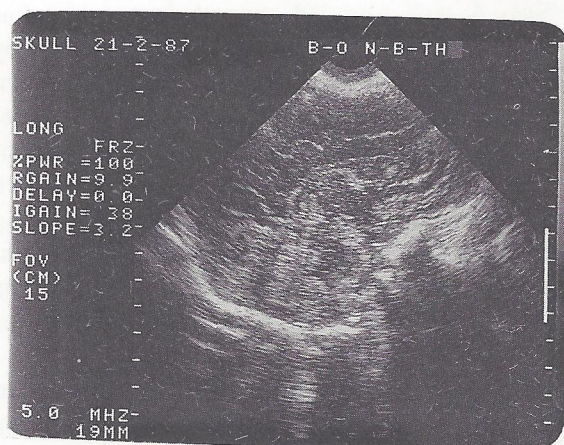
- Answer 1.** These are skin neurofibromata.
Answer 2. Multiple cafe-au-lait patches and axillary freckling.
Answer 3. Neurofibromatosis (von Recklinghausen's disease).
Answer 4. Scoliosis; mild mental retardation (10%) seizures (3%); spinal cord or root compression; CNS tumor (5%) pseudoarthrosis of the tibia (1%) pheochromocytoma (< 1%).

CASE NO. 2

- Answer 1.** The cranial cavity is transonic. An irregular cortical mantle near the base posteriorly is present. Also present is an intact cerebellum. The falx (interhemispheric fissure) is absent. Coronal (A) and sagittal (B) ultrasounds of a normal skull are provided for comparison.



- Answer 2.** Holoprosencephaly.
Answer 3. Hydrocephalus and hydranencephaly. In hydrocephalus, the falx is present and the ultrasonic finding is that of bilateral cystic intracranial structures. In hydranencephaly, the falx is either absent or incomplete, the cerebellum is present but there is no cortical/cerebral tissue.
Answer 4. Death is usual within 6 months.



REFERENCE :

- Carrasco CR, et al. An algorithm for prenatal ultrasound diagnosis of congenital CNS abnormalities. *J Ultrasound Med* 1985;4:163-168.

Anyone interested in presenting a Quiz
for publication should contact
Dr. Akbar Mohsin Mohammad on Tel. : 250662.