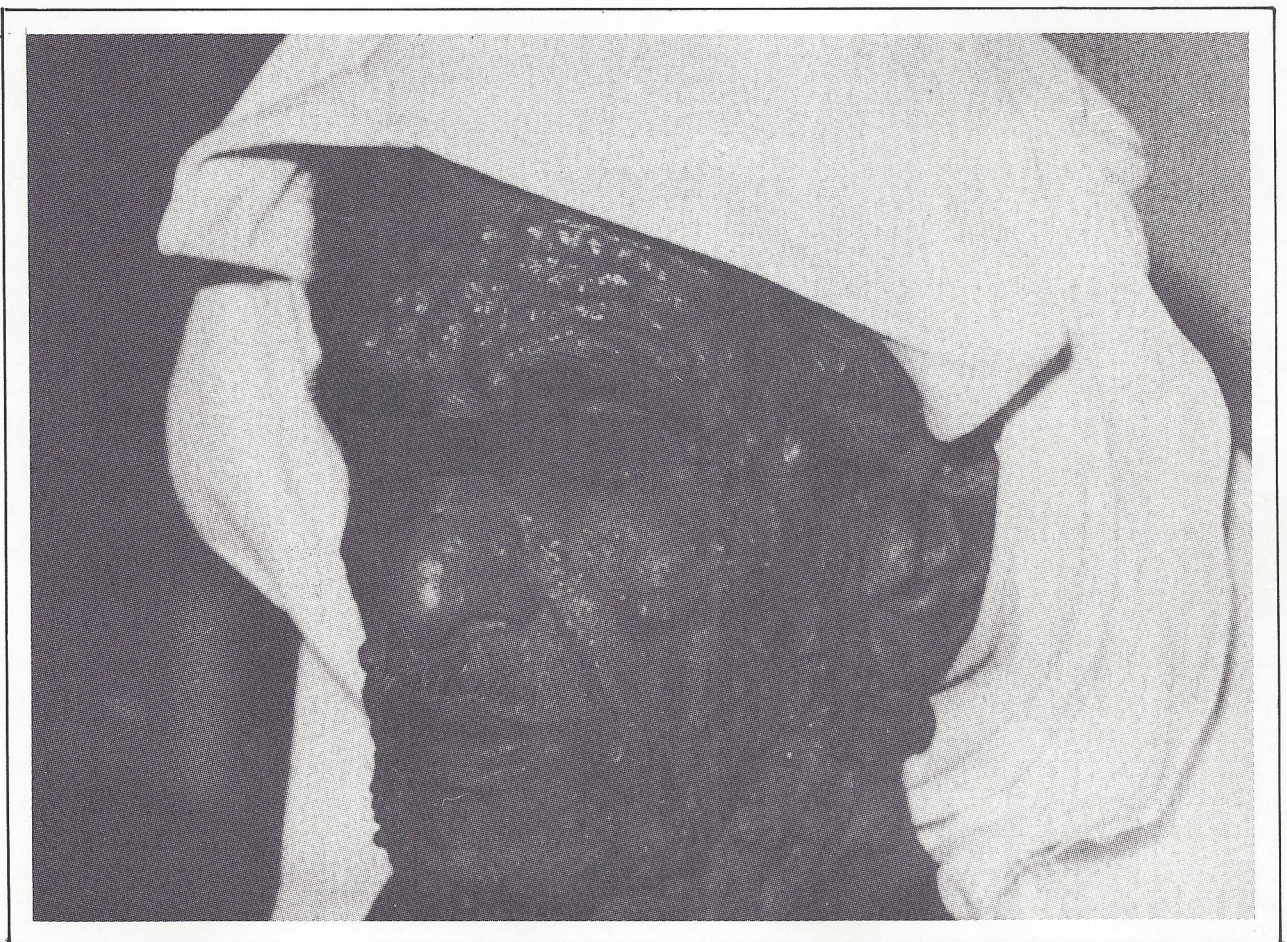

# MEDICAL QUIZ

Prepared By Akbar Mohsin Mohammed\*  
Najeeb S. Jamsheer\*\*

## CASE No. 1

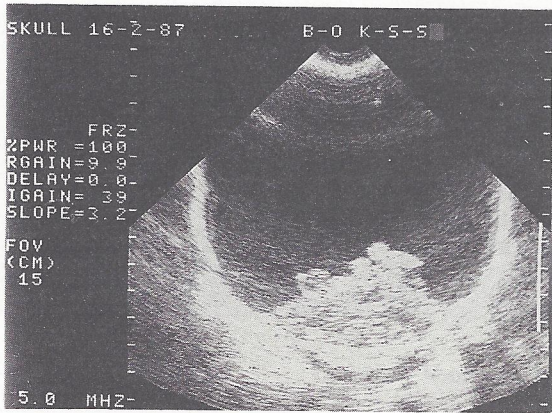


\*Chairman, Paediatric Dept  
Salmaniya Medical Centre  
State of Bahrain

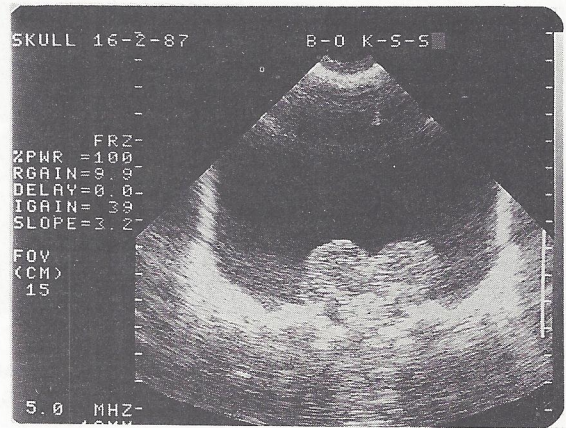
\*\*Chairman, Radiology Dept  
Salmaniya Medical Centre  
State of Bahrain

- Question 1.** What are these skin lesions ?
- Question 2.** What other skin findings are seen in this disease ?
- Question 3.** What is the diagnosis ?
- Question 4.** What are the major complications ?

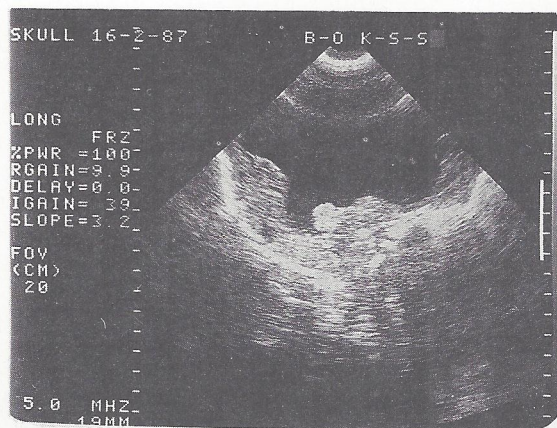
**CASE No. 2**



**A**



**B**



**C**

Coronal (A, B) and sagittal (C) of a skull ultrasound on a few days old infant with history of abnormal progressive increase in head circumference.

**Question 1.** What is (are) the abnormality(ies) ?

**Question 2.** What is the diagnosis ?

**Question 3.** What are the main differential diagnoses ?

**Question 4.** What is the prognosis ?

(Answers on Page 47)