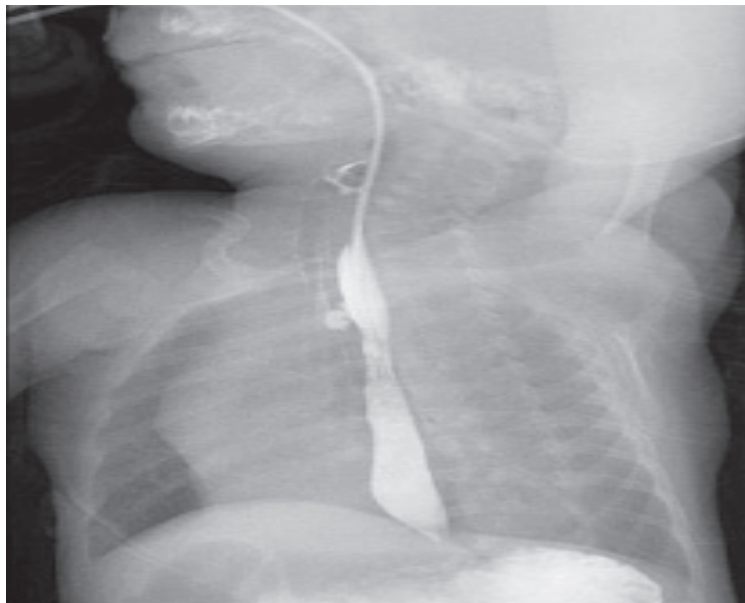


Medical Quiz

Saeed Alhindi, MD, CABS, FRCSI*

A full-term male infant, product of normal vaginal delivery, was born with a high anorectal malformation. The patient underwent laparotomy with a sigmoid colostomy and mucous fistula. He developed sudden choking with significant abdominal distention immediately after feeding on the third postoperative day. Look at the figure below and answer the following questions:



- Q1. Mention the radiological test and describe the findings.
- Q2. What other diagnostic procedure is needed in this case?
- Q3. What is the diagnosis?

Answers on page 259

* Assistant Professor, Arabian Gulf University
Consultant Pediatric Surgeon, Salmaniya Medical Complex
P.O. Box 12
Kingdom of Bahrain
E-mail: sjalhindi@yahoo.com, sjalhindi@gmail.com