

## Status Epilepticus: An Intractable Case with a Successful Outcome

Mohamed Mourad Hashim, MD, DESA\* Karim Abdel Hakim, MBBCh, MD\*\* Mohammed Elbahr, MBBCh, MSc\*\*\*  
Mahmoud Etman, MBBCh, MSc\*\*\* Eamon Tierney, MB, FFARCSI, FJFICMI\*\*\*\*

**A thirty-two-year-old male patient with a history of fever presented with generalized tonic-clonic convulsions and a low Glasgow Coma Score (GCS); an endotracheal tube was inserted to secure his airway.**

**The patient had malignant generalized tonic-clonic convulsions for six weeks, he was diagnosed as status epilepticus (SE) on the electroencephalogram (EEG). Achieving control was very difficult even with various antiepileptic medications. More than six antiepileptic drugs were used in addition to continuous infusion of anesthetic medications to control the convulsions.**

**After four-months in the ICU, the patient became fully conscious with no residual neurological deficit and good control of convulsions but with generalized muscle weakness. The patient was eventually transferred to the regular ward and was discharged after few days.**

*Bahrain Med Bull 2015; 37(4): 270 - 274*

SE is a life-threatening condition, which necessitate urgent management. SE is defined as either continuous convulsions without remission for more than five minutes or frequent seizures without returning to the base-line conscious level in between the seizures<sup>1-3</sup>.

In SE patients, 30-43% will show a refractory type of status epilepticus (RSE). RSE is associated with an increased hospital stay and a poor neurological outcome but without increased mortality. The incidence of RSE is associated with different risk factors such as encephalitis. In addition, it was noted that patient with non-convulsive status epilepticus (NCSE) tend to be more resistant to medications (refractory status epilepticus) than patients with convulsive SE<sup>4,5</sup>.

The mortality rate in patients with the first episode of SE could reach 20%, but the estimates vary widely according to the underlying etiology<sup>6-9</sup>. Mortality of SE rises to 81% due to anoxic brain insult<sup>6,10</sup>. Mortality is not only dependent on the underlying etiology, but on other medical comorbidities as well. Increasing age and a high APACHE II score are also independent risk factors<sup>9,11-14</sup>.

Female gender and a failure to respond to the first drug administrated were risk factors for recurrent SE. The recurrence could be 25 percent<sup>15</sup>.

RSE is defined as SE that fails to respond to antiepileptic medications and/or recurs quickly on tapering these medications; it could evolve to malignant SE in about 20% of patients, and it carries a very poor prognosis<sup>16</sup>.

The aim of this report is to highlight the possibility of full recovery after intractable status epilepticus and the use of high-dose combined drug therapy in the management of such cases.

### THE CASE

A thirty-two-year-old Indian male was unconscious and agitated after suffering a generalized tonic-clonic convulsion while driving. There was a history of fever and contact with a roommate who had a skin rash two days prior to admission, but there was no previous history of convulsions.

The patient had a Glasgow Coma Score (GCS) of 7; endotracheal intubation was inserted to secure the airway. The brain CT scan was normal and the CSF analysis was inconclusive. The patient started empirically on ceftriaxone, acyclovir and steroids to cover both bacterial and viral infections. After a few days, MRI and venogram (MRV) revealed a transverse sinus thrombosis. Therapeutic anticoagulation was commenced. Two weeks after admission, a cerebral angiogram was performed for the possibility of *in situ* thrombolysis. The angiogram showed spontaneous recanalization of the lesion.

The patient had generalized tonic-clonic convulsions and SE on EEG for six weeks. He was started initially on Phenytoin, followed by continuous infusions of Propofol and Midazolam. Clonazepam, Levetiracetam, Topiramate and Sodium Valproate at maximum doses for two weeks. In the second week of admission, a percutaneous tracheostomy (PCT) was performed and the patient was kept on controlled ventilation.

---

\* Senior Registrar  
Department of Anesthesia  
\*\* Consultant  
\*\*\* Registrar  
\*\*\*\* Consultant and Director of ICU  
Department of Intensive Care  
Associate Professor of Anesthesia and Critical Care, RCSI-MUB  
King Hamad University Hospital  
Kingdom of Bahrain  
Email: mohamed.hashim@khuh.org.bh; mohamed.elbahr@khuh.org.bh

Over the following few weeks, some different anticonvulsant and anesthetic drugs were used to control the seizures, see Figures 1- 4. Figures 1 to 4 demonstrate the agents used, the doses given and the duration of their usage. A follow-up brain MRI revealed biparietal acute ischemic insults and bilateral sphenoid and ethmoidal sinusitis.

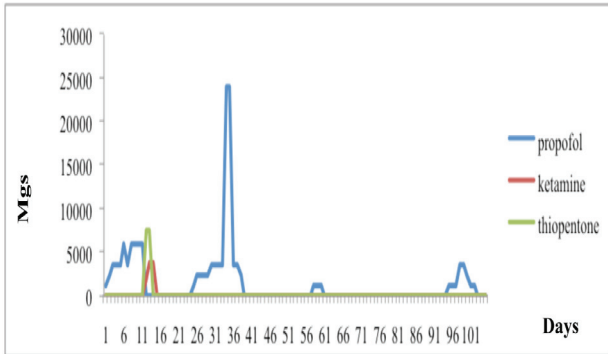


Figure 1: Dosage of Propofol, Ketamine and Thiopentone

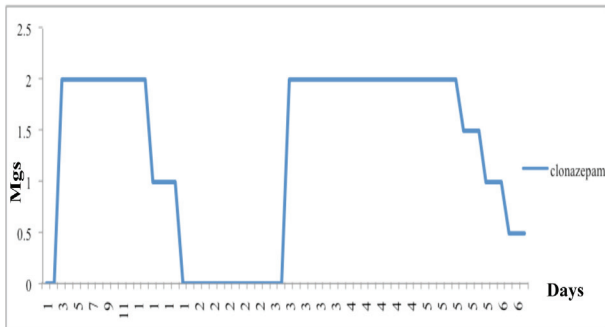


Figure 2: Dosage of Clonazepam

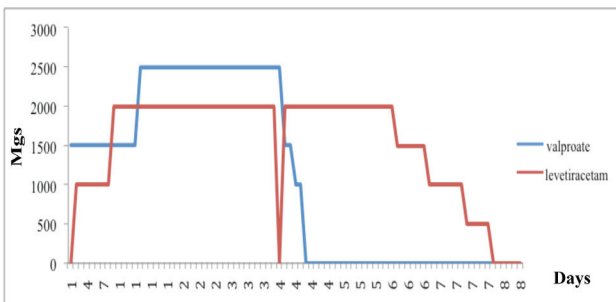


Figure 3: Dosage of Valproate and Levetiracetam

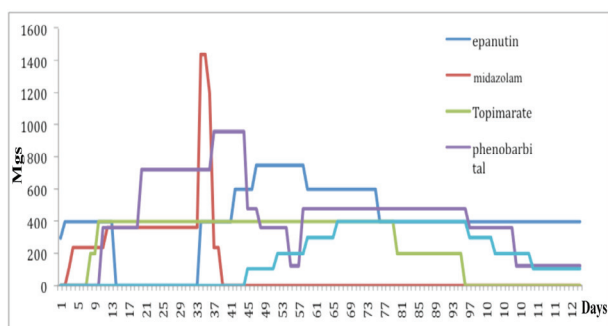


Figure 4: Dosage of Epanutin, Midazolam, Topiramate, Phenobarbital and Lacosamide

The patient continued to have seizures; therefore, high doses of Propofol (up to 1 gm/hr) and Midazolam (60 mg/hr) were initiated. Continuous EEG monitoring was applied aiming for burst suppression and EEG silence. Antiepileptic drug doses were maximized without obtaining full control of the convulsions.

The phenobarbital dose of 240 mg every 6 hours achieved control of the generalized convulsions except focal twitches.

Slow weaning of propofol and midazolam was achieved and the patient was kept on six anticonvulsants: Phenobarbital, Lacosamide, Topiramate, Levetiracetam, Clonazepam and Phenytoin, which achieved good control of the convulsions.

The patient started to regain consciousness, but with severe muscle weakness and disorientation; therefore, mechanical ventilation had to be continued. Slow weaning from the ventilation was initiated, but the patient developed sepsis (ventilator-acquired pneumonia-VAP) with uncontrolled convulsions; therefore, the Propofol infusion was restarted with a maintenance of the dose of Phenobarbital of 240 mg/8 hours.

After sepsis treatment, mechanical ventilation weaning was commenced with aggressive physiotherapy. The patient became awake with weak muscle power, but with good mental status and the ability to obey simple commands.

The patient's alertness slowly improved; he became better orientated, his muscle power improved and all his invasive lines (Foley's catheter, nasogastric tube, central venous catheter and arterial line) were removed.

The patient became fully conscious with no residual neurological deficit and with good control of convulsions using Phenobarbital, Phenytoin and Lacosamide.

Intensive physiotherapy led to the improvement of the muscle power; the patient was transferred to the high dependency unit (HDU) and eventually to the regular ward, where he stayed for twelve days before going home. He had no more generalized tonic-clonic seizures, but still had some facial twitches during speaking or straining. The patient was mobile, but due to lower limb weakness, he was able to walk only for few steps with support and assistance.

## DISCUSSION

Patients who continue to have either clinical or electroencephalographic fits after receiving adequate dosages of first and second line antiepileptic medications are considered intractable while persistent seizure activity after administration of high-dose intravenous anesthetics is considered to be malignant SE<sup>17,5</sup>.

Most episodes of SE develop without a prior history of epilepsy; they are almost always secondary to an underlying structural or metabolic-toxic problem, brain anoxia and encephalitis<sup>1,5,18</sup>. The essentials in managing SE are as follows: management of breathing and circulation to stop seizure activity and treat the underlying cause<sup>19</sup>. Intravenous Lorazepam is the drug of

choice to treat SE in the first instance<sup>20</sup>. Phenytoin remains the second-line agent<sup>4</sup>.

After failure of the first and second-line drug therapy, the third-line should be administered, but there is limited evidence to guide the systematic addition of the third-line anticonvulsants in SE<sup>21-23</sup>. Despite Pentobarbital infusion being associated with fewer breakthrough seizures and treatment failures, many studies suggest that continuous infusions of Propofol or Midazolam should be considered as agents of choice in RSE because of the better side-effect compared to Pentobarbital<sup>18,21,24</sup>. When coma-inducing agents are employed, coma should be maintained for at least 24-48 hours<sup>25</sup>.

Malignant SE that are refractory to Propofol; Midazolam and/or Pentobarbital, Ketamine infusion has occasionally been successfully used<sup>26,27</sup>.

Anticonvulsant agents including Lacosamide and Topiramate should not be considered in malignant SE. Inhalational anesthetics, particularly Isoflurane, should be reserved for salvage therapy when other agents in anesthetic doses are ineffective or have produced unacceptable side-effects<sup>28-32</sup>.

Other newer promising treatment regimens for malignant SE include surgery if a localized area is causing the seizure, electroconvulsive therapy, hypothermia and a ketogenic diet<sup>33-36</sup>.

In our patient, there were several factors that predicted a poor outcome: no previous history of seizures, an accompanying transverse venous sinus thrombosis, biparietal acute ischemic insults, potential hypoxic brain injury, low initial Glasgow Coma Score, sepsis and prolonged duration of the status epilepticus.

## CONCLUSION

**To our knowledge, this is the first published report describing an excellent cognitive recovery in a patient after six weeks of continuous seizure activity which remained uncontrolled even after the administration of intravenous anesthetic drugs (Propofol and Midazolam) and six oral antiepileptic medications. Therefore, excellent neurological recovery is possible after prolonged malignant status epilepticus, in young patients with malignant SE who have limited brain damage need a significant period of intensive pharmacological therapy to show signs of recovery and in malignant SE; it is important to target burst suppression relentlessly even if heroic doses of intravenous anesthetic drugs have to be administered.**

**Author Contribution:** All authors share equal effort contribution towards (1) substantial contribution to conception and design, acquisition, analysis and interpretation of data; (2) drafting the article and revising it critically for important intellectual content; and (3) final approval of the manuscript version to be published. Yes.

**Potential Conflicts of Interest:** None.

**Competing Interest:** None. **Sponsorship:** None.

**Submission Date:** 26 March 2015. **Acceptance Date:** 6 October 2015.

**Ethical Approval:** Approved by the Research and Ethics Committee, King Hamad University Hospital, Bahrain.

## REFERENCES

1. Aminoff MJ, Simon RP. Status Epilepticus. Causes, Clinical Features and Consequences in 98 Patients. *Am J Med* 1980; 69(5):657-66.
2. Lowenstein DH, Alldredge BK. Status Epilepticus. *N Engl J Med* 1998; 338(14):970-6.
3. Treatment of Convulsive Status Epilepticus. Recommendations of the Epilepsy Foundation of America's Working Group on Status Epilepticus. *JAMA* 1993; 270(7):854-9.
4. Mayer SA, Claassen J, Lokin J, et al. Refractory Status Epilepticus: Frequency, Risk Factors, and Impact on Outcome. *Arch Neurol* 2002; 59(2):205-10.
5. Holtkamp M, Othman J, Buchheim K, et al. Predictors and Prognosis of Refractory Status Epilepticus Treated in a Neurological Intensive Care Unit. *J Neurol Neurosurg Psychiatry* 2005; 76(4):534-9.
6. DeLorenzo RJ, Pellock JM, Towne AR, et al. Epidemiology of Status Epilepticus. *J Clin Neurophysiol* 1995; 12(4):316-25.
7. Logroscino G, Hesdorffer DC, Cascino G, et al. Short-Term Mortality after a First Episode of Status Epilepticus. *Epilepsia* 1997; 38(12):1344-9.
8. Chin RF, Neville BG, Scott RC. A Systematic Review of the Epidemiology of Status Epilepticus. *Eur J Neurol* 2004; 11(12):800-10.
9. Koubeissi M, Alshekhlee A. In-Hospital Mortality of Generalized Convulsive Status Epilepticus: A Large US Sample. *Neurology* 2007; 69(9):886-93.
10. Towne AR, Pellock JM, Ko D, et al. Determinants of Mortality in Status Epilepticus. *Epilepsia* 1994; 35(1):27-34.
11. Prasad A, Worrall BB, Bertram EH, et al. Propofol and Midazolam in the Treatment of Refractory Status Epilepticus. *Epilepsia* 2001; 42(3):380-6.
12. Rossetti AO, Hurwitz S, Logroscino G, et al. Prognosis of Status Epilepticus: Role of Aetiology, Age, and Consciousness Impairment at Presentation. *J Neurol Neurosurg Psychiatry* 2006; 77(5):611-5.
13. Canouï-Poitrine F, Bastuji-Garin S, Alonso E, et al. Risk and Prognostic Factors of Status Epilepticus in the Elderly: A Case-Control Study. *Epilepsia* 2011; 52(10):1849-56.
14. Alvarez V, Januel JM, Burnand B, et al. Role of Comorbidities in Outcome Prediction after Status Epilepticus. *Epilepsia* 2012; 53(5):e89-92.
15. Hesdorffer DC, Logroscino G, Cascino GD, et al. Recurrence of Afebrile Status Epilepticus in a Population-Based Study in Rochester, Minnesota. *Neurology* 2007; 69(1):73-8.
16. Holtkamp M, Othman J, Buchheim K, et al. A "Malignant" Variant of Status Epilepticus. *Arch Neurol* 2005; 62(9):1428-31.
17. Claassen J, Hirsch LJ, Emerson RG, et al. Treatment of Refractory Status Epilepticus with Pentobarbital, Propofol, or Midazolam: A Systematic Review. *Epilepsia* 2002; 43(2):146-53.
18. Drislane FW, Lopez MR, Blum AS, et al. Detection and Treatment of Refractory Status Epilepticus in the Intensive Care Unit. *J Clin Neurophysiol* 2008; 25(4):181-6.
19. Ruegg SJ, Dichter MA. Diagnosis and Treatment of Nonconvulsive Status Epilepticus in an Intensive Care Unit Setting. *Curr Treat Options Neurol* 2003; 5(2):93-110.
20. Lason W, Dudra-Jastrzębska M, Rejdak K, et al. Basic Mechanisms of Antiepileptic Drugs and Their Pharmacokinetic/Pharmacodynamic Interactions: An Update. *Pharmacol Rep* 2011; 63(2):271-92.

21. Alldredge BK, Gelb AM, Isaacs SM, et al. A Comparison of Lorazepam, Diazepam, and Placebo for the Treatment of Out-of-Hospital Status Epilepticus. *N Engl J Med* 2001; 345(9):631-7.
22. Bleck TP. Refractory Status Epilepticus. *Curr Opin Crit Care* 2005; 11(2):117-20.
23. Rossetti AO, Lowenstein DH. Management of Refractory Status Epilepticus in Adults: Still More Questions than Answers. *Lancet Neurol* 2011; 10(10):922-30.
24. Rossetti AO. Which Anesthetic should be used in the Treatment of Refractory Status Epilepticus? *Epilepsia* 2007; 48 Suppl 8:52-5.
25. Kossoff E. The Fat is in the Fire: Ketogenic Diet for Refractory Status Epilepticus. *Epilepsy Curr* 2011; 11(3):88-9.
26. Marik PE, Varon J. The Management of Status Epilepticus. *Chest* 2004; 126(2):582-91.
27. Hsieh CY, Sung PS, Tsai JJ, et al. Terminating Prolonged Refractory Status Epilepticus Using Ketamine. *Clin Neuropharmacol* 2010; 33(3):165-7.
28. Yeh PS, Shen HN, Chen TY. Oral Ketamine Controlled Refractory Nonconvulsive Status Epilepticus in an Elderly Patient. *Seizure* 2011; 20(9):723-6.
29. Albers JM, Möddel G, Dittrich R, et al. Intravenous Lacosamide--An Effective Add-On Treatment of Refractory Status Epilepticus. *Seizure* 2011; 20(5):428-30.
30. Kellinghaus C, Berning S, Immisch I, et al. Intravenous Lacosamide for Treatment of Status Epilepticus. *Acta Neurol Scand* 2011; 123(2):137-41.
31. Synowiec AS, Yandora KA, Yenugadhathi V, et al. The Efficacy of Topiramate in Adult Refractory Status Epilepticus: Experience of a Tertiary Care Center. *Epilepsy Res* 2012; 98(2-3):232-7.
32. Hottinger A, Sutter R, Marsch S, et al. Topiramate as an Adjunctive Treatment in Patients with Refractory Status Epilepticus: An Observational Cohort Study. *CNS Drugs* 2012; 26(9):761-72.
33. Kofke WA, Young RS, Davis P, et al. Isoflurane for Refractory Status Epilepticus: A Clinical Series. *Anesthesiology* 1989; 71(5):653-9.
34. Fernandez A, Claassen J. Refractory Status Epilepticus. *Curr Opin Crit Care* 2012; 18(2):127-31.
35. Kamel H, Cornes SB, Hegde M, et al. Electroconvulsive Therapy for Refractory Status Epilepticus: A Case Series. *Neurocrit Care* 2010; 12(2):204-10.
36. Corry JJ, Dhar R, Murphy T, et al. Hypothermia for Refractory Status Epilepticus. *Neurocrit Care* 2008; 9(2):189-97.