

Cervical-Spine Injury and Quadriplegia Resulting from “Break Dance”

Badrya Toorani, BS, MBBS, CABS, FCPS* Shaker Al Asheeri, BSc**
Hussain Al Aradi, MD*** Osama Al Marzooq, MB, BCH****

We present a case of a rare cause of cervical spine injury and quadriplegia, an injury secondary to break dancing.

A nineteen-year-old male presented with quadriplegia; he sustained an injury while performing “break dancing”. To our knowledge, it is the first case of cervical spine injury reported after break dance in GCC states.

Cervical injuries and quadriplegia secondary to break dancing have rarely been described. Compared to other forms of recreational dance, break dancing may cause serious, life-threatening injuries.

Bahrain Med Bull 2017; 39(2): 120 - 122

Break dancing has been a popular recreational activity for adolescents and young adults since the 1980's. The emergence of the Internet in the 1990's gave break dancers a new method for gaining a wider audience, popularizing the dance around the world for long enough that it is now a subculture rather than just a recreational activity^{1,2}. Breakdance movements require explosive power, sustained effort and local and general endurance¹. Because these movements involve extremely strenuous physical activities, such as splits, spins, handstands and tumbling, it could be inferred that there is a high possibility of damage through acute or chronic musculoskeletal injuries. Such injuries include sprains, strains, tendinitis, bursitis, growth plate injuries, fractures of the clavicle, radius, ulna, carpal bone, phalanx and fifth metatarsal bone, stress fractures of the femur and calcaneus, vertebral fractures and spinal cord injuries².

Although no epidemiologic studies of musculoskeletal injuries in break-dancers have been reported, few case reports have been presented. Therefore, it could be calculated that injuries due to break dancing are now more prevalent and more critical than once thought to be².

Cervical spine injuries in dancers are usually misdiagnosed because they appear as stable injuries; yet, the consensus amongst physicians is to emphasize these injuries as unstable and intervention includes surgery.

The aim of this report is to present a patient with a rare cervical spine injury and quadriplegia resulting from break dance.

THE CASE

A previously healthy 19-year-old Bahraini male presented with quadriplegia on 23 May 2009. He sustained this injury while break dancing. The patient described performing a back flip when his hands failed to hold him upside down and resulted in a flexion injury to the neck with axial loading at C1–C2.

Examination of both upper and lower limbs revealed zero muscle power (complete quadriplegia), no intact sensation below the C1 region, no anal tone and no deep tendon reflexes. CT of the spine revealed no evidence of anterior atlantoaxial subluxation with a distance between the dense and the anterior arch of C1. There was no definite displaced fracture of C2 demonstrated, see figure 1.

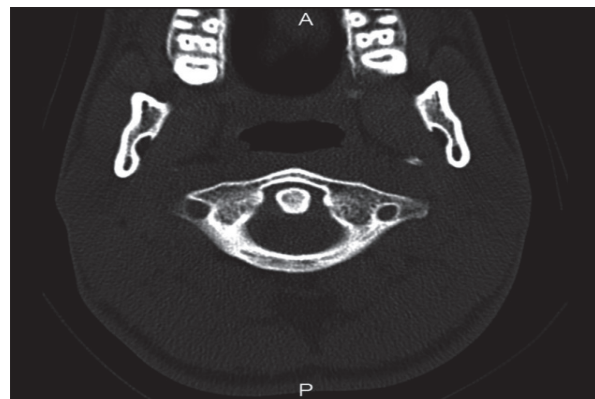


Figure 1: CT Scan of Cervical Spine Revealing Normal C1–C2 Articulation, No Instability and No Evidence of Subluxation

* Consultant Orthopedic, Trauma and Spine Surgeon
Chairperson
** Senior Orthopedic Surgeon
*** Resident
**** Resident
Department of Orthopedics
Salmaniya Medical Complex
The Kingdom of Bahrain
E-mail: badriyatoorani@hotmail.com

MRI revealed a hematoma in the cord from the base of the skull to the posterior body of C2 and mild central posterior disk prolapse at C2/C4, see figures 2 and 3.

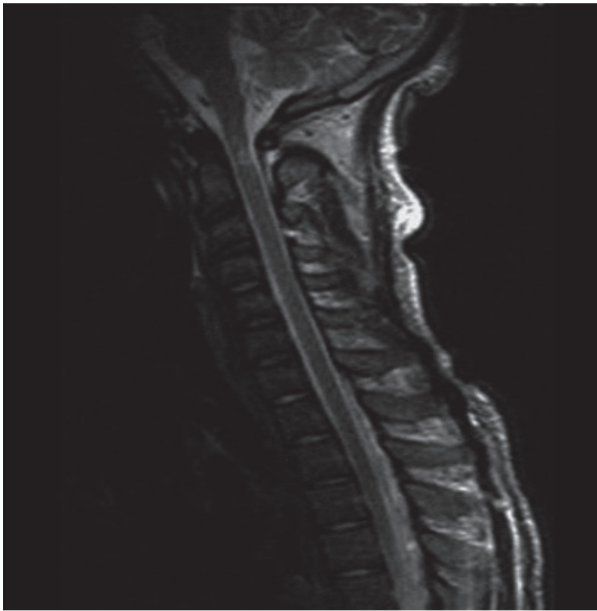


Figure 2: MRI T2 Spine Revealing Normal C1-C2 Articulation, No Evidence of Subluxation, a Posterior Hematoma at C2 Level and Hematoma in the Cord

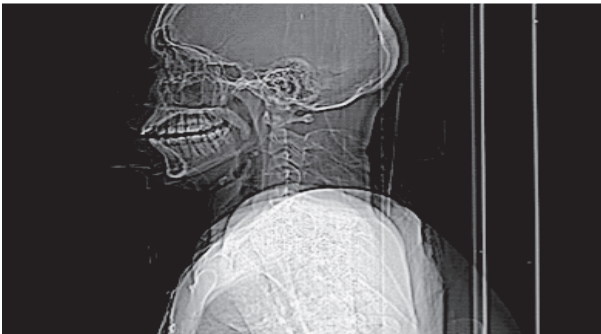

Figure 3: Lateral Cervical Spine X-ray Revealing No Evidence of C1-C2 Subluxation

The patient had a rupture of the anterior and posterior ligament at C1–C2. He was given methylprednisolone in the first 24 hours and intubated. The patient was put on skull traction and hard cervical collar in the ICU.

Repeat MRI four days following the injury showed an increase in the central hematoma, extending from the medulla oblongata to C4, see figure 4.

The patient underwent a traction test under general anesthesia. The test revealed that the spine was stable; therefore, he was treated conservatively. Subsequently, the patient showed neurological improvement.

Post-treatment, the patient developed spastic movements. A repeat MRI was performed, where subluxation of C1 on C2 and narrowing of the spinal canal was found; the diameter the canal was about 11 mm and the distance between C1 and odontoid process was 6 mm, see figures 5 and 6.

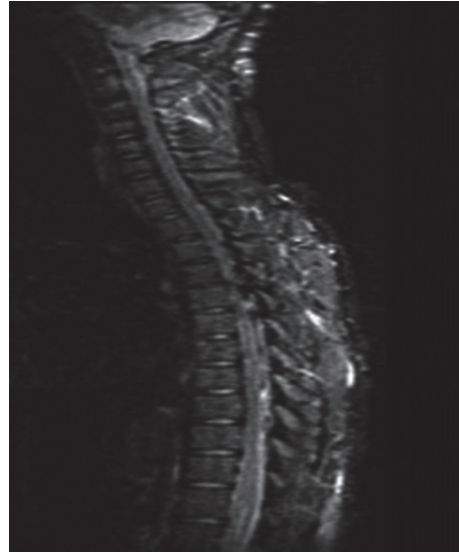

Figure 4: MRI T2 Revealing Hematoma Extending to the Level of C4

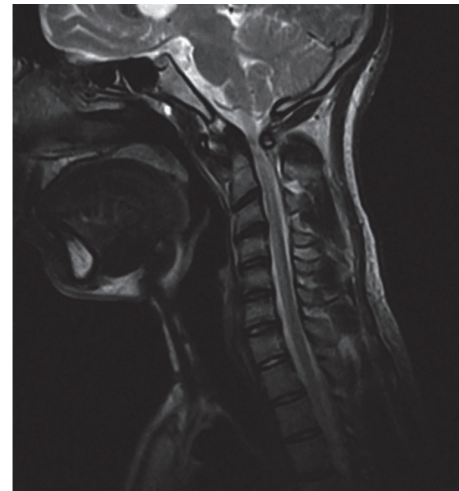


Figure 5: MRI T2 Revealed Evidence of C1-C2 Subluxation and Narrowing of the Spinal Cord Canal

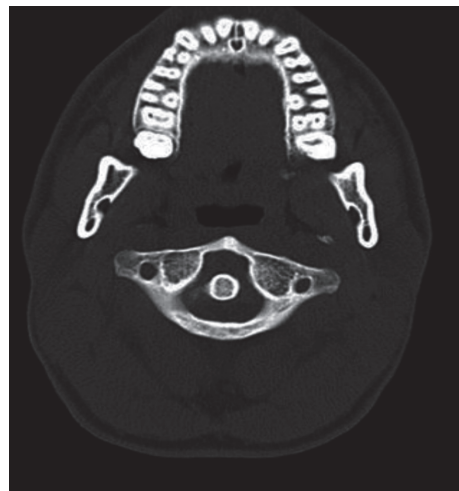

Figure 6: CT Scan Cervical Spine Revealing Evidence of C1-C2 Subluxation with Increased Anterior Dens Interval

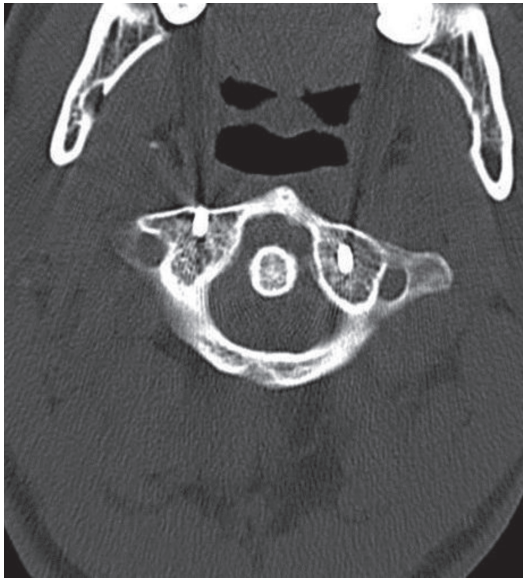

Figure 7: CT Scan Cervical Spine Revealing Transarticular Screws Insertion in C1-C2 Joint

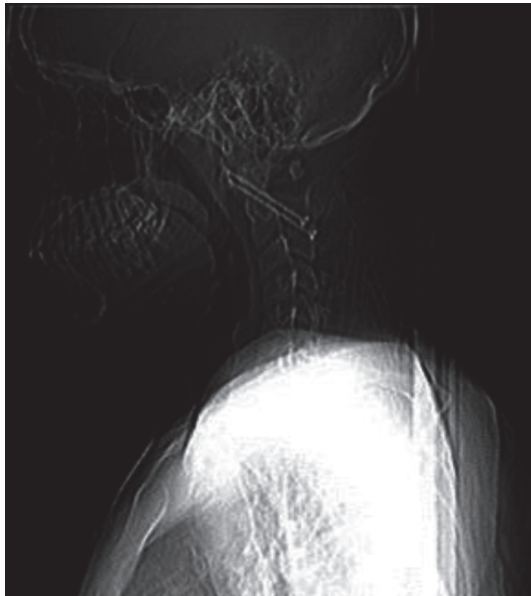


Figure 8: Postoperative Lateral X-ray after Transarticular Screw Insertion

The patient was treated surgically by posterior cervical C1–C2 transarticular screw with closed reduction and fusion, see figures 7 and 8. He then underwent an extensive physiotherapy program.

The patient improved neurologically; he was able to slowly stand up, lie down, walk around and open the door on his own. However, he still could not voluntarily control urination and defecation.

DISCUSSION

Break-dancers' injuries mostly localized to non-spine fractures, such as wrists (69%), fingers (62%), knees (62%), shoulders (52%), elbows (43%), ankles (38%), foot (29%) and hip (17%); the number of injuries per dancer are multiple rather than

singular². Fifty percent of the subjects suffered lumbar spine non-fracture injuries, while only 38% suffered cervical spine non-fracture injuries. Our patient is one of those rare cases. It is also noteworthy to mention that the study was unable to determine specific preventative injury measures; however, it recommended the use of protective devices, proper warm-up and cool-down exercises, instruction and supervised training, as well as education.

In another rare case of an 11-year-old boy who sustained the same injury as our patient, the boy acquired no neurological deficits and recovered fairly quickly; he suffered a combined odontoid dens fracture with an anterior C1/C2 luxation while engaging in a head-spin stunt³. Surgical repositioning was performed. The patient's head was fixed into a Mayfield clamp in the supine position. A translaminar fixation of C1/C2 had been performed, where two 16 mm screws were placed into the C2 arch and two 14 mm screws were placed into the C1 arch³. Follow-up examinations showed positive results with no neurological deficits³.

CONCLUSION

Cervical injuries and quadriplegia secondary to break dancing have rarely been described. The prognosis of patients who sustain cervical injuries due to break dancing ranges from moderate to severe and may cause serious chronic or acute life-threatening or debilitating injuries.

Injuries may appear as stable on imaging studies; consequently, this deception steers the management plan away from surgical and towards a conservative treatment route.

Author Contribution: All authors share equal effort contribution towards (1) substantial contribution to conception and design, acquisition, analysis and interpretation of data; (2) drafting the article and revising it critically for important intellectual content; and (3) final approval of manuscript version to be published. Yes.

Potential Conflicts of Interest: None.

Competing Interest: None.

Sponsorship: None.

Acceptance Date: 5 April 2017.

Ethical Approval: Approved by the Secondary Health Care Research Sub-Committee, Ministry of Health, Bahrain.

REFERENCES

1. Dance Medicine. In: Maffulli N, Chan, KM, Malina R, eds. Sports Medicine for Specific Ages and Abilities. 1st ed. USA: Churchill Livingstone Harcourt Publishers Limited, 2001:161-8.
2. Cho CH, Song KS, Min BW, et al. Musculoskeletal Injuries in Break-Dancers. *Injury* 2009; 40(11):1207-11.
3. Petridis AK, Kinzel A, Blaeser K, et al. Can Break Dance Break Your Neck? C1/C2 Luxation with a Combined Dens Fracture without Neurological Deficit in an 11-Year Old Boy after a Break Dance Performance. *Clin Pract* 2015; 5(3):781.