

Medical Quiz

Saeed Alhindi, MD, CABS, FRCSI*

A nine-year-old male patient presented with upper abdominal pain of three months duration. The pain is associated with nausea and vomiting. The patient had the following radiological tests; look at the figures below and answer the following questions:

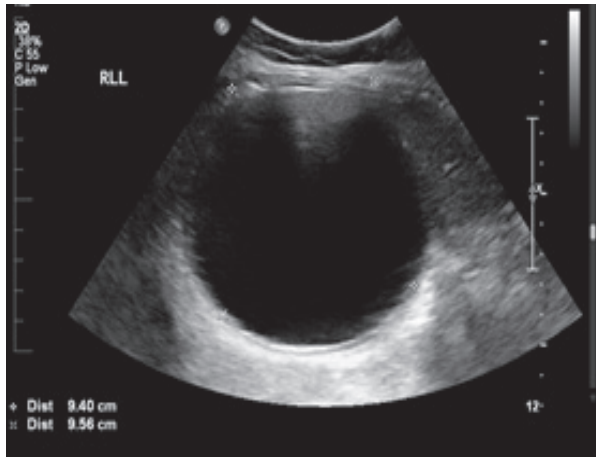


Figure 1

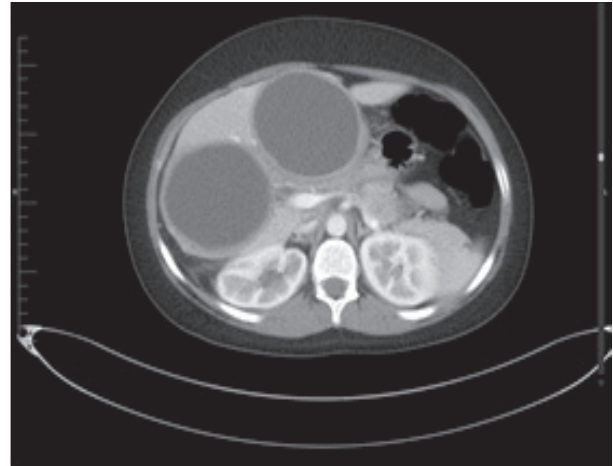


Figure 2

- Q1. Identify the radiological tests and describe the findings in figures 1 and 2.
- Q2. Mention three organs which could be affected by this disease.
- Q3. What is the diagnosis?

Answers on page 86

* Assistant Professor, Arabian Gulf University
Consultant Pediatric Surgeon, Salmaniya Medical Complex
P.O. Box 12
Kingdom of Bahrain
E-mail: sjalhindi@yahoo.com, sjalhindi@gmail.com