

## A Retrospective Histopathological Analysis of Appendiceal Tumors for 10 Years

Muneera Al-Khalifa\* Muzoon Al-Muawda\*  
Budoor Almusaifer, MB BCh BAO\*\* Abdulla Darwish, FRCPath\*\*\*

**Objective:** To evaluate the incidence of appendiceal tumors in different sex and age groups.

**Design:** A Retrospective Study.

**Setting:** Pathology Department, Bahrain Defence Force Hospital, Bahrain.

**Method:** A retrospective review of 2,310 appendectomy specimens submitted to the Pathology Department between 1 January 2006 and 31 December 2015.

**Result:** During the study period, 2,310 appendectomy specimens were reviewed; 19 (0.8%) of the samples were histologically diagnosed as appendiceal tumors. Of the 19 appendiceal tumors, 9 (47%) were carcinoid, 6 (32%) were benign, including mucinous cystadenoma and neuroma and 4 (21%) were malignant. The mean age of carcinoid tumors is 35 years, ranging from 14 to 51 years. The mean age of malignant appendiceal tumors is 46 years, ranging from 30 to 60 years. Appendiceal tumors were found to be more common in males than in females. The male to female ratio is 2:1 for both carcinoid and benign tumors and 3:1 for malignant tumors.

**Conclusion:** Appendiceal tumors are rare. The most common tumors are carcinoid tumors. In some cases, an appendectomy alone is a sufficient treatment for a tumor. However, in cases of malignancy, a right hemicolectomy is required.

*Bahrain Med Bull 2018; 40(1): 18 - 21*

The appendix is one of the human organs that attracts little attention, hence termed an ineffectual blind tube. Nonetheless, this intestinal organ at the junction between the cecum and terminal ileum, undergoes pathological changes that have a significant influence on human health<sup>1</sup>. This organ is also susceptible to conditions such as appendicitis and carcinoid tumors<sup>2</sup>. The World Health Organization (WHO) classifies appendiceal tumors into epithelial, non-epithelial or secondary. Epithelial tumors include adenoma, carcinoma and carcinoid. On the other hand, non-epithelial tumors of mesenchymal origin include neuroma, lipoma, leiomyoma, gastrointestinal stromal tumor (GIST) and their malignant forms<sup>3</sup>. Malignant lymphoma and Kaposi's sarcoma are also possible appendiceal growths<sup>1,3,4,5</sup>.

Acute abdominal pain is one of the most common earliest indicators of any clinical issues. The earliest known case of an appendiceal tumor dates back to 1882<sup>2</sup>. Appendiceal tumors constitute 0.2% to 0.5% of all primary neoplasms seen in the gastrointestinal tract<sup>4,6-9</sup>. This type of tumor is rare compared to other tumors that affect the gastrointestinal tract<sup>2,6,10-12</sup>.

Appendiceal tumors could arise from any cell along its walls<sup>2</sup>. Unfortunately, there is no solid understanding of their pathogenesis<sup>13,14</sup>. In addition, patients with appendiceal tumors are mostly asymptomatic; in rare instances, acute appendicitis can be an early indicator of an abdominal mass. Typically, the anomaly is detected during an abdominal surgery such as appendectomy, often as a result of acute appendicitis. The growths could be detected by CT scans where they appear as abdominal masses<sup>6, 13, 15-17</sup>.

The aim of this study is to determine the incidence rate of appendiceal tumors.

### METHOD

All histopathological specimens of appendectomies from 1 January 2006 and 31 December 2015 were reviewed. Only cases which had complete clinical data and histological records were included in the study.

Two thousand three hundred ten pediatric and adult appendectomies were performed during the 10-year period.

---

\* Medical Student  
Royal College of Surgeons in Ireland - Medical University of Bahrain  
\*\* Resident  
\*\*\* Consultant Histopathologist  
Department of Pathology  
Bahrain Defence Force Hospital - Royal Medical Services  
The Kingdom of Bahrain  
E-mail: abdulla.darwish@bdfmedical.org

The sample included negative appendectomies where the histological examination established that the appendix was normal. The following data were documented: age, gender, diagnosis, tumor size, location and metastasis.

The WHO classification of appendiceal tumors was used to classify the tumors into carcinoid, benign and malignant. Two cases of mucocele of the appendix and eight cases due to incomplete clinical data were excluded from the study.

The data was analyzed using SPSS 19.0 statistical package. The Chi-Square test was used to compare categorical data whereby a P-value of <0.05 was considered significant. The continuous data generated was expressed in the form of mean and standard deviation while descriptive analysis of frequencies and percentages featured as part of the statistical analysis.

**RESULT**

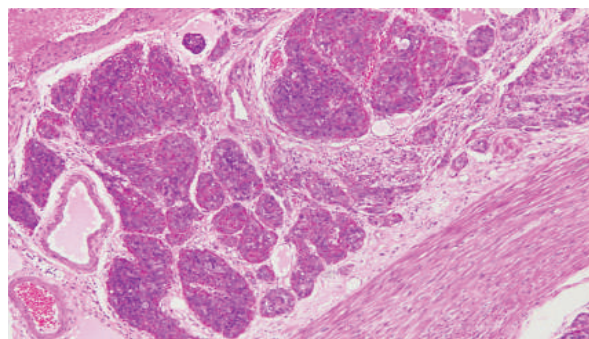
Two thousand three hundred ten appendix specimens were documented; 1,456 (63%) were male and 854 (37%) were female with a male to female ratio of 1.7:1.

One hundred eighty-four (8%) appendices were normal, 1,857 (80.4%) were inflamed appendices and 19 (0.82%) were appendiceal tumors, 250 (10.8%) were lymphoid hyperplasia, fibrosis and fecolith. Nine (0.38%) of the appendiceal tumors were carcinoid tumors, 6 (0.25%) were benign tumors, and 4 (0.17%) were malignant tumors, see table 1.

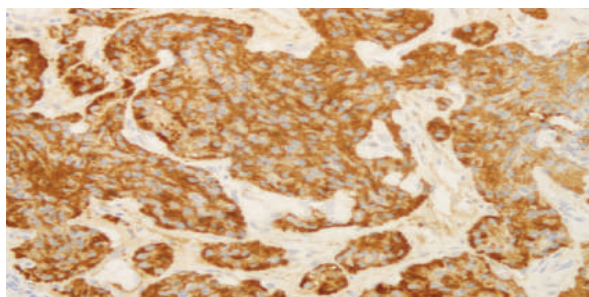
**Table 1: Incidence of Appendiceal Tumors**

Type of Tumor	Males	Females	Total (%)
<b>Carcinoid Tumor</b>			
Carcinoid	6	2	9
Goblet Cell Carcinoid	0	1	
<b>Benign Tumors</b>			
Mucinous Cystadenoma	2	2	6
Appendiceal Neuroma	2	0	
<b>Malignant Tumors</b>			
Mucinous Adenocarcinoma	2	1	4
Mucinous Cystadenocarcinoma	1	0	
<b>Total</b>	<b>13</b>	<b>6</b>	<b>19</b>

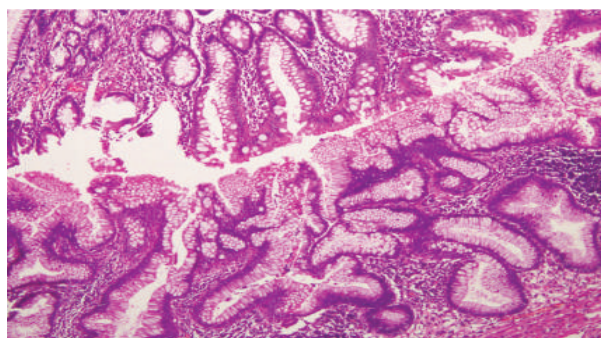
Six (0.25%) carcinoid tumors were associated with appendicitis, and one (0.04%) patient had a goblet cell carcinoid tumor which metastasized, see figure 1 (A and B). Additionally, nine (0.38%) of the tumors were located at the tip of the appendix, while six (0.25%) had invaded the submucosa. Four (0.17%) benign tumors were mucinous cystadenomas, and two (0.08%) were appendiceal neuromas, see table 1 and figure 2. Both cases of appendiceal neuroma were found to be associated with fibrous obliteration. There were no patients with carcinoid syndrome or signet ring carcinoma. Figures 3(A) and 3(B) show two cases of adenocarcinoma.



**Figure 1 (A): Microscopic View of Carcinoid Tumor with Classical Arrangement of the Tumor Cells (H & E stained x10)**



**Figure 1 (B): Tumor Cells Stained Strongly for Chromogranin, a Special Immunohistochemistry Marker for Neuroendocrine Cells (Chromogranin Stain x20)**



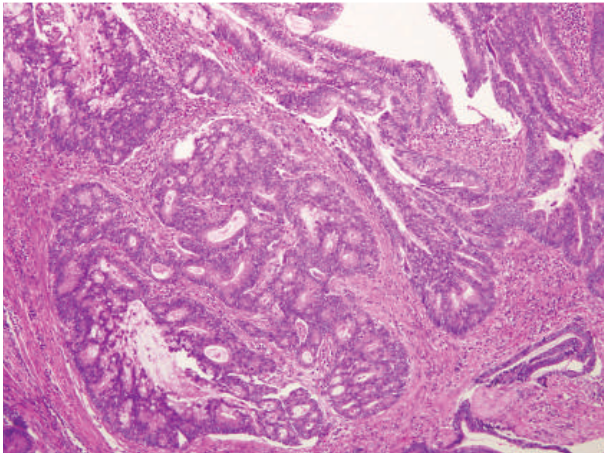
**Figure 2: Low-Power Microscopic View of the Mucinous Cystadenoma in the Lower Portion of the Image Compared to the Normal Appendiceal Mucosa in the Upper Portion (H & E x10)**

Of the 19 appendiceal tumors, 13 were males and six were females; however, there was no significant relationship between gender and tumor types (P-value=0.7). Carcinoid tumors were diagnosed in patients between the ages of 14 and 51 with a mean age of 35.2 years. Early diagnosis of carcinoid tumor was more common among women than among men with mean ages of 28.3 and 38.7 years respectively, see table 2.

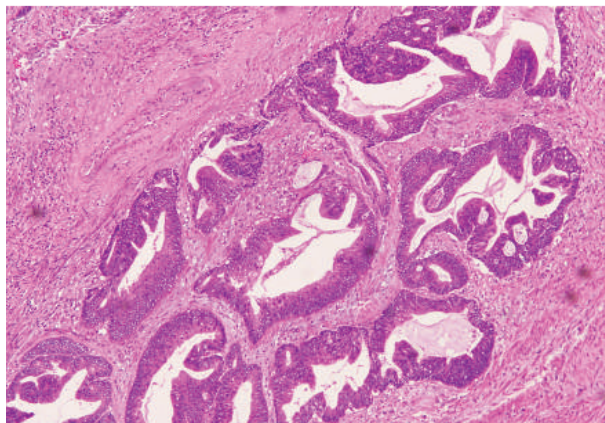
**Table 2: Age of Presentation of Appendiceal Tumors (19)**

Age Group (years)	Carcinoid		Benign		Malignant		Total (%)
	Males	Females	Males	Females	Males	Females	
10-29	0	2 (10.5%)	1 (5.3%)	0	0	0	3 (15.8%)
30-49	6 (31.6%)	0	3 (15.7%)	1 (5.3%)	1 (5.3%)	1 (5.3%)	12 (63.2%)
≥50	0	1 (5.3%)	0	1 (5.2%)	2 (10.5%)	0	4 (21%)
<b>Total</b>	<b>6 (31.6%)</b>	<b>3 (15.8%)</b>	<b>4 (21%)</b>	<b>2 (10.5%)</b>	<b>3 (15.8%)</b>	<b>1 (5.3%)</b>	<b>19 (100%)</b>

The mean age of the presentation of benign tumors was 38.8 years for both sexes; nonetheless, the average age for males is 33.5 years and 49.5 years for females.



**Figure 3 (A): Microscopic View of Adenocarcinoma of the Appendix: Low Power View of a Moderately Differentiated Adenocarcinoma Infiltrating the Wall (H & E x10)**



**Figure 3 (B): Microscopic View of Adenocarcinoma of the Appendix: Mucinous Adenocarcinoma Shows Dilated Malignant Glands Filled with Mucin (H & E x10)**

## DISCUSSION

In our study, the prevalence of appendiceal tumors was 0.82% compared to 0.7% in South Korea and Israel<sup>7,18</sup>. In our study, the average age of presentation for malignant tumors was 46 years, which is lower than several studies where the mean age was 57-61 years<sup>2,5,19</sup>.

This study demonstrated that carcinoid tumors are the most common type of appendiceal tumors, which is similar to other studies<sup>1,6,12,20</sup>. These tumors are “well-differentiated neuroendocrine tumors” and are either asymptomatic or present as acute appendicitis<sup>4,20-24</sup>. Carcinoid tumors are slow-growing and appendectomy often proves to be an effective treatment approach<sup>20,21,23</sup>. In this study, the largest carcinoid tumor was an 8 mm goblet cell carcinoid.

Females are more commonly affected with carcinoid tumors<sup>3,15,20,25</sup>. However, Moertel et al claim that the incidence

rate of carcinoid tumors is equal in both sexes<sup>25</sup>. In this study, males were twice more likely to be diagnosed with carcinoid tumors.

Carcinoid tumors in the appendix have a 2% to 4.7% chance of developing into malignancy and lower incidence of metastasis compared to other types of carcinoid growths that occur in the lungs, intestines, ovaries or kidneys<sup>20-23</sup>. In our study, one of the nine carcinoid tumors (goblet cell) metastasized; it was an aggressive adenocarcinoid tumor with carcinoid features, similar to other studies<sup>5,26</sup>. Other studies revealed that the mean age of presentation of goblet cell carcinoid ranges between 52 and 59 years<sup>5,16</sup>. In our study, this type of tumor was diagnosed in a 51-year old female.

A study by Roggo et al found that 78% of carcinoid tumors were located at the tip of the appendix; Another study by Lee et al found it to be 66.7%<sup>20,7</sup>. On the other hand, goblet cell carcinoids mostly occur in the middle-third of the appendix<sup>12</sup>. In our study, the average size of carcinoid tumors was 3.79 mm. A South Korean study reported an average size of 8.6 mm<sup>7</sup>. An appendectomy is an appropriate treatment approach for carcinoid tumors less than 1 cm to 2 cm in size<sup>11,13,20,21</sup>.

Benign tumors are usually asymptomatic and account for about 0.2%. These abnormal masses are mostly found incidentally, similar to other appendiceal tumors<sup>11</sup>. The most common type of benign tumor is mucinous cystadenoma. We found that mucinous cystadenomas occur in 0.2% of appendices compared to 0.4% to 0.6% in other studies<sup>7,27</sup>. The treatment is total excision to avoid any malignant transformation and prevent pseudomyxoma peritonei. Based on the reviewed literature, the prevalence of mucocele is 0.29% to 0.4%<sup>28</sup>. A neuroma is another common benign tumor which is known to cause fibrous obliteration. This was evident in both cases in this study<sup>3</sup>.

Adenocarcinoma is the most common primary malignancy of the appendix<sup>5</sup>. According to Langlie-Lesnik, males are 2-3 times more likely to be diagnosed with this primary malignancy compared to females<sup>29</sup>. Although this is a relatively rare type of malignant tumor of the appendix, it accounts for 4% to 6% of all appendiceal tumors<sup>2,6,19,30</sup>.

Adenocarcinoma tends to perforate<sup>19</sup>. One case of mucinous cystadenocarcinoma in our study had perforated. The mean age of presentation of adenocarcinoma in our study was 46 years.

Based on the findings of this study, more men than women were diagnosed with carcinoid tumors. A possible justification could be that there were almost twice as many men as women who underwent appendectomies during the studied period. One-third of the women reviewed were diagnosed with benign tumors, while malignant tumors of the appendix appeared more commonly among males. An appendectomy is the common form of treatment for an appendiceal tumor that measures less than 1 cm to 2 cm, where there are no signs of lymphovascular invasion<sup>4,11,17,19-21</sup>.

## CONCLUSION

**Appendiceal tumors are rare; nonetheless, carcinoid tumors are the most common tumor in the appendix. Additionally,**

**mucinous cystadenoma is the most common benign tumor. Appendiceal tumors are slow-growing and are often detected before they grow large enough to metastasize. The most popular treatment approach is appendectomy. The data is not entirely reliable and cannot be used to present a solid conclusion regarding the relationship between appendiceal tumors, patients' age and gender. Nevertheless, the data in this study can be used for comparison purposes in future studies.**

**Author Contribution:** All authors share equal effort contribution towards (1) substantial contributions to conception and design, acquisition, analysis and interpretation of data; (2) drafting the article and revising it critically for important intellectual content; and (3) final approval of the manuscript version to be published. Yes.

**Potential Conflicts of Interest:** None.

**Competing Interest:** None.

**Sponsorship:** None.

**Acceptance Date:** 27 January 2018.

**Ethical Approval:** Approved by the Research and Ethics Committee, Bahrain Defence Force Hospital, Bahrain.

## REFERENCES

- American Society of Clinical Oncology. Appendix Cancer-Overview. <http://www.cancer.net/cancer-types/appendix-cancer/overview>. Accessed on 16 May 2016.
- O'Donnell ME, Badger SA, Beattie GC, et al. Malignant Neoplasms of the Appendix. *Int J Colorectal Dis* 2007; 22(10):1239-48.
- Hamilton SR, Altonen LA. Pathology and Genetics: Tumours of the Digestive System. 3rd ed. France: IARC Press, 2000. <http://www.iarc.fr/en/publications/pdfs-online/pat-gen/bb2/bb2-chap5.pdf>. Accessed on 18 June 2016.
- Ozcelik CK, Turanli S, Bozdogan N, et al. Clinical Experience in Appendiceal Neuroendocrine Neoplasms. *Contemp Oncol (Pozn)* 2015; 19(5):410-3.
- McCusker ME, Coté TR, Clegg LX, et al. Primary Malignant Neoplasms of the Appendix: A Population-Based Study from the Surveillance, Epidemiology and End-Results Program, 1973-1998. *Cancer* 2002; 94(12):3307-12.
- Guraya SY. Do We Still Need to Perform Routine Histological Examination of Appendectomy Specimens? *J Clin Diagn Res* 2015; 9(6): PL01.
- Lee WS, Choi ST, Lee JN, et al. A Retrospective Clinicopathological Analysis of Appendiceal Tumors from 3,744 Appendectomies: A Single-Institution Study. *Int J Colorectal Dis* 2011; 26(5):617-21.
- Sugarbaker PH, Stephens AD. Atlas of Appendix Cancer and Pseudomyxoma Peritonei. <http://www.feliceapicella.it/www.surgicaloncology.com/attitle.htm>. Accessed on 18 June 2016.
- American Society of Clinical Oncology. Appendix Cancer-Statistics. <http://www.cancer.net/cancer-types/appendix-cancer/statistics>. Accessed on 18 June 2016.
- Connor SJ, Hanna GB, Frizzelle FA, et al. Appendiceal Tumors: Retrospective Clinicopathologic Analysis of Appendiceal Tumors from 7,970 Appendectomies. *Dis Colon Rectum* 1998; 41(1):75-80.
- Deans GT, Spence RA. Neoplastic Lesions of the Appendix. *Br J Surg* 1995; 82(3):299-306.
- Deschamps L, Couvelard A. Endocrine Tumors of the Appendix: A Pathologic Review. *Arch Pathol Lab Med* 2010; 134(6):871-5.
- Shooting for a Cure. What is Appendiceal Cancer? MD Anderson Cancer Center. <http://www.shootoutcancer.org/appendiceal-cancer/>. Accessed 18 June 2016.
- American Society of Clinical Oncology. Appendix Cancer-Risk Factors. Cancer.net <http://www.cancer.net/cancer-types/appendix-cancer/risk-factors>. Accessed on 16 May 2016.
- MD Anderson Cancer Center. Appendix Cancer. <http://www.mdanderson.org/cancer-types/appendix-cancer/appendix-cancer-facts.html>. Accessed on June 18 2016.
- Liu E, Telem DA, Warner RR, et al. The Role of Ki-67 in Predicting Biological Behavior of Goblet Cell Carcinoid Tumor in Appendix. *Am J Surg* 2011; 202(4):400-3.
- Landolsi S, Mannai S. Incidental Neuroendocrine Tumor of the Appendiceal Base Less than 20 mm in Diameter: Is Appendectomy Enough? *Pan Afr Med J* 2015; 22: 102.
- Hananel N, Powsner E, Wolloch Y. Adenocarcinoma of the Appendix: An Unusual Disease. *Eur J Surg* 1998; 164(11):859-62.
- Cerame MA. A 25-year Review of Adenocarcinoma of the Appendix. A Frequently Perforating Carcinoma. *Dis Colon Rectum* 1988; 31(2):145-50.
- Roggo A, Wood WC, Ottinger LW. Carcinoid Tumors of the Appendix. *Ann Surg* 1993; 217(4):385-90.
- Gu Y, Wang N, Xu H. Carcinoid Tumor of the Appendix: A Case Report. *Oncol Lett* 2015; 9(5):2401-2403.
- Strosberg JR. Clinical Characteristics of Carcinoid Tumours. UpToDate 2016. <http://www.uptodate.com/contents/clinical-characteristics-of-carcinoid-tumours>. Accessed on 17 June 2016.
- American Society of Clinical Oncology. Carcinoid Tumor: Overview. Cancer.net 2015 <http://www.cancer.net/cancer-types/carcinoid-tumor/overview>. Accessed on 18 June 2016.
- American Society of Clinical Oncology. Appendix Cancer-Symptoms and Signs. Cancer.net 2015. <http://www.cancer.net/cancer-types/appendix-cancer/symptoms-and-signs>. Accessed 16 May 2016.
- Moertel CG, Dockerty MB, Judd ES. Carcinoid Tumors of the Vermiform Appendix. *Cancer* 1968; 21(2):270-8.
- Warkel RL, Cooper PH, Helwig EB. Adenocarcinoid, A Mucin-Producing Carcinoid Tumor of the Appendix: A Study of 39 Cases. *Cancer* 1978; 42(6):2781-93.
- Velusamy A, Saw S, Gossage J, et al. Combined Adenocarcinoid and Mucinous Cystadenoma of the Appendix: A Case Report. *J Med Case Rep* 2009; 3:28.
- Karakaya K, Barut F, Emre AU, et al. Appendiceal Mucocele: Case Reports and Review of Current Literature. *World J Gastroenterol* 2008; 14(14):2280-3.
- Langlie-Lesnik C. Adenocarcinoma of the Appendix. Adenocarcinoma 2010. <http://www.appendix-cancer.com/oldsite/adenocarcinoma.htm>. Accessed on 18 June 2016.
- Gehrig PA, Boggess JF, Ollila DW, et al. Appendix Cancer Mimicking Ovarian Cancer. *Int J Gynecol Cancer* 2002; 12(6):768-72.