

Lemierre Syndrome: An Unusual Complication of Tongue Cancer

Anis Chaari, MD, EDIC* El Sayed Khalil Mahmoud, MBCh, MSc** Mariam El Khaja***
Hussein Hassanein, Msc, MD**** Ranjit Divakaran, FDS RCS, MDS*****

An eighty-year-old female was admitted to the intensive care unit for hemorrhagic shock due to bleeding tongue malignancy. Clinical assessment revealed infected neoplastic lesion. Blood cultures on admission revealed Streptococcus spp. The diagnosis of Lemierre syndrome was suspected. Therefore, an ultrasound Doppler was performed and revealed thrombosed right internal jugular vein. The patient had a favorable outcome and improved with appropriate antimicrobial treatment.

Bahrain Med Bull 2018; 40(1): 61 - 62

Lemierre syndrome (LS) is a rare and life-threatening complication of oropharyngeal infections¹. Its incidence ranges between 0.6 and 2.3 cases per million, and carries a mortality rate of 4% to 18%^{1,2}. Typically, LS includes pharyngotonsillitis or peritonsillar abscess, septicemia related to anaerobic bacteria and internal jugular vein thrombosis^{2,3}. Previous case series reported that Lemierre syndrome could also be induced by other oropharyngeal infections, such as mastoiditis or dental infection^{4,5}.

The aim of this presentation is to report the first case of Lemierre syndrome associated with infected tongue cancer.

THE CASE

An eighty-nine-year-old female was admitted to the intensive care unit (ICU) for hemorrhagic shock. One hour before admission, she had active bleeding from the tongue with an estimated blood loss of 500 ml.

On examination, the patient had an indurated fungating lump on the right lateral posterior aspect of the tongue 10x8 cm. Multiple ulcerated areas were found on the lump and profuse bleeding. Hemostasis achieved with prolonged pressure and local injection of adrenaline. Previous histopathology records revealed that the lesion had been diagnosed one year ago as a moderately differentiated squamous cell carcinoma. Only palliative care was given to the patient, and no surgical intervention was considered.

The clinical assessment revealed that the blood pressure was 82/40 mmHg. Heart rate was 124 beats per minute. The patient had cold and clammy extremities. Laboratory investigations showed: leucocyte count 20640/mm³, Hb 8.9 g/dl, platelets 237

G/L. The coagulation tests and the other laboratory parameters were unremarkable. The patient was intubated and started on mechanical ventilation then transferred to the intensive care unit. Blood pressure improved with fluid resuscitation and the transfusion of two units of packed red blood cells. Antimicrobial therapy, Piperacillin/Tazobactam 4.5 gm/6 hourly for 14 days, was initiated after blood and endotracheal aspirate cultures. Blood cultures performed on admission grew anaerobic Streptococcus spp. The diagnosis of Lemierre syndrome was considered. Therefore, bilateral jugular veins ultrasound Doppler was performed showing a thrombus in the lower segment of the right internal jugular vein, see figure 1. Antimicrobial treatment was continued. However, anticoagulation was not considered because of the high risk of bleeding. The patient was weaned off the mechanical ventilation after three days and discharged to the ward four days later.

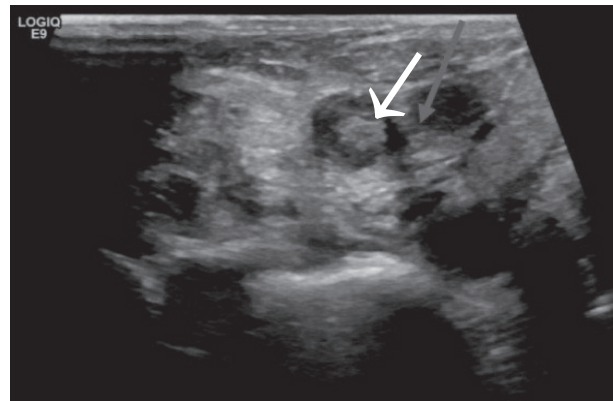


Figure 1: Ultrasound Neck Showing an Echogenic Thrombus in the Lower Segment of Right Internal Jugular Vein (Arrow)

* Consultant
Intensive Care Unit
King Hamad University Hospital
** Registrar
Intensive Care Unit
King Hamad University Hospital.
*** Registrar
Internal Medicine Department
**** Senior Registrar
Radiology Department
King Hamad University Hospital
***** Consultant
Maxillo-facial surgery
E-mail: anis.chaar@khuh.org.bh

DISCUSSION

Lemierre syndrome was first described by André Lemierre in 1936². The syndrome is a triad of oropharyngeal infection, anaerobic septicemia and internal jugular vein thrombosis⁶. Pharyngotonsillitis and peritonsillar abscess are the commonest sources of infection^{2,7}. However, other sources such as dental infection, sinusitis, postoperative complication of maxillofacial surgery and intravenous drug abuse have been reported as possible triggers of Lemierre syndrome^{8,9}. *Fusobacterium necrophorum* a Gram-negative anaerobe microorganism is isolated in 70% to 80% of the cases and positive blood culture^{9,10}. However, *Streptococcus* spp, *Peptostreptococcus* spp, *Bacteroides* spp and methicillin-resistant *Staphylococcus aureus* have been isolated in several cases of Lemierre syndrome^{6,9,11}. The common characteristic of these bacteria is the severity of the local and systemic inflammatory response resulting in septic thrombophlebitis. Therefore, internal jugular vein thrombosis may result either from an extension of the thrombus via the drainage veins or bacteremic dissemination through the lymph nodes¹¹.

To the best of our knowledge, our case is the first report of Lemierre syndrome related to infected tongue cancer. It is also a rare case of Lemierre syndrome occurring in the elderly as most of the cases were reported in young and immunocompetent patients^{2,6,11}. The diagnosis was suspected based on positive blood culture growing *Streptococcus* spp along with oropharyngeal infection. Clinical assessment, radiological investigations, and microbiological tests did not reveal any other infectious site; such screening is of paramount importance. The septic thrombosis of the internal jugular vein might become a source of septic emboli leading to pneumonia, liver abscess or septic arthritis².

Antimicrobial treatment is the cornerstone of management in patients with Lemierre syndrome. Broad spectrum antibiotic should be started as soon as possible. The duration of the antimicrobial treatment is controversial, but authors recommend a duration of 4 to 6 weeks⁹. Our patient was not started on therapeutic anticoagulation as she had a high risk of bleeding. Moreover, anticoagulation and surgical treatment should be considered only in patients who do not improve despite appropriate antimicrobial therapy¹¹.

CONCLUSION

Lemierre syndrome is a rare disease. The diagnosis should be suspected in patients with oropharyngeal infection and septicemia due to anaerobic bacteria. The identification of internal jugular vein thrombosis is essential to confirm the diagnosis of Lemierre syndrome. Management is mainly based on early and appropriate antimicrobial therapy. Our case report highlights that oropharyngeal malignancies can also be the source of sepsis and the leading cause of Lemierre syndrome.

Authors contribution: All authors share equal effort contribution towards (1): Substantial contribution to conception and design, acquisition, analysis and interpretation of data,

(2) Drafting the article and revising it critically for important intellectual content (3): Final approval of manuscript version to be published. Yes.

Conflict of Interest: None.

Competing Interest: None.

Sponsorship: None.

Acceptance Date: 6 February 2018.

Ethical Approval: Approved by the Research and Ethics Committee, King Hamad University, Bahrain.

REFERENCES

1. Riordan T, Wilson M. Lemierre's Syndrome: More Than a Historical Curiosa. *Postgrad Med J* 2004; 80:328-334.
2. Duke C, Alexander K, Hageman JR. An Unusual Cause of Respiratory Distress in a 17-Year-Old Boy. Atypical Lemierre Syndrome. *Pediatr Ann* 2014; 43:20-23.
3. Azzopardi C, Grech R, Mizzi A. Lemierre Syndrome: More Than Just a Sore Throat. *BMJ Case Rep* 2013; 2013.
4. Ben Abdallah Chabchoub R, Riquet A, Ramdane A et al. Lemierre Syndrome Revealed by Torticollis. *Arch Pediatr* 2015; 22:540-543.
5. Boyd D, Paterson P, Dunphy L, et al. A Case Report of Lemierre's Syndrome Associated with Dental Sepsis. *Scott Med J* 2013; 58:e24-27.
6. Ghaly B, Bertram A, Naim A. Lemierre's Syndrome: A Serious Complication of a Routine Dental Procedure. *Aust Dent J* 2013; 58:246-249.
7. Kidambi TD, Lee C, Kohlwes RJ. MRSA-Associated Lemierre's Syndrome in an Intravenous Drug User. *J Gen Intern Med* 2015; 30:1886-1887.
8. Albilal JB, Humber CC, Clokie CM et al. Lemierre Syndrome from an Odontogenic Source: A Review For Dentists. *J Can Dent Assoc* 2010; 76: a47.
9. Abhishek A, Sandeep S, Tarun P. Lemierre Syndrome from a Neck Abscess due to Methicillin-Resistant *Staphylococcus aureus*. *Braz J Infect Dis* 2013; 17:507-509.
10. Ahkee S, Srinath L, Huang A et al. Lemierre's Syndrome: Postanginal Sepsis due to Anaerobic Oropharyngeal Infection. *Ann Otol Rhinol Laryngol* 1994; 103: 208-210.
11. Gupta N, Kralovic SM, McGraw D. Lemierre Syndrome: Not So Forgotten! *Am J Crit Care* 2014; 23:176-179.