

## Successful Outcome in Treating Ventriculitis with Intrathecal Colistin in a Child

AbdulAziz K. AlZailaie, MD\* Ahmed A. Aljarie, MD\*\* Hesham M. Abdelwahab, MD\*\*\*  
Ali A. Asiri, PharmD\*\*\*\* Ibrahim Alnaami, MD, MSc, FRCSC\*\*\*\*\*

**CNS infections due to multi-resistant strains of Acinetobacter pose a serious complication in neurosurgical patients in recent years. The widespread use of antibiotics may have altered the epidemiology of post-neurosurgical CNS infections. Antimicrobial agents to which these strains are susceptible have poor central nervous system (CNS) penetration.**

**We report a case of a five-year-old female patient who was diagnosed with Juvenile Pilocytic Astrocytoma causing hydrocephalus. The tumor was surgically resected. During the procedure, an external ventricular drain (EVD) was inserted. Postoperatively, the patient developed ventriculitis and meningitis. Initially, systemic colistin was administered for four weeks with no improvement in the patient's clinical condition, and the CSF cultures remained positive. Intrathecal colistin was then initiated as a last resort; the patient showed improvement clinically and cerebrospinal fluid (CSF) culture was negative on the fifth day of treatment.**

*Bahrain Med Bull 2018; 40(1): 59 - 60*

CNS infections due to multi-resistant strains of Acinetobacter pose a serious complication in neurosurgical patients. The widespread use of antibiotics may have altered the epidemiology of post-neurosurgical CNS infections. External ventricular drainage (EVD) is one of the procedures most widely performed in neurosurgery associated with a high infection rate of 2-33%. Risk factors for this type of infection include the duration of EVD, inadequate asepsis during manipulation of drain components, increased intracranial pressure and intraventricular hemorrhage<sup>1</sup>.

Gram-positive bacteria are the most frequent cause of EVD infections, followed by Gram-negative bacteria<sup>1</sup>. Among Gram-negative bacteria, Acinetobacter sp. has become an important nosocomial pathogen due to the increase in the number of multi-resistant strains; the species is responsible for a growing number of postoperative infections with a high mortality rate<sup>2</sup>. Antimicrobial agents to which these strains are susceptible have poor central nervous system (CNS) penetration<sup>3</sup>.

Colistin is very effective in the treatment of Acinetobacter infections, but its nephrotoxic and neurotoxic side effects

limit the use of colistin in the treatment of post-neurosurgical infections<sup>2-4,6</sup>. Colistin penetration into the Cerebrospinal fluid is very low<sup>1,3-5</sup>. Thus, intrathecal administration of colistin seems warranted for the treatment of CNS infections from gram-negative bacilli.

The aim of this presentation is to report a case of ventriculitis in a child, successfully treated with intrathecal colistin.

### THE CASE

A five-year-old female patient, not known to have any previous medical illness, presented with ataxic gait for two months. The patient was conscious, alert, oriented and vitally stable. Neurological examination revealed signs of cerebellar ataxia. Laboratory investigations were within normal.

MRI with IV contrast of the head and neck revealed a large mass lesion (measuring 78x67x66 mm) related to the right cerebellar hemisphere and vermis encroaching on the fourth ventricle, see figures 1 and 2.

---

\* Neurosurgical Resident  
Department of Surgery  
Aseer Central Hospital  
Demonstrator, Najran University

\*\* Infectious Disease Consultant

\*\*\* Pediatric Intensive Care Specialist  
Abha Maternity and Children's Hospital

\*\*\*\* Clinical Pharmacist  
Intensive Care Unit  
Aseer Central Hospital

\*\*\*\*\* Assistant Professor  
Adult and Pediatric Neurosurgeon  
Aseer Central Hospital  
Director of Neurosurgery Training Program, King Khalid University  
Kingdom of Saudi Arabia  
E-mail: alza0002@gmail.com

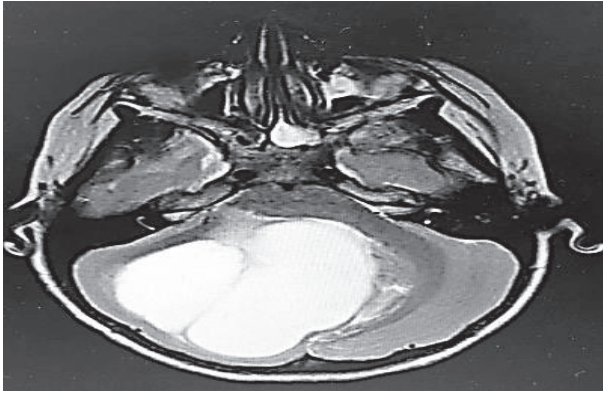


Figure 1: Axial MRI T2-Weighted Image Showing Cerebellar Hyperintense Lesion

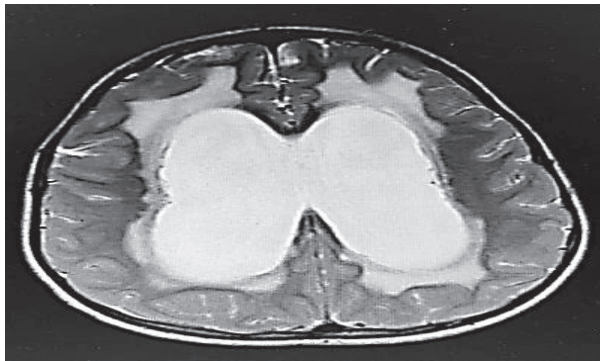

Figure 2: Axial MRI T2-Weighted Image Showing the Enlarged Lateral Ventricles

The pathology of the lesion was Juvenile Pilocytic Astrocytoma (JPA). The tumor was surgically resected. During the procedure, an external ventricular drain (EVD) was inserted. Postoperatively, the patient developed meningitis and ventriculitis. CSF cultures were positive for Gram-negative bacilli (*Acinetobacter* MRAB). Initially, intravenous colistin was administered for four consecutive weeks, but there was no clinical improvement of the patient's condition and CSF cultures remained positive. Failure to sterilize the CSF from *Acinetobacter* with intravenous colistin warranted the intrathecal administration. Colistin was administered intrathecally with a dose of 125,000 IU (10 mg)/day for three weeks. The patient showed improvement clinically, and the cerebrospinal fluid (CSF) culture was negative on the fifth day of treatment.

## DISCUSSION

Karaiskos et al, in a review, found 81 patients (71 adults and 10 pediatrics) who received Colistin intrathecally for a median duration of 18.5 days. Four days is needed to achieve sterilization of cerebrospinal fluid. The rate of a successful outcome was 89%. Colistin toxicity revealed reversible chemical ventriculitis/meningitis in nine cases (11%)<sup>4</sup>.

The sterilization of CSF is reported in almost all treated patients with the use of intrathecal colistin<sup>1,2,4,5,7</sup>. Chemically induced meningeal irritation can cause treatment interruption, but irreversible toxicity has never been documented<sup>1,4,7</sup>.

In another study, 24 patients were identified where clinical and microbiological cure with IT/IVT colistin therapy rates were

83% and 92%, respectively; three patients (13%) developed chemical ventriculitis and one (4%) had treatment-associated seizures<sup>6</sup>. This convincing data led the team to initiate intrathecal colistin as the last therapeutic resort.

## CONCLUSION

**Our study shows that intrathecal colistin is an effective treatment option for MRAB CNS infection. To the best of our knowledge based on PubMed and other medical databases, it is one of the first few reported cases in pediatric population in English literature, and it is the first reported case in the Kingdom of Saudi Arabia. This case report and others reflect the potential safety and efficacy of intrathecal colistin in the management of MRAB CNS infection.**

**Author Contribution:** All authors share equal effort contribution towards (1) substantial contributions to conception and design, acquisition, analysis and interpretation of data; (2) drafting the article and revising it critically for important intellectual content; and (3) final approval of the manuscript version to be published. Yes.

**Potential Conflicts of Interest:** None.

**Competing Interest:** None.

**Sponsorship:** None.

**Acceptance Date:** 24 January 2018.

**Ethical Approval:** Approved by Aseer Central Hospital/Abha Maternity and Children's Hospital, Saudi Arabia.

## REFERENCES

1. De Pascale G, Pompucci A, Maviglia R, et al. Successful Treatment of Multidrug-Resistant *Acinetobacter* Baumannii Ventriculitis with Intrathecal and Intravenous Colistin. *Minerva Anestesiologica* 2010; 76(11):957-60.
2. Saleem AF, Shah MS, Shaikh AS, et al. *Acinetobacter* Species Meningitis in Children: A Case Series from Karachi, Pakistan. *J Infect Dev Ctries* 2011; 5(11):809-14.
3. Markantonis SL, Markou N, Foustieri M, et al. Penetration of Colistin into Cerebrospinal Fluid. *Antimicrob Agents Chemother* 2009; 53(11):4907-10.
4. Karaiskos I, Galani L, Baziaka F, et al. Intraventricular and Intrathecal Colistin as the Last Therapeutic Resort for the Treatment of Multidrug-Resistant and Extensively Drug-Resistant *Acinetobacter* Baumannii Ventriculitis and Meningitis: A Literature Review. *Int J Antimicrob Agents* 2013; 41(6):499-508.
5. Baiocchi M, Catena V, Zago S, et al. Intrathecal Colistin for Treatment of Multidrug-Resistant (MDR) *Pseudomonas Aeruginosa* after Neurosurgical Ventriculitis. *Infez Med* 2010; 18(3):182-6.
6. Khawcharoenporn T, Apisarnthanarak A, Mundy LM. Intrathecal Colistin for Drug-Resistant *Acinetobacter* Baumannii Central Nervous System Infection: A Case Series and Systematic Review. *Clin Microbiol Infect* 2010; 16(7):888-94.
7. Brandão RACS, Braga MHV, de Albuquerque LAF, et al. Multiresistant *Acinetobacter* baumannii ventriculitis. *J Bras Neurocirurg* 2012; 23(2): 172-175.