

## Medical Quiz

Saeed Alhindi, MD, CABS, FRCSI\*

A twenty-five-day-old male infant was presented with left groin swelling of one-week duration. The swelling was increasing in size and was associated with fever. Clinical examination revealed tender groin swelling with limitation of movement of the left hip joint. The patient was treated with intravenous antibiotic without improvement. Ultrasound was performed and revealed subcutaneous edema in the left groin. The patient had the following radiological test:

Look at the figure below and answer the following questions:

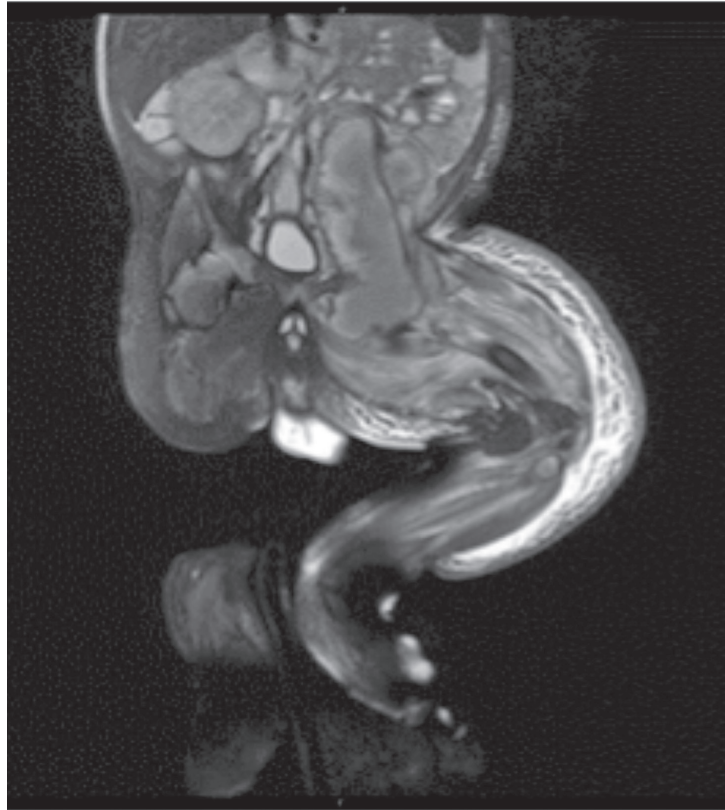


Figure 1

- Q1. Identify the radiological test.
- Q2. Describe the findings in the figure.
- Q3. What is the diagnosis?

Answers on page 76

---

\* Assistant Professor, Arabian Gulf University  
Consultant Pediatric Surgeon  
Department of Pediatrics  
Salmaniya Medical Complex  
P.O. Box 12, Manama  
The Kingdom of Bahrain  
E-mail: sjalhindi@gmail.com