

Unilateral Acanthamoeba Keratitis following the Use of Cosmetic Contact Lens

Aysha Waheed Agab, MB BCH, BAO* Abdul Rahman Albuainain, MB BCH, BAO*
Ghada Al Bin Ali, Saudi Board of Ophthalmology, FRCS (Glasgow)**

Colored lenses were first designed for patients with eye pathologies, such as aniridia or corneal opacity. However, in recent years they have become readily available over-the-counter as cosmetic accessories. Widespread use of these lenses has been noted among young adults. Acanthamoeba keratitis is a rare cause of corneal infection, which is associated with poor visual prognosis. Over the past ten years, improvements in the management of this infection have been documented, yet the best treatment is still primary prevention. Hence, contact lens wearers must be provided with proper instructions regarding contact lens hygiene.

We present a case of unilateral Acanthamoeba keratitis in a cosmetic contact lens wearer who presented with a month history of right eye pain, photophobia, redness and blurred vision. The contact lenses were obtained over the counter, and a history of poor contact lens hygiene was found. The patient was started on empirical treatment initially. The treatment was modified once the diagnosis was confirmed via Giemsa Stain of corneal scrapings, which showed Acanthamoeba cysts. The patient improved markedly and was discharged from the hospital. The disease classically has a slowly progressive, chronic course, with frequent remission periods. Our patient was lost to follow-up due to poor compliance and failure to adhere to guidelines.

Bahrain Med Bull 2017; 39(1): 69 - 71

Acanthamoeba keratitis (AK) is a severe, painful corneal infection caused by Acanthamoeba, a ubiquitous free-living amoeba, which infect the cornea by exposure to contaminated water, usually potentiated by contact lens use.

The first published case of confirmed AK was in 1974. The incidence of the disease increased during the 1980s, corresponding to the widespread use of soft contact lenses. Several studies have shown that Acanthamoeba cysts and trophozoites adhere to several types of contact lenses, suggesting that these lenses may act as a vector for disease transmission. Other documented risk factors include poor lens hygiene, contact lens use while swimming, and water source contamination^{1,2}.

Contact lenses provide therapeutic, visual and cosmetic benefits³. Their use has become widespread in recent years, with the total number of contact lens wearers worldwide estimated to be as high as 140 million in 2005⁴. They are particularly popular among young adults. Cosmetically, they are worn to alter the color or appearance of the eye. Improper use is associated with vision-threatening complications, such as Acanthamoeba keratitis (AK).

The aim of this case is to present potential ocular danger associated with improper and unsupervised cosmetic contact lens use bought over the counter.

THE CASE

A thirty-six-year-old female presented with severe pain, photophobia, blurred vision and redness of the right eye for one-month. A history of daily cosmetic contact lens use was obtained. The patient reported regular cleaning of the contact lenses with tap water. Prior to the presentation, she received antibacterial and antiviral treatment and topical prednisolone acetate 1% with no noticeable improvement.

Uncorrected visual acuity was 6/24 in the right eye and 6/6 in the left eye. Intraocular pressure was 16 in both eyes. Slit-lamp biomicroscopy of the right eye showed severe diffuse conjunctival injection, complete stromal ring infiltrate, corneal edema and a two-millimeter hypopyon, see figure 1 (A and B). The epithelium was intact. There was a 2+ anterior chamber reaction. A differential diagnosis of Acanthamoeba versus fungal stromal keratitis was made. Corneal scraping was performed and the contact lens case was submitted for culture and sensitivity. The patient was admitted. Corticosteroid and antiviral were discontinued and the patient was started on empirical treatment with topical fortified ceftazidime 50 mg/mL and topical fortified vancomycin 25 mg/mL hourly in addition to oral voriconazole 200 mg twice daily.

* Resident

Eye and Laser Centre

** Head of Eye and Laser Centre

Bahrain Defense Force Hospital, Royal Medical Services
The Kingdom of Bahrain

E-mail: a.w.agab@gmail.com, asa.albuainain@gmail.com

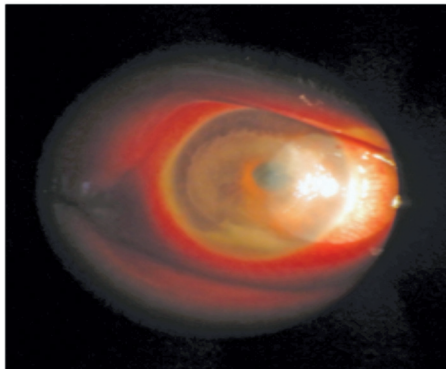


Figure 1 A

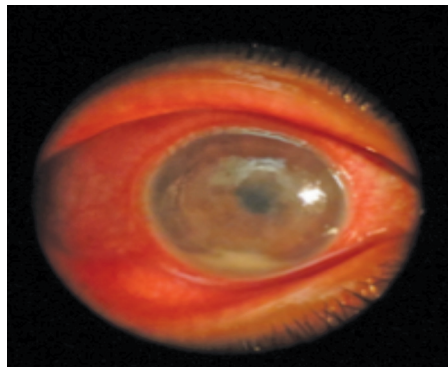


Figure 1 B

Figure 1 (A and B): Slit Lamp Photograph of the Cornea Showing Complete Corneal Ring Infiltrate with Hypopyon caused by Acanthamoeba Keratitis

Giemsa stain showed *Acanthamoeba* cysts, see figure 2. The following anti-acanthamoeba treatment was initiated: Propamide Isethionate 0.1% eye drops hourly while awake, chlorhexidine 0.02% eye drops hourly while awake, lubricant drops six times daily, erythromycin ointment at bedtime and oral voriconazole 200 mg twice daily. The patient had marked improvement. Clinically, the hypopyon disappeared completely after 72 hours and the frequency of propamide isethionate 0.1% and chlorhexidine 0.02% was decreased to every two hours while awake and 1% topical prednisolone acetate was added.

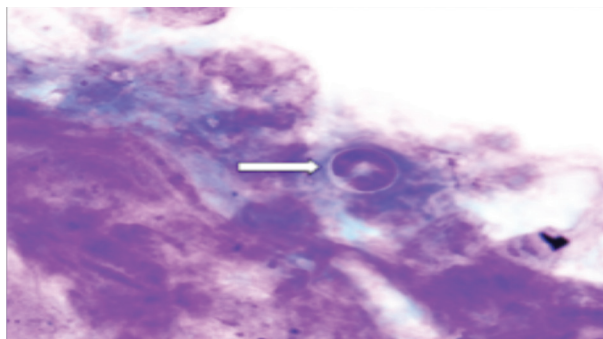


Figure 2: Arrow Pointing at Rounded Acanthamoeba Cyst within the Corneal Epithelial Cells in Cytology Smear (Giemsa Stain, X40)

Contact lens case culture was positive for *Chryseobacterium indologenes* and *Streptococcus pneumoniae* on the right, and

Acinetobacter baumannii and *Pseudomonas aeruginosa* on the left. As a result, moxifloxacin 0.5% hydrochloride eye drops three hourly were added for the right eye and gatifloxacin 0.3% eye drops four times daily for the left eye as prophylaxis. On day four, one-millimeter hyphema was observed on examination; it disappeared the following day.

During initial treatment, the patient underwent periodic epithelial debridement to maximize the drug penetration. Upon discharge, propamide isethionate 0.1% and 0.02% chlorhexidine was reduced to three hourly while awake, oral voriconazole 200 mg twice daily, moxifloxacin hydrochloride 0.5% eye drops four times daily, as well as gatifloxacin 0.3% eye drops four times daily for the left eye. The patient failed follow-up. Five weeks later, she presented with reactivation of the disease due to poor compliance with the treatment. The patient was advised re-admission for intensive treatment; however, the patient refused and was lost to follow-up.

DISCUSSION

Acanthamoeba keratitis is uncommon; however, documented cases have shown that it is a potentially blinding corneal disease. The WHO estimated corneal ulcers to be responsible for 1.5 to 2.0 million new cases of monocular blindness every year⁵. Early recognition and appropriate treatment are essential for restoring vision. The association between AK and concurrent contact lens use was first made in 1984. Eventually, a combination of predisposing factors was identified, such as corneal microtrauma, extended contact lens wear, wear of contact lens inside hot tubs, swimming pools or lakes; in addition to poor lens hygiene including the use of tap water to clean, disinfect and store the lens. Most of contact lens-related AK is seen in soft contact lens users^{1,3,6}.

The disease has a slowly progressive chronic course, with frequent periods of remission. The typical clinical presentation is severe pain, disproportionate to the signs, with superficial keratitis, which is often misdiagnosed as herpes simplex virus (HSV) keratitis, followed by radial keratoneuritis and ring infiltrates (commonly with an overlying epithelial defect) is observed. Therefore, an accurate direct microscopic examination of corneal scrapings is necessary to provide a rapid diagnosis before commencing initial antimicrobial therapy, which could be modified according to culture. Special stains such as calcofluor white and acridine orange have shown to be the most promising; however, they are time-consuming and require special microscopic filters. Hematoxylin and Eosin are quick, inexpensive stains readily available and could evaluate *Acanthamoeba* cysts by an experienced pathologist^{7,8}.

This form of keratitis is not only rare, but also one of the most difficult infections to treat because *Acanthamoeba* could exist in two forms: cysts and trophozoites, cysts are resistant to treatment. Therefore, anti-amoebic treatment must include the use of cysticidal agents. Most published studies recommend combination therapy, which is associated with increased cost, poor compliance and more side effects, such as epithelial toxicity. Furthermore, these medications are associated with poor corneal penetration; thus, periodic epithelial debridement is needed similar to our patient. The average duration of medical therapy is six months to ensure eradication of

organisms emerging from cysts. Recent studies have shown that antifungal drugs, such as voriconazole and natamycin and β -blockers, such as propranolol may possess antifungal properties^{2,5,9}.

Our case was initially misdiagnosed with other types of microbial keratitis. Numerous patients with Acanthamoeba keratitis are misdiagnosed initially and receive treatment targeting more typical forms of infectious keratitis. Consequently, the diagnosis may be delayed if the prescribed topical antimicrobial or corticosteroid results in temporary symptom relief^{2,6}.

In Bahrain, cosmetic contact lenses are readily available over-the-counter from various non-eye care retailers that do not offer eye examination, lens fitting and education regarding proper lens hygiene. Regulatory changes have been made in USA, United Kingdom, Canada and Australia classifying cosmetic contact lenses as medical devices, and thus preventing their distribution without a prescription or proper fitting by an eye care professional^{3,10}. In addition, contact lens related complications are associated with considerable cost to the healthcare system¹⁰.

CONCLUSION

Acanthamoeba keratitis is a potentially sight-threatening infection resulting from unsafe contact lens use. Cleaning contact lenses with tap water rather than using the proper disinfectant solution is a major risk factor to develop Acanthamoeba keratitis. This could be avoided by proper patient education. The serious risks of improper contact lens use needs to be communicated to the public and we strongly advocated regulatory changes restricting the sale of contact lenses without proper consultation.

Author Contribution: All authors share equal effort contribution towards (1) substantial contributions to conception and design, acquisition, analysis and interpretation of data; (2) drafting the article and revising it critically for important intellectual content; and (3) final approval of the manuscript version to be published. Yes.

Potential Conflicts of Interest: None.

Competing Interest: None.

Sponsorship: None.

Acceptance Date: 13 February 2017.

Ethical Approval: Approved by the Department of Ophthalmology, Bahrain Defence Force Hospital, Bahrain.

REFERENCES

1. Joslin CE, Tu EY, Shoff ME, et al. The Association of Contact Lens Solution Use and Acanthamoeba Keratitis. *Am J Ophthalmol* 2007; 144(2):169-180.
2. Alfawaz A. Radial Keratoneuritis as a Presenting Sign in Acanthamoeba Keratitis. *Middle East Afr J Ophthalmol* 2011; 18(3):252-5.
3. Abdelkader A. Cosmetic Soft Contact Lens Associated Ulcerative Keratitis in Southern Saudi Arabia. *Middle East Afr J Ophthalmol* 2014; 21(3):232-5.
4. Stapleton F, Keay L, Jalbert I, et al. The Epidemiology of Contact Lens-Related Infiltrates. *Optom Vis Sci* 2007; 84(4):257-72.
5. Ong HS, Corbett MC. Corneal Infections in the 21st Century. *Postgrad Med J* 2015; 91(1080):565-71.
6. Lindsay RG, Watters G, Johnson R, et al. Acanthamoeba Keratitis and Contact Lens Wear. *Clin Exp Optom* 2007; 90(5):351-60.
7. Grossniklaus HE, Waring GO 4th, Akor C, et al. Evaluation of Hematoxylin and Eosin and Special Stains for the Detection of Acanthamoeba Keratitis in Penetrating Keratoplasties. *Am J Ophthalmol* 2003; 136(3):520-6.
8. Gopinathan U, Sharma S, Garg P, et al. Review of Epidemiological Features, Microbiological Diagnosis and Treatment Outcome of Microbial Keratitis: Experience of Over a Decade. *Indian J Ophthalmol* 2009; 57(4): 273–279.
9. Rahimi F, Hashemian SM, Tafti MF, et al. Chlorhexidine Monotherapy with Adjunctive Topical Corticosteroids for Acanthamoeba Keratitis. *J Ophthalmic Vis Res* 2015; 10(2):106-11.
10. Kerr NM, Ormonde S. Acanthamoeba Keratitis Associated with Cosmetic Contact Lens Wear. *N Z Med J* 2008; 121(1286):116-9.