

## Young Adult with Acute Sigmoid Volvulus

Ahmed Selais, MD, BSc\* Amro Salem, MCh FRCS\*\*  
Raneem El-Jabri, MB BCh BAO(NUI), LRCSI, LRCPI\*\*\*

**Many studies describe sigmoid volvulus as commonly seen in elderly patients with psychiatric or neurological comorbidities or who are bed bound. However, recent studies suggest that this condition is seen amongst ambulatory previously healthy young patients.**

**We report a case of a young male patient with sigmoid volvulus. He was diagnosed radiologically using plain abdominal roentgenography which was confirmed using abdominal CT scan. Surgical intervention initially followed the endoscopic detorting method for the acute relief of the volvulus, followed by laparotomy, sigmoid resection with primary anastomosis upon recurrence of the volvulus within 24 hours from detortion.**

*Bahrain Med Bull 2019; 41(3): 171 - 173*

Sigmoid volvulus is the most common cause of volvulus; however, it may also involve the cecum (<20%) or the transverse colon<sup>1</sup>. The incidence varies from 8% in the developed countries to 80% in developing countries. It is also estimated to be four times more common in the Middle East compared to Western countries<sup>1</sup>.

A volvulus occurs when a redundant loop of bowel twists about its own mesentery. Rarely, it develops when an ileal loop twists around the sigmoid; this is known as ileosigmoid knotting<sup>2</sup>. Chronic constipation resulting in a dilated redundant colon, along with a narrow mesenteric base, are important predisposing factors to volvulus development. When the degree of twisting exceeds 180 to 360 degrees, it compromises the vascular perfusion of the twisted bowel loop; thus leading to complications of colon obstruction, such as ischemia, strangulation, gangrene and ultimately perforation and fecal peritonitis<sup>2</sup>. Patients may otherwise present with intermittent chronic volvulus with a long history of recurrent obstructive symptoms.

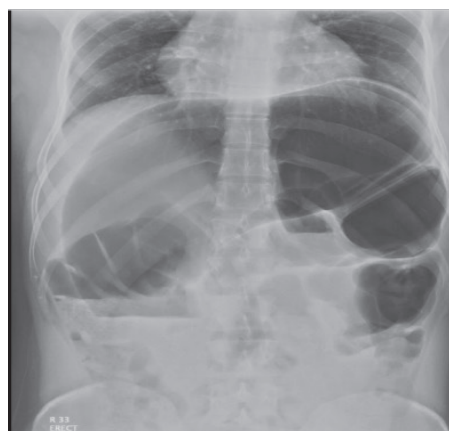
The aim of this presentation is to report a case of a young healthy adult with acute sigmoid volvulus who was managed endoscopically and surgically.

### THE CASE

A twenty-eight-year-old male from the Indian subcontinent presented with a gradually increasing colicky generalized abdominal pain and constipation for four days. The pain was associated with three episodes of non-bilious vomiting. The patient was a resident of Bahrain for 4 years with no previous medical or surgical history. He was afebrile and vitally stable at the time of examination. The patient's abdomen was mildly distended and tympanic with generalized tenderness; however, he was non-peritonitic. Digital rectal examination revealed an empty rectum, with no obvious masses.

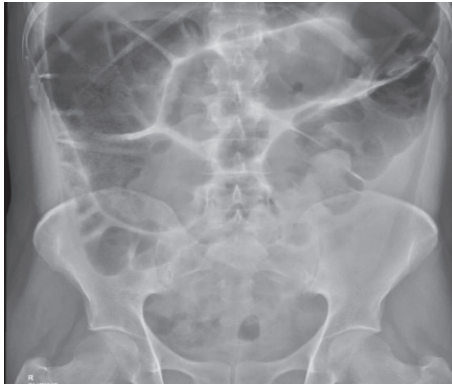Abdominal roentgenography revealed a markedly distended large bowel with gases and fecal matter. Air-fluid levels were noted. No free air under the diaphragm. The patient's WBC count was 10,760/mm<sup>3</sup> with a neutrophil percentage of 87%. Serum electrolytes were as follows: sodium 141 mmol/L (normal range is 134–145 mmol/L), potassium 3.7 mmol/L (normal range is 3–5 mmol/L), urea 4.2 mmol/L (normal range is 2.9–9.3 mmol/L), and creatinine 96 mmol/L (normal range is 80–115 mmol/L). Abdominal CT scan revealed sigmoid volvulus. Successful detorsion was attempted endoscopically. No gangrenous or ischemic patches were seen. Therefore, the rectal tube was left in place. The rectal tube was removed the next day; the patient was discharged once oral feeding was tolerated in the absence of abdominal pain or distention.

The patient returned to the emergency unit 5 days after discharge with a three-day history of symptoms similar to his initial presentation, along with the same examination and radiological findings, see figures 1-3. The sigmoid colon was successfully detorted endoscopically and the absence of ischemic changes within the colon wall was confirmed.

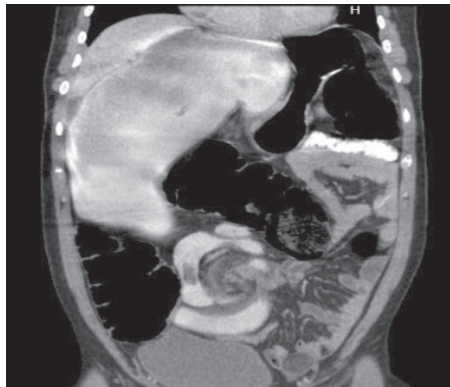


**Figure 1: An Erect View Abdominal X-ray Showing Coffee Bean Sign**

\* Senior House Officer  
\*\*\* Consultant  
Department of General Surgery  
King Hamad University Hospital  
Kingdom of Bahrain  
E-mail: Ahmed.selais@khuh.org.bh



**Figure 2: A Supine View Abdominal X-ray Showing Coffee Bean Sign**



**Figure 3: CT Abdomen and Pelvis Showing Whirl Pool Sign**

An urgent laparotomy with sigmoid colectomy and primary anastomosis was performed the next day.

## DISCUSSION

The prevalence of sigmoid volvulus varies between the developed countries; in the United States, it accounts for less than 10% of large bowel obstruction, whereas in developing countries, such as Bolivia, it accounts for 80 %<sup>2</sup>. The prevalence of sigmoid volvulus in the Middle East was documented to be four times that of the Western world<sup>2</sup>. Sarfaraz et al reported 4 cases of acute sigmoid volvulus in patients between 25 and 35 years<sup>2</sup>. This series raised the possibility of acute sigmoid volvulus amongst young adults with a mean age of 27.5 years. Previous studies suggested a mean age of 57.9 and 74 years<sup>3-5</sup>.

Our reported case is similar to the cases reported by Sarfaraz et al in that both are young adults, with no comorbidities or history of previous abdominal surgery<sup>2</sup>. In addition, both identified with poor dietary habits such as the consumption of processed food high in calories but low in nutritional content (junk food) and low fibers. Poor hydration, in addition, to the heat and humidity of the climate lead to greater water loss from the body. The harsh weather conditions encourage a sedentary lifestyle of commuting by cars, which poses a strong risk factor for long-standing constipation and acute sigmoid volvulus.

According to Heis et al, abdominal pain (96%) is the most common clinical symptom followed by distension (84%) and constipation (63%)<sup>6</sup>. Sarfaraz et al found abdominal

pain in 100% of cases; 50% with constipation and 50% with obstipation<sup>2</sup>. The current case presented with all the above symptoms, with abdominal pain being the first recognized symptom.

Plain abdominal roentgenography is a useful initial diagnostic tool in cases of bowel obstruction. Coffee-bean, bent inner tube or omega signs are suggestive of sigmoid volvulus as found in 68.7% of patients by Heis et al<sup>6</sup>. Sigmoid volvulus was diagnosed with plain abdominal roentgenography alone in 34.6% of cases as described by Tiah et al<sup>3</sup>. Abdominal CT provides the additional advantage of excluding other causes of intestinal obstruction in uncertain cases and facilitates the diagnosis of complications due to rare causes of sigmoid volvulus, such as ileosigmoid knotting.

The initial treatment of acute sigmoid volvulus is urgent endoscopy if the patient is clinically stable and his imaging studies excluded signs of perforation or strangulation. A flexible sigmoidoscope or colonoscope is advanced cautiously to the site of obstruction. The sigmoid colon decompresses successfully in 70-90% after insufflation and application of gentle pressure of the tip of the scope to the distal point of sigmoid obstruction. The colonic walls should then be inspected for mucosal ischemia and gangrenous changes. Urgent laparotomy with resection of the affected bowel and Hartmann's procedure is indicated if endoscopic decompression fails, mucosal wall changes, the patient is clinically unstable, or imaging is suggestive of strangulation or perforation of bowel loops segments. Otherwise, semi-elective sigmoid resection with primary anastomosis is ideally carried out following successful decompression, given that the mucosal wall inspection post-decompression is not ischemic or gangrenous.

Patients managed with decompression alone are at 50% risk of recurrence within the first year.

## CONCLUSION

**Acute sigmoid volvulus should be considered in the differential diagnosis of young adults with generalized abdominal pain and constipation or obstipation, especially in the absence of previous medical or surgical history.**

---

**Author Contribution:** All authors share equal effort contribution towards (1) substantial contributions to conception and design, acquisition, analysis and interpretation of data; (2) drafting the article and revising it critically for important intellectual content; and (3) final approval of the manuscript version to be published. Yes.

**Potential Conflicts of Interest:** None.

**Competing Interest:** None.

**Sponsorship:** None.

**Acceptance Date:** 6 May 2019.

**Ethical Approval:** Approved by the Research and Ethical Committee, King Hamad University Hospital, Bahrain.

**REFERENCES**

1. Brunnicardi F, Anderson D, Billiar T, et al. Schwartz's Principles of Surgery. 10th ed. New York: McGraw-Hill; 2015; 1219-1220.
2. Sarfaraz M, Hasan S, Lateef S. Sigmoid Volvulus in Young Patients: A New Twist on an Old Diagnosis. *Intractable & Rare Diseases Research* 2017; 6(3):219-223.
3. Tiah L, Goh S. Sigmoid volvulus: diagnostic twists and Turns. *European Journal of Emergency Medicine* 2006; 13(2):84-87.
4. Ören D, Atamanalp S, Aydinli B, et al. An Algorithm for the Management of Sigmoid Colon Volvulus and the Safety of Primary Resection: Experience with 827 Cases. *Diseases of the Colon & Rectum* 2007; 50(4):489-497.
5. Liang J, Lai H, Lee P. Elective Laparoscopically Assisted Sigmoidectomy for the Sigmoid Volvulus. *Surgical Endoscopy* 2006; 20(11):1772-1773.
6. Heis H, Bani-Hani K, Rabadi D, et al. Sigmoid Volvulus in the Middle East. *World J Surg* 2008; 32(3):459-464.