

## Spontaneously Expelled Giant Submandibular Stone

Hasan Alansari, MB BCh BAO, MRCS (ENT)\* Fahad Bedawi, DOHNS, MRCS (ENT)\*\* Waleed Janahi, FRCS\*\*\*

**Sialolithiasis of the submandibular gland present in various sizes and may be associated with sialadenitis. It is rare to find sialolith exceeding 30 mm long or larger.**

**We present a case of a spontaneously expelled submandibular stone. A thirty-six-year-old male presented with recurrent left submandibular swelling associated with pain and bitter taste in mouth. The swelling was increasing during meal times. On examination, a hard mass was felt in the floor of the mouth, X-ray revealed large radio-opaque mass within the Wharton's duct which was expelled spontaneously without surgical intervention**

*Bahrain Med Bull 2020; 42 (3): 216 - 217*

Sialolithiasis is the most common disease of the salivary gland, the submandibular gland is the most frequently affected. It has been estimated that more than 12 out of 1,000 adult patients have been affected and at least 92% of all sialolithiasis cases manifest in the submandibular gland, while the parotid is affected in only 6% and 2% is the sublingual gland<sup>1,2,3</sup>. Sialolithiasis tends to be more frequent in males than females and rarely ever occurs in children<sup>4,5</sup>.

Sialolithiasis is caused by the precipitation of amorphous tricalcium phosphate which leads to new deposits of different substances that eventually form stone<sup>6</sup>.

The size of submandibular stones usually range from 1mm to 10mm; a stone measuring over 15mm is considered a giant salivary gland stone and is a rare occurrence. There have been reports of stones that measure over 30mm, which is considered to be a rare finding<sup>7,8</sup>.

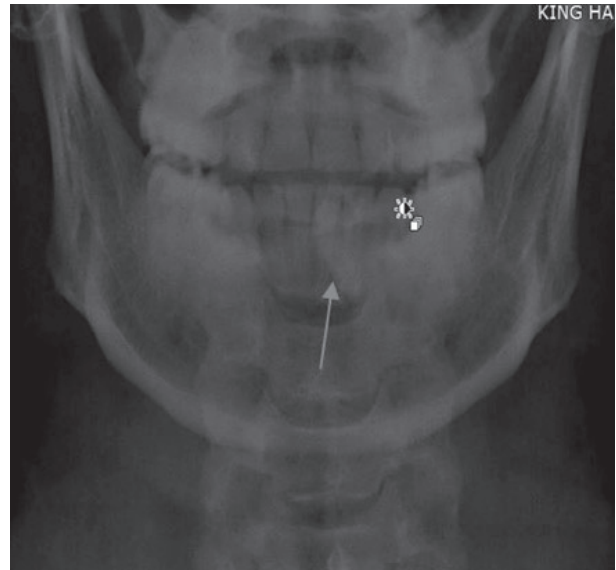
The aim of this presentation is to report a case of giant submandibular stone measuring 30mm, which was expelled from the Wharton's duct spontaneously.

### THE CASE

A thirty-six-year-old male smoker presented with a 2-week history of left-sided submandibular swelling extending to the left side floor of the mouth, increasing in size and was associated with dull pain, worse during eating and affected his sleep. The patient also complained of bitter taste in his mouth with yellowish red discharge. Further history revealed that he had similar episodes for 4 years but of milder severity that was managed conservatively. On examination, the patient was vitally stable, not in distress and afebrile. An oval-shaped cystic swelling was found in the left-digastric triangle measuring 4x3cm, it was tender with no overlying skin changes. Intraoral examination revealed a swelling in the left floor of the mouth with blood-stained discharge coming from the Wharton's duct. Bimanual examination revealed a swollen left submandibular

gland with a hard longitudinal lump on the floor of the mouth.

Blood investigations were all within normal limits except for C-reactive protein, which was mildly elevated. Anterior submandibular X-ray revealed a large radio-opaque mass on the left side floor of the mouth, see figure 1. The patient was managed with IV Augmentin and IV paracetamol.

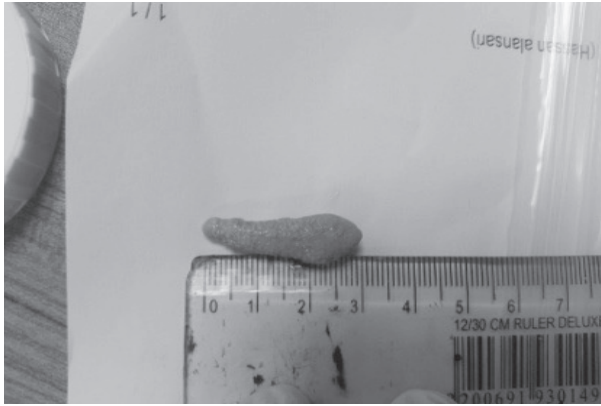

**Figure 1: X-ray of Oral Cavity, Arrow Pointing to Stone**

After the night of admission and IV Augmentin and IV paracetamol, the patient spat a large 30mm stone, which relieved most of his symptoms, see figure 2. The patient became pain-free and the swelling had subsided. The patient was discharged on oral Augmentin with a follow-up within 2 weeks.

---

\* Registrar  
\*\* Registrar  
\*\*\* Consultant  
Department of ENT  
King Hamad University Hospital  
Kingdom of Bahrain  
E-mail: hassan.alansari21@gmail.com



**Figure 2: Giant Submandibular Stone**

## DISCUSSION

Sialolithiasis is most commonly found in the submandibular gland. It is thought to be due to high alkaline concentration of submandibular secretions, a high amount of calcium and phosphate, long and tortuous Wharton's duct and the flow of saliva against gravity<sup>1,9</sup>.

In 60% of cases, a submandibular stone presents as a painful swelling, usually worse at mealtime. However, they may also present as a painless swelling or only pain. It is important to palpate the floor of the mouth for masses and observing the secretion or discharge of the salivary gland openings and look for osteophyte<sup>10-12</sup>.

The use of imaging studies is valuable in the diagnosis of submandibular stones; an ultrasound can reveal at least 99% of intraductal stones that have a diameter of 1.5mm. X-rays have been shown to be useful because almost 90% of submandibular stones are radio-opaque, which was demonstrated in our patient. Sialography is another imaging modality which consists of opacification of the duct with a water-soluble contrast medium; it is, however, contraindicated in patients who have an acute infection and those who are sensitive to the contrast medium. CT scan has become the imaging modality of choice because it is not invasive; however, it does expose the patients to a large amount of radiation. Sialendoscopy is another diagnostic method that allows a complete exploration of the ductal system and direct visualization of duct pathology<sup>13</sup>.

In the acute phase and with the presence of infection, antibiotics and supportive care is a must. After the infection subsides, treatment modality can be chosen. In small stones, a non-invasive modality with hydration, NSAIDs, citrus food to increase salivation and massaging. Extracorporeal shock lithotripsy can be performed to extrude the stone. Sialendoscopy is diagnostic and therapeutic for salivary duct stones. In larger stones or small stones not responding to conservative measures, a surgical approach to restore the flow of saliva is required. Transoral sialolithectomy can be performed and an artificial fistula to regulate the flow of saliva. For stones located within the gland or recurrent sialolith formation with recurrent obstruction and infection, surgical removal of the gland is advisable<sup>10-13</sup>.

## CONCLUSION

**Sialolithiasis of the submandibular gland present in various sizes and may be associated with acute or chronic sialadenitis. Our case had a giant stone of more than 30 mm, which was managed conservatively and extruded on its own.**

**Author Contribution:** All authors share equal effort contribution towards (1) substantial contributions to conception and design, analysis and interpretation of data; (2) drafting the article and revising it critically for important intellectual content; and (3) final approval of the manuscript version to be published. Yes.

**Potential Conflicts of Interest:** None.

**Competing Interest:** None.

**Sponsorship:** None.

**Acceptance Date:** 7April 2020.

**Ethical Approval:** Approved by the Research and Ethics Committee, King Hamad University Hospital, Bahrain.

## REFERENCES

1. Leung A, Choi M, Wagner G. Multiple Sialoliths and a Sialolith of Unusual Size in the Submandibular Duct Case Report. *Oral Surgery, Oral Medicine, Oral Pathology, Oral Radiology, and Endodontology* 1999; 87(3): 331-333.
2. Iro H, Schneider HT, Födra C, et al. Shockwave Lithotripsy of Salivary Duct Stones. *Lancet* 1992; 339:1333-6.
3. El Deeb M, Holte N, Gorlin RJ. Submandibular Salivary Gland Sialoliths Perforated Through the Oral Floor. *Oral Surg Oral Med Oral Pathol* 1981; 51:134-9.
4. Nahiel O, Eliav E, Hasson O, et al. Pediatric Sialolithiasis. *Oral Surg Oral Med Oral Pathol Radiol Endod* 2000; 90:708.
5. McKenna JP, Bostock DJ, McMenamin PG. Sialolithiasis. *Am FamPhysician* 1987; 36:119-25.
6. Bodner L. Parotid Sialolithiasis. *The Journal of Laryngology & Otology* 1999; 113(3): 266-267.
7. Ledesma-Montes C, Garces Ortiz M, Salcido-Garia S, et al. Giant Sialolith, Case Report a Review of Literature. *J Oral Maxillofac Surg* 2007; 65:128-30.
8. Emegoakor C, Chianakwana G, Ugonabo M, et al. An Unusually Large Submandibular Gland Stone. A Case Report. *Nigerian Journal of Surgery* 2011; 15(1-2): 15-17.
9. Raksin SZ, Gould SM, Williams AC. Submandibular Duct Sialolith of Unusual Shape and Shape. *J Oral Surg* 1975; 33:142-5.
10. Siddiqui SJ. Sialolithiasis: An Unusually Large Submandibular Salivary Stone. *British Dental Journal* 2002; 193(2): 89-91.
11. Alkurt MT, Peker i. Unusually Large Submandibular Sialoliths: Report of Two Cases. *Eur J Dent* 2009; 3(2): 135-139.
12. Arslan S, Vuralkan E, Iu BC, et al. Giant Sialolith of Submandibular Gland: Report of a Case. *Journal of Surgical Case Reports* 2015; 4:1-3.
13. Bull PD. Salivary Gland Stones: Diagnosis and Treatment. *Hospital Medicine* 2001; 62(7): 396-399.