

Medical Quiz

Saeed Alhindi, MD, CABS, FRCSI*

A 10-month-old male presented with vomiting for one-day duration after ingestion of a foreign body. No history of fever or change in bowel habits. Clinical examination revealed a non-tender abdomen. The patient underwent a radiological investigation. Look at the figure below and answer the following questions:

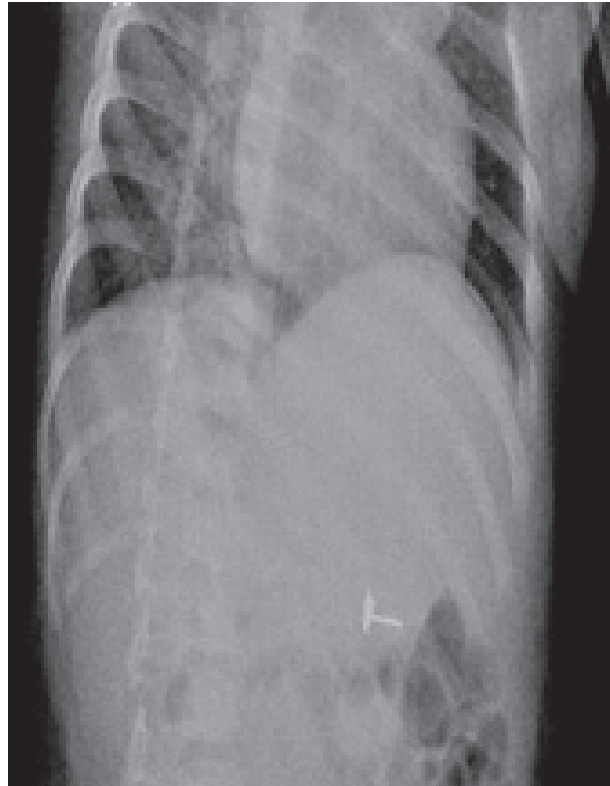


Figure 1

- Q1. Mention the radiological test and the findings in the figure.
- Q2. Mention two possible complications that can occur in this case.
- Q3. What is the management of this case?

Answers on page 232

* Assistant Professor, Arabian Gulf University
Consultant Pediatric Surgeon, Salmaniya Medical Complex
P.O. Box 12
Kingdom of Bahrain
E-mail: sjalhindi@yahoo.com, sjalhindi@gmail.com