

Answers to Medical Quiz

Alaa Zidan*

- A1. MRI findings : There is a liquid collection between the capsule and the rotator cuff, sagittal views show this collection between supraspinatus and infraspinatus.
- A2. Diagnostic arthroscopy showed a SLAP lesion with a bucket handle tear; the biceps anchor is loose. There is no intra-articular abnormality.
- A3. Physical findings are highly suspect of a "hidden" intrasubstance partial RC tear which often accompany SLAP lesions. MRIs do not necessarily correlate well to intra-arthroscopic findings (especially for partial thickness tears: sensitivity 20%, specificity 88%, pos. pred. val. 20%, neg. pred. val. 88%, and overall accuracy 79% - This lesion looks substantial enough that it should also show up on diagnostic ultrasound if you need further verification.

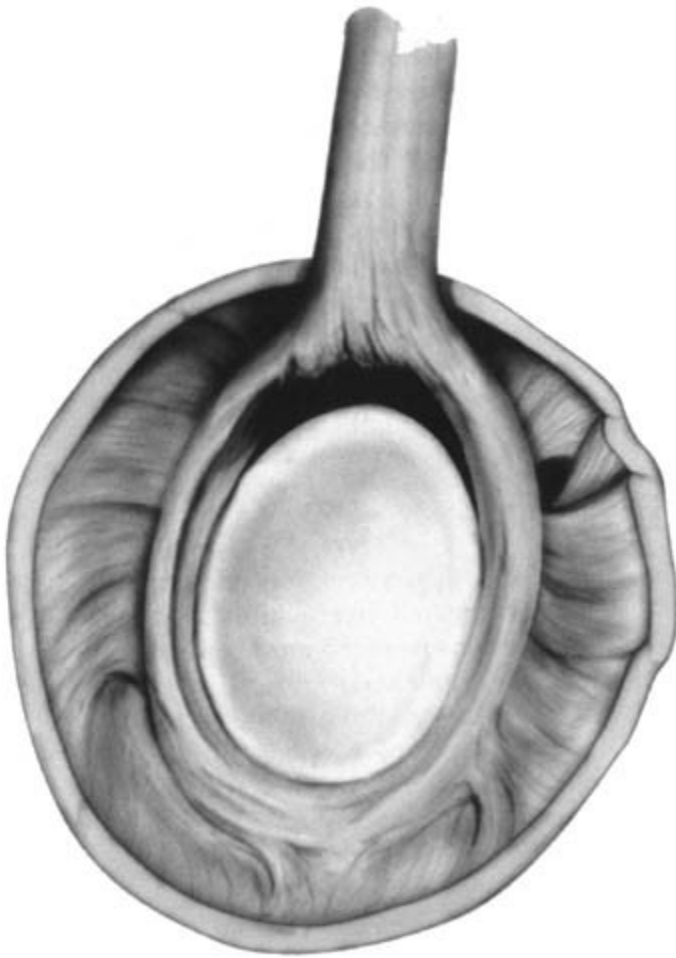
DISCUSSION

SLAP lesion stands for a tear of the superior labrum, from anterior to posterior. The labrum is a thin ring of tissue that surrounds the rim of the shoulder socket, deepening the socket and increasing the stability of the shoulder joint. At the top of the socket, or '12 o'clock' position, the biceps tendon also inserts into the labrum, SLAP lesion is due to a traction injury, is a common cause. A fall on the outstretched arm, or repetitive activities such as pitching may predispose to this injury.

The clinical presentation of SLAP lesion is pain of the shoulder radiating to the arm, a sense of catching may be felt, or deep aching that persists, high index of suspicion is needed, as diagnosis based on physical examination is extremely difficult. X-rays are rarely helpful, MRI scans are frequently inaccurate¹, a well – placed injection of local anesthetic into the shoulder joint will temporarily relieve symptoms suggesting the diagnosis, anti inflammatory medication and rest may relief the symptoms. Arthroscopic surgery with either repair of the torn tissue, or removal of the torn piece, is the treatment of choice².

Synder in 1990, after reviewing this arthroscopic series. Identified four types of Superior labrum lesions involving the biceps anchor and called them **S.L.A.P lesions**, (Superior Labrum from Anterior to Posterior lesion).

He also developed the arthroscopic technique for the treatment of these lesions with special references to type II and type IV, in these cases the reattachment of the superior labrum contributes in restoring the stability of the glenohumeral joint



Type II Slap lesion

Typical symptoms of a SLAP lesion include a catching sensation, pain with movement, and susceptibility to dislocation. Diagnosis can be quite difficult, as these injuries do not show up well on MRI scans. Usually, the diagnosis is made by Arthroscopy.

REFERENCES

1. Chamberline B, McAndrew D. MRI Assessment of the rotator cuff: Is it really accurate? *Arthroscopy* 1997;13:710-19
2. Esch JC, Baker CL. *Arthroscopic Surgery. The Shoulder and Elbow.* JB Lippincott 1993.