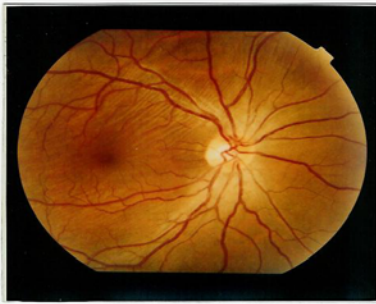


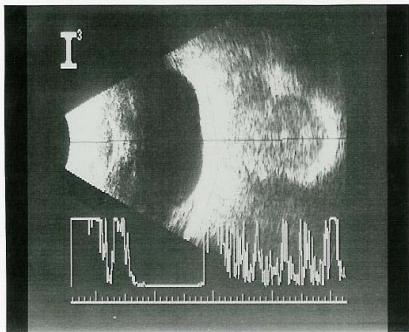
## **MEDICAL QUIZ**

Mohinder Singh, FRCS, FRC Ophth\*

Thirty-seven years old Asian manual worker presented with history of gradually diminishing vision in his right eye since two months. He denied any injury to the eye and there was no positive medical history. His uncorrected visual acuity was recorded as 6/18 in the right and 6/6 in the left eye. Right eye vision could be improved to 6/6 by correcting the hypermetropic error. Intraocular pressure was 16 mm Hg in each eye and anterior segments were unremarkable. Fundus picture and echography of the right eye are shown.



**Figure No 1: Fundus photograph of the right eye.**



**Figure No 2: A & B scan of the right eye and orbit.**

1. What abnormality is present in the fundus?
2. What information do you get from the ocular echography?
3. Why is the right eye vision reduced?
4. Which other single relevant investigation should be done?