

## **Medullary Renal Cell Carcinoma Case Report**

Mohammed Abdulla Al-Tantawi MBBCH, CABS\* Abdul Amir Issa MBBCH, CABS\*\*\*  
Mohammed Abdulla MBBCH, CABS\*\* Mohammed Redha Samie MBBCH, FRCS(1)\*

**This is a case report of a medullary renal carcinoma in a sickle cell trait patient. The clinical, histological, and radiological features of this tumor are described, and the chemotherapeutic regimens used in this disease are discussed. Treatment modalities have proved largely unsuccessful in advanced disease.**

**Medullary renal cell carcinoma is characterized by a lack of early warning signs, diverse clinical manifestations and resistance to radiotherapy and chemotherapy.**

**Awareness and early diagnosis may prove essential in improving the survival rate.**

***Bahrain Med Bull 2005; 27(4):***

Medullary renal carcinoma is a recently recognized epithelial malignant tumor arising from the renal parenchyma. This tumor is almost exclusive to patients with the sickle cell trait. Most patients present with metastatic disease and have a poor prognosis<sup>1</sup>.

The kidney in patients with sickle cell disease exhibits numerous structural and functional abnormalities that are seen along the entire length of the nephron. The environment of the renal medulla is characterized by hypoxia, acidosis, and hypertonicity. Because these conditions promote hemoglobin S (Hb S) polymerization and red cell sickling, this area of the kidney is particularly susceptible to disorders<sup>1</sup>.

In 1974, Berman categorized the six nephropathies of sickle cell disease or sickle cell trait as haematuria, papillary necrosis, nephrotic syndrome, renal infarction, hyposthenuria, and pyelonephritis<sup>1</sup>.

Davis et al, in 1996, described a highly aggressive tumor of renal calyceal origin in young patients with sickle cell disease, and designated this “renal medullary cancer”, the seventh sickle cell nephropathy<sup>2</sup>.

---

\* Consultant Urologist  
\*\* Chief Resident  
\*\*\* Senior Resident  
Urology Unit, Department of Surgery  
Salmaniya Medical Complex  
Kingdom of Bahrain

A case of renal medullary cell carcinoma is presented with review of literature.

## **THE CASE**

A twenty-five year old male was admitted with the main complaint of right flank pain for three weeks; it was associated with intermittent haematuria and low-grade fever. The patient was sickle cell trait positive and had Glucose-6-phosphate dehydrogenase reduced activity.

On clinical examination, no abdominal mass was felt. Routine blood investigations were normal, and urinalysis showed microscopic haematuria. Intravenous pyelogram showed no contrast excretion on the right side, and normal left kidney (Figure 1). Ureteroscopy with retrograde contrast study showed a filling-defect in the right renal pelvis. Abdominal computerized tomography showed a mass in the right renal pelvis extending into the proximal 4-5 cm of the ureter, and enlarged hilar renal lymph nodes (Figure 2). CT scan of the chest showed bilateral metastases (Figure 4).

Figure 1, 2 & 4

Right nephroureterectomy was performed as the initial clinical diagnosis was transitional cell carcinoma. Intraoperatively, the findings were: A large mass arising from the renal pelvis invading the psoas muscles, with multiple enlarged hilar renal lymph nodes encasing around the renal vessels. The postoperative period was uneventful, and the histological diagnosis was very poorly differentiated medullary renal cell carcinoma, (Figure 3). The histopathological report showed that it was grade 3 medullary carcinoma, which had invaded the renal parenchyma and perinephric fat with microscopic tumour nodules in the cortex, and marked vascular invasion. Postoperatively, the patient was given eight cycles of chemotherapy (Docataxel, Gemcitabine Hydrochloride and Cisplatin).

Figure 3

Eight months after surgery the patient was doing well and was gaining weight. CT of the chest eight months after treatment did not show any sign of metastasis and his hilar lymph nodes had diminished in size from 12 cm to 1-2 cm post treatment.

## **DISCUSSION**

The existence of renal cell carcinoma in some patients with sickle cell disease was reported by Baron et al and later confirmed by Davis et al<sup>2,3</sup>.

In their original description of 33 patients, Davis et al. observed that there was a male predominance under 25 years of age; both sexes were equally affected in the 3rd decade of life. In 25 black patients, gross haematuria and abdominal flank pain were the most frequent clinical symptoms. Less frequently, weight loss and a palpable mass were found. Data available on 19 patients showed survival of only 15 weeks postoperatively; it is an evidence of the aggressive nature of the tumor<sup>2</sup>. Gross pathology revealed involvement of the right kidney in 23 of the 33 patients. Most of the tissue sections had satellite nodules in the renal cortex with extension to

the perinephric and peripelvic soft tissue; characteristics that have been used to detect the presence of tumor in previous radiologic studies<sup>4</sup>. A pathological description is one of a lobulated pattern with the tumor located in the renal medulla, which is firm with variable areas of necrosis and haemorrhage<sup>5</sup>. Microscopically, the tumor presents a reticular or adenoid cystic pattern with regions of poor differentiation in a stroma with a mucinoid, myxoid, and or oedematous appearance.

Renal medullary carcinoma is a recently described as highly aggressive tumor, occurring predominantly in young patients with sickle cell trait; they usually present with metastasis. Surgery, radiotherapy and chemotherapy do not appear to alter the course of the disease, and the survival time is very short. Presentation is usually with haematuria, abdominal pain and weight loss. Forty-nine patients have been reported from the USA; of whom 47 were African-American<sup>5</sup>. On review of the imaging findings it is possible for a radiologist to suggest a specific diagnosis within the appropriate characteristic and clinical setting<sup>6</sup>.

Current studies demonstrate that there are common elements associated with the clinical presentation of renal medullary carcinoma<sup>8</sup>. In young adults who have abnormalities of the hemoglobin gene and present with persistent abdominal pain, renal medullary carcinoma should be considered. Haematuria gives more concern especially if it is found to be on the right side; because the tumour is more predominant (70-80%) in the right kidney.

Computerized tomography is the investigation of choice for renal medullary carcinoma; in this case it showed highly suspicious bilateral chest metastatic nodules. In all cases radical nephrectomy is recommended.

There is no effective treatment option for advanced renal medullary carcinoma. Patients treated with surgery and chemotherapy had a mean survival of 32 weeks compared to those who had surgery alone where the survival was 19 weeks<sup>5</sup>. Renal medullary carcinoma is clearly resistant to chemotherapy as well as to immunotherapy.

## **CONCLUSION**

**Medullary renal carcinoma is an aggressive neoplasm, and the disease is not affected by different treatment modalities.**

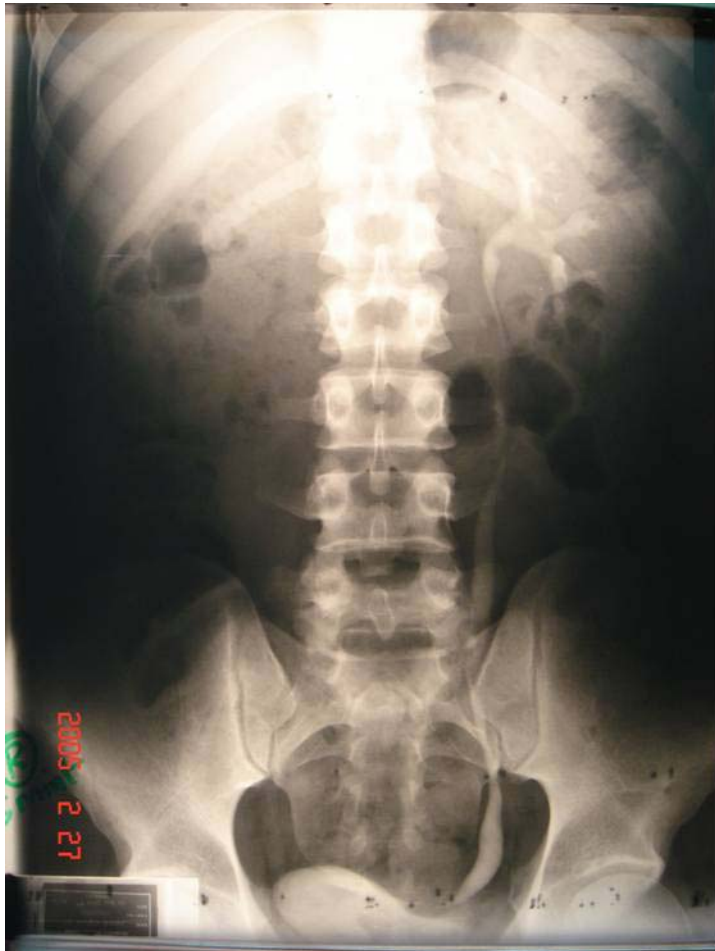**This patient was treated by nephroureterectomy and chemotherapy; and eight months later his chest metastasis could not be seen on CT scan; renal hilar lymph nodes had diminished in size from 12 cm to 1-2 cm only. He started gaining weight and he resumed his normal activities.**

## **REFERENCES**

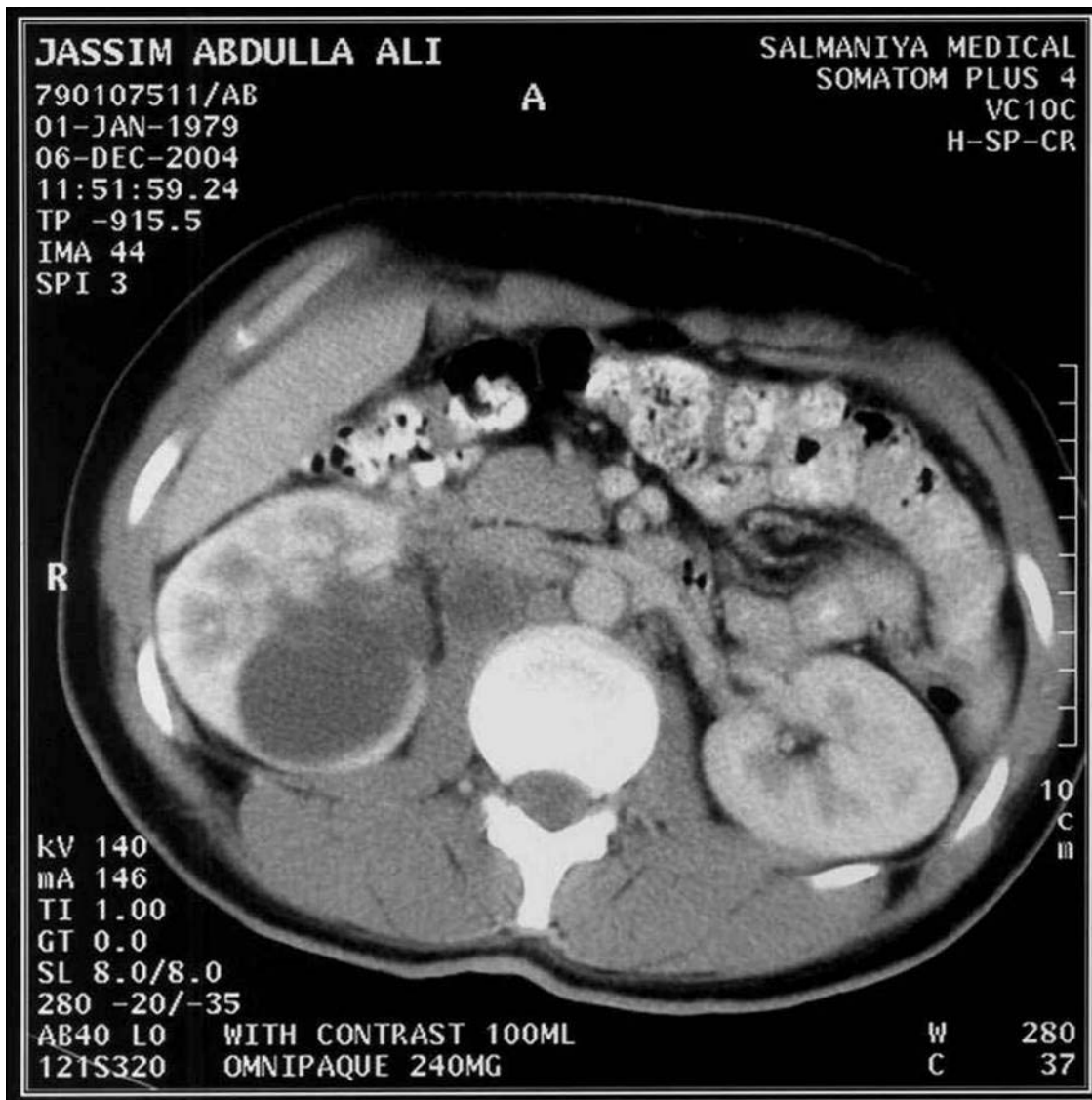
1. Berman LB. Sickle Cell Nephropathy. JAMA 1974;1228-79.
2. Davis CJ Jr, Mostofi FK, Sesterhenn IA. Renal medullary carcinoma. The seventh sickle cell nephropathy. Am J Surg Pathol 1995;119:1-11.
3. Baron BW, Mick R, Baron JM. Haematuria in sickle cell anaemia—not always benign:

Evidence for excess frequency of sickle cell anaemia in African Americans with renal cell carcinoma [Review]. *Acta Haematol* 1994;92:119-22.

4. Davidson AJ, Choyke PL, Hartman DS, et al. Renal medullary carcinoma associated with sickle cell trait: Radiologic findings. *Radiology* 1995;195:83-5.
  5. Avery RA, Harris JE, Davis CJ, et al. Renal medullary carcinoma: Clinical and therapeutic aspects of a newly described tumor. *Cancer* 1996;78:128-32.
  6. Khan A, Thomas N, Costello B, et al. *Eur J Radiol* 2000;35:1-7.
  7. Lijo S, Xiang HE, Michael Pins, et al. Renal Medullary Carcinoma and ABL gene Amplification. *The Journal of Urology* 2005;173:1883-8.
- 

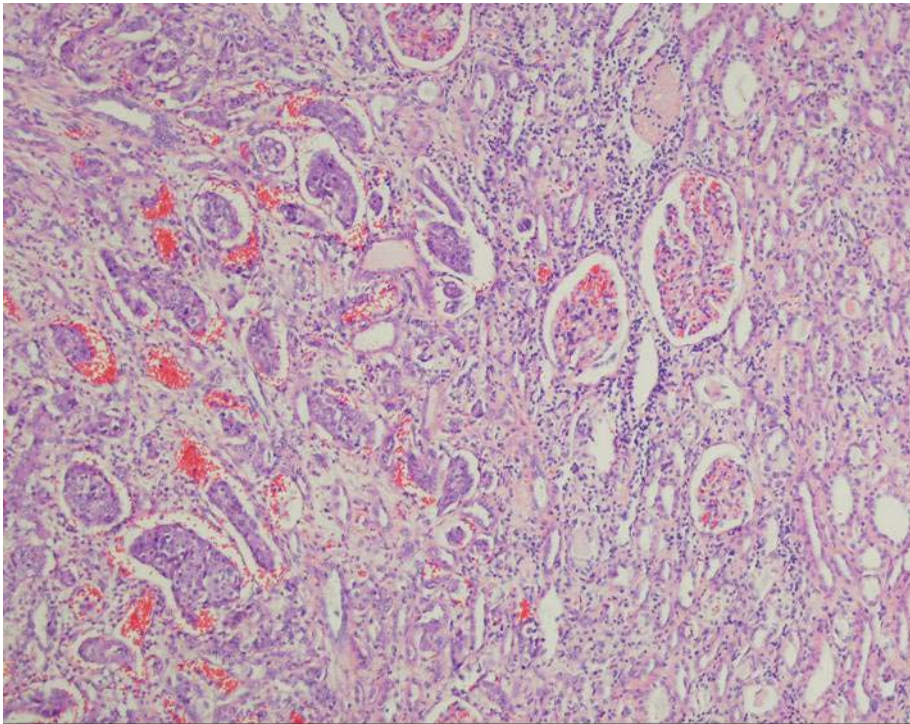


Intravenous pyelogram showing no contrast excretion on the right side, and normal left kidney(Figure 1)

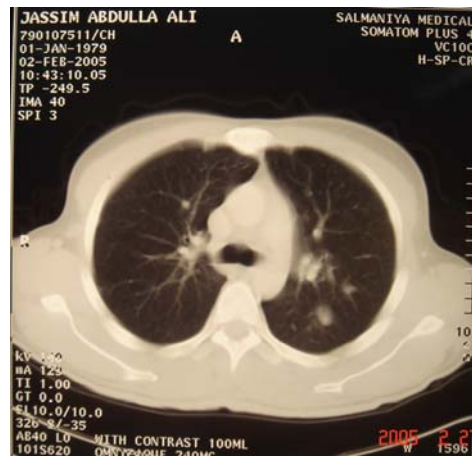
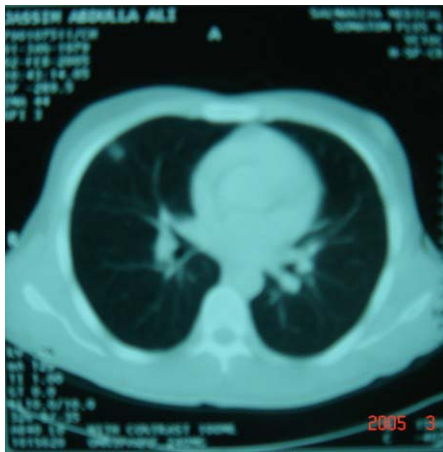


CT abdomen showing mass in the right renal pelvis extending into the proximal 4-5 cm of the

ureter, and enlarged hilar renal lymph nodes (Figure 2)



Tumor presents a reticular or adenoid cystic pattern with regions of poor differentiation in stroma with mucinoid, myxoid, and or oedematous appearance with areas of haemorrhage (figure 3)



CT chest showing bilateral metastasis  
( Figure 4)