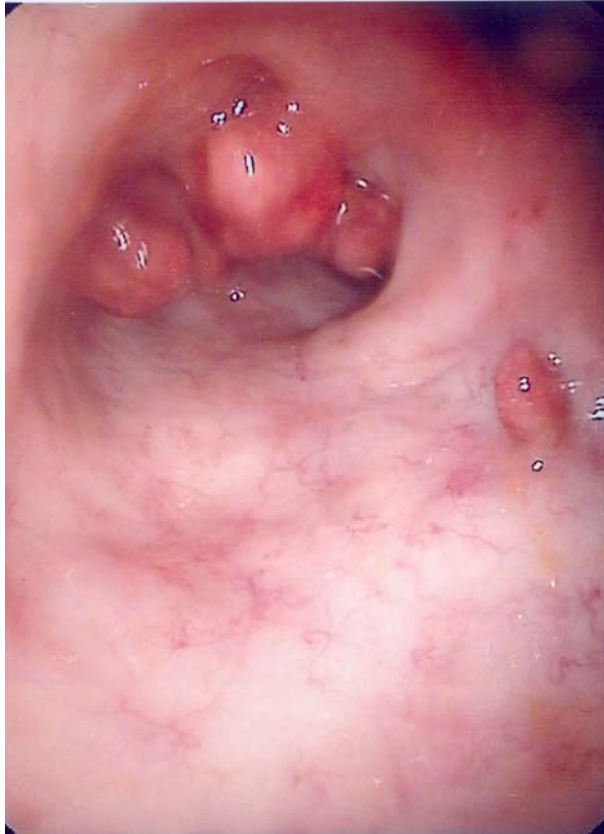

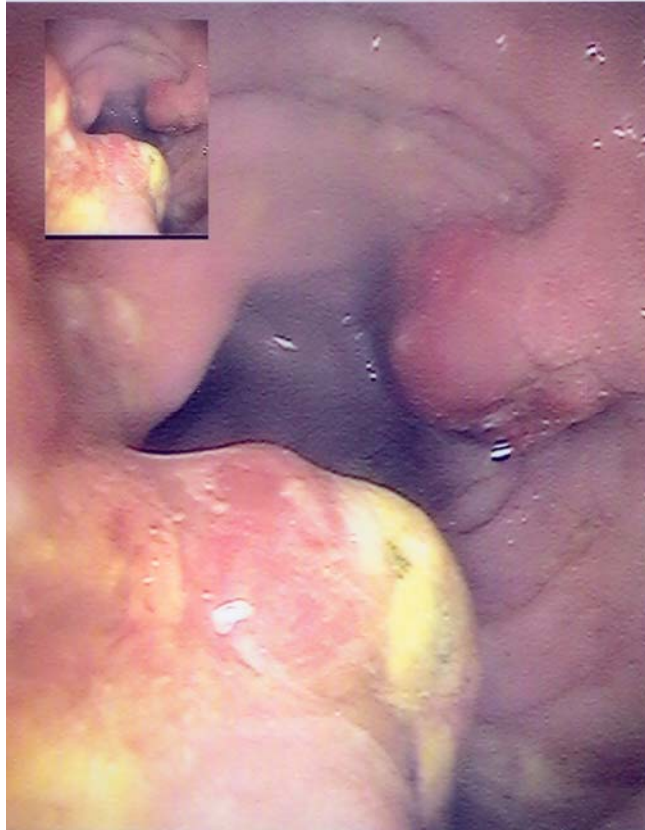
Medical Quiz

Rare cause of Colonic Bleeding

Suhair Al- Saad, MBChB, CABS, FRCSI* Hamdi Al-Shenawi, MBBS, FRCSI**

A thirty-two year male Yemeni patient presented with one year history of intermittent rectal bleeding. There was no anal pain or swelling, and no change in bowel habits. There was no loss of appetite or weight, and no associated abdominal pain. Rectal examination was normal. Colonoscopy showed multiple lesions at the recto-sigmoid junction (Photos). All were removed endoscopically on two occasions.





- Q1. Describe what you see in the image.**
- Q2. What is the differential diagnosis?**
- Q3. What is the likely diagnosis?**