

Medical Quiz

Suhair Khalifa Al Saad, FRCSI, CABS, CST* Basma Al Sayed, MB, ChB**

A fifty-eight years old female diabetic patient underwent radiological investigation for dysfunctional uterine bleeding by the gynecologist; she had strong family history of uterine malignancy. She was referred to general surgery due to the findings seen on the figures 1, 2 and 3.

The patient was asymptomatic. On examination, the patient was generally healthy with normal chest, cardiovascular and abdomen. Laparoscopic resection of the lesion was performed. Postoperatively, she improved and discharged home within 4 days. Figure 4 shows the resected lesion. Please answer the following questions.

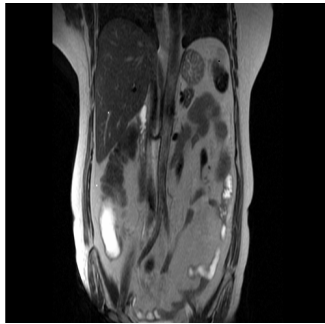


Figure 1

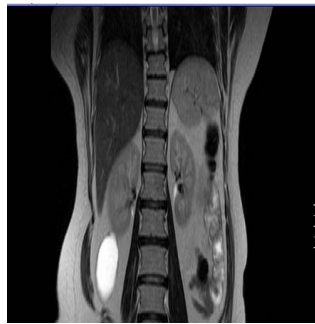


Figure 2

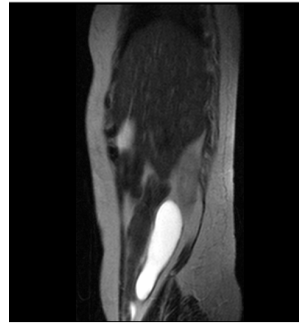


Figure 3

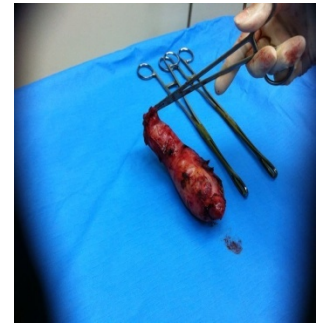

Figure 4

- Q.1. What is the radiological test seen on Figure 1, 2 and 3 and mention 3 findings?
- Q.2. What is the differential diagnosis?
- Q.3. What are the laboratory investigations, which could confirm the diagnosis?
- Q.4. What is the diagnosis?

* Assistant Professor Arabian Gulf University
Consultant Surgeon
** Surgical Resident
Surgery Department
Salmaniya Medical Complex
Kingdom of Bahrain
Email: alsaadsuhair@gmail.com