

Prevalence of Alkaptonuria in South of Jordan

Khalid Al-Ghzawi, MD, JBFM*

Ahmed Telfah, MD, JBIM

Mohammad Tawara, MD

Walid Issa Treef, MD, JBGS

Objectives: The aim of this study is to analyze the incidence of alkaptonuria in south of Jordan and to point out its prevalence among Jordanians at this region

Materials and Methods: This study was based on screening of first and second degree relatives of three already diagnosed patients, and random screening of 300 persons from both sexes with the age group from 6-18 years, living in Al-Taybah 10 kilometers from Petra.

Results: Alkaptonuria was found in 2 cases among relatives of the affected patients. Random screening reveals the presence of 4 cases.

Conclusion: Even though Alkaptonuria is a rare metabolic disorder worldwide, we have a high incidence in south of Jordan, with an unusual association with epilepsy in one patient. Further studies are necessary to point out the incidence of Alkaptonuria in Jordan; and there must be proper methods to control the progression of this disorder .

Bahrain Med Bull 1999;21(2): 47-48

Alkaptonuria is a rare metabolic disorder resulting from loss of homogentisate 1,2 dioxygenase activity, it has a particular place in the history of human genetics as it was the first disease to be interpreted as a mendilian recessive trait by Garrod in 1902 . At least 600 cases had been reported with the prevalence of 3 - 5 per million^{1,3}.

Large quantities of homogenetic acid which is an intermediary product of tyrosine catabolism , accumulate in the affected individuals leading to darkening of urine, deposition in connective tissues causing ochronosis and later on causing debilitating arthritis^{2,3,5}(see pictures taken of our patients at the end of this subject).

METHODS

This study was based on screening of first and second degree relatives of three already diagnosed alkaptonuric patients and random screening of three hundred persons from both sexes with the age group from 6-18 years living in Al-Taybah (in the south of Jordan 10 Km from Petra) , with a population of 4000 Jordanians; screening performed by taking family history, clinical examination and urine samples.

Urine of the involved persons was examined by naked eye appearance after exposure to air and by using Benedict's reagent which makes positive samples brown in color (Fig 1). To avoid false positive results, positive samples were reexamined by using saturated silver nitrate solution which gives brown precipitate.

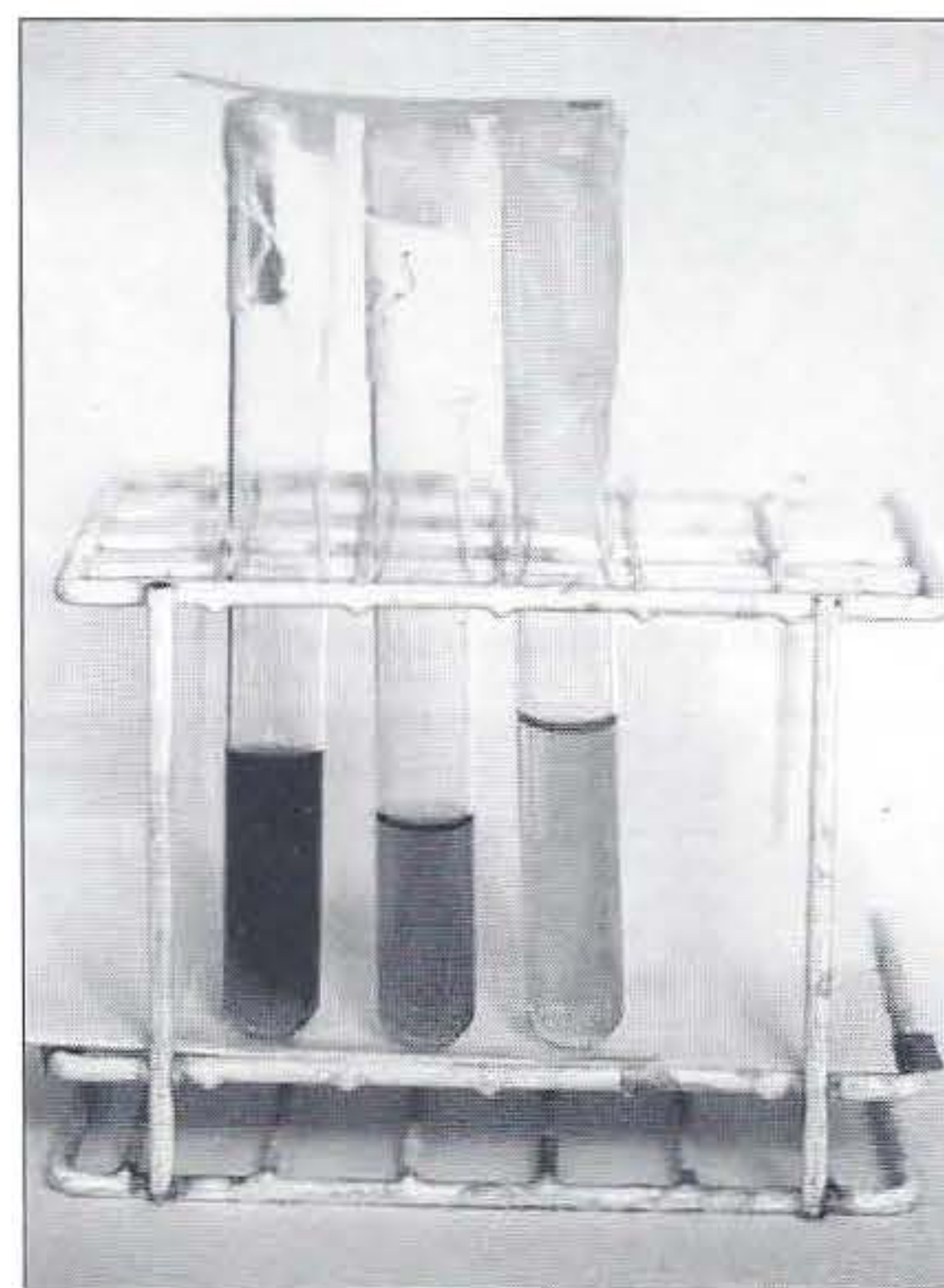


Figure 1 Dark colouration of urine on exposure to air

RESULTS

Nine cases of alkaptonuria were found in this area. Two cases were discovered while analyzing the family tree of the three patients already diagnosed, 4 cases were discovered while performing the random screening. All patients newly diagnosed have no complaints and do not know about their disease .

* P.O. Box 68,
Wadi-Essir 11810,
Jordan

DISCUSSION

Alkaptonuria is a rare metabolic disease, the incidence of the disease is 3-5 per million¹⁻³, but in the study done at Al-Taybah, we found two cases of alkaptonuria after family screening of three patients previously diagnosed to have Alkaptonuria and four cases in the random study -this is a very high incidence if we compare it with international prevalence of alkaptonuria, so we have to find out the causes of this high incidence. This may be as a result of consanguineous marriage, and as a result of inbreeding within isolated hamlets of this region. The classical triad of darkening of urine, ochronosis and arthritis were found in all of the early three diagnosed patients (picture 1, 2 & 3), one of them had epilepsy of two years duration and controlled by antiepileptic drugs, this is unusual to be found in Alkaptonuria^{2,4-6}); the relationship between alkaptonuria and epilepsy is not known. we wonder whether this is accidentally found or it is a new association; further studies must be carried out to see if there is any other similar association - that will enable us to say that epilepsy is a new association of Alkaptonuria.

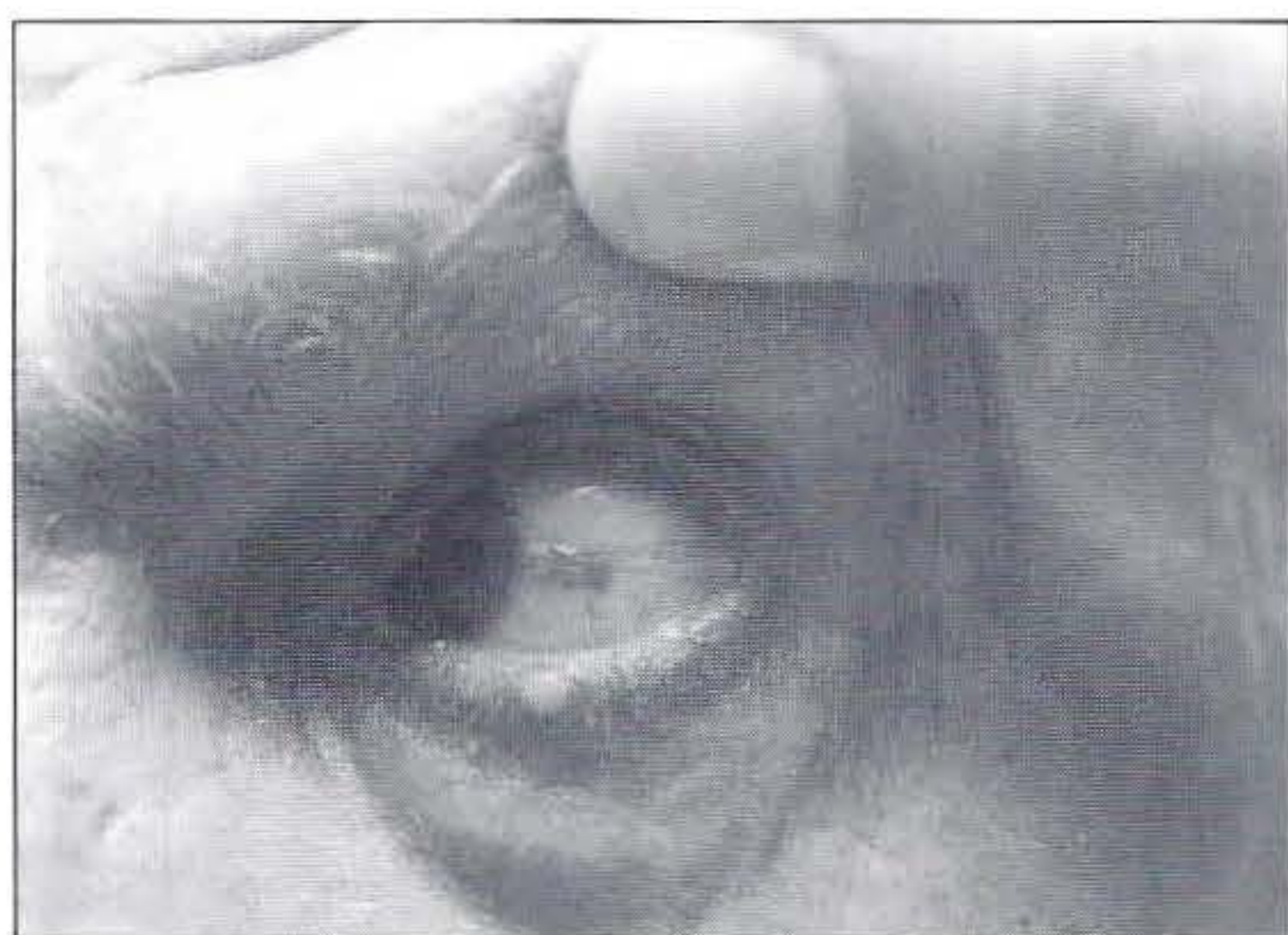

Figure 2a: Pigmentation of sclera and skin surrounding the eye

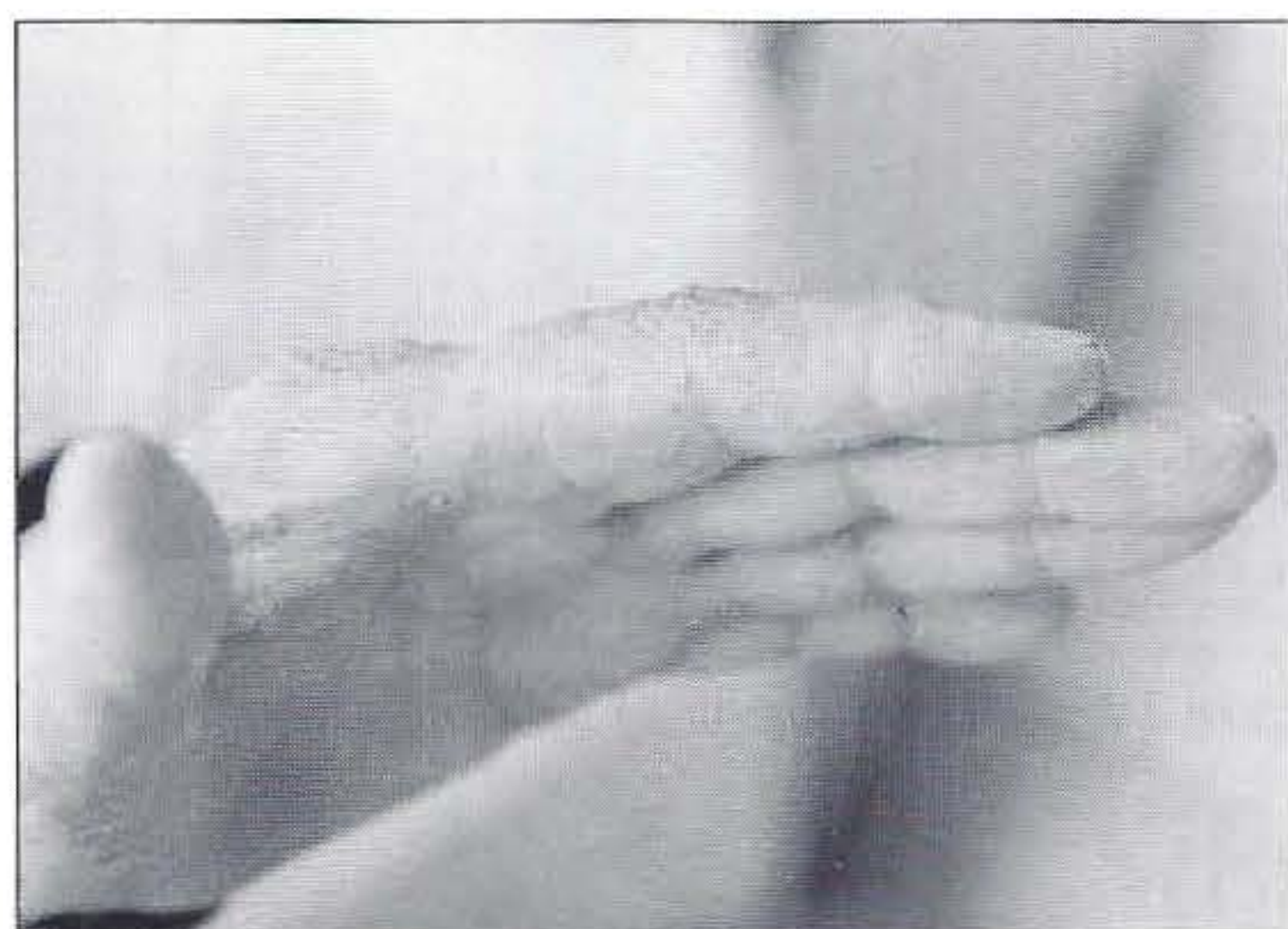

Figure 2b: Pigmentation of the hand

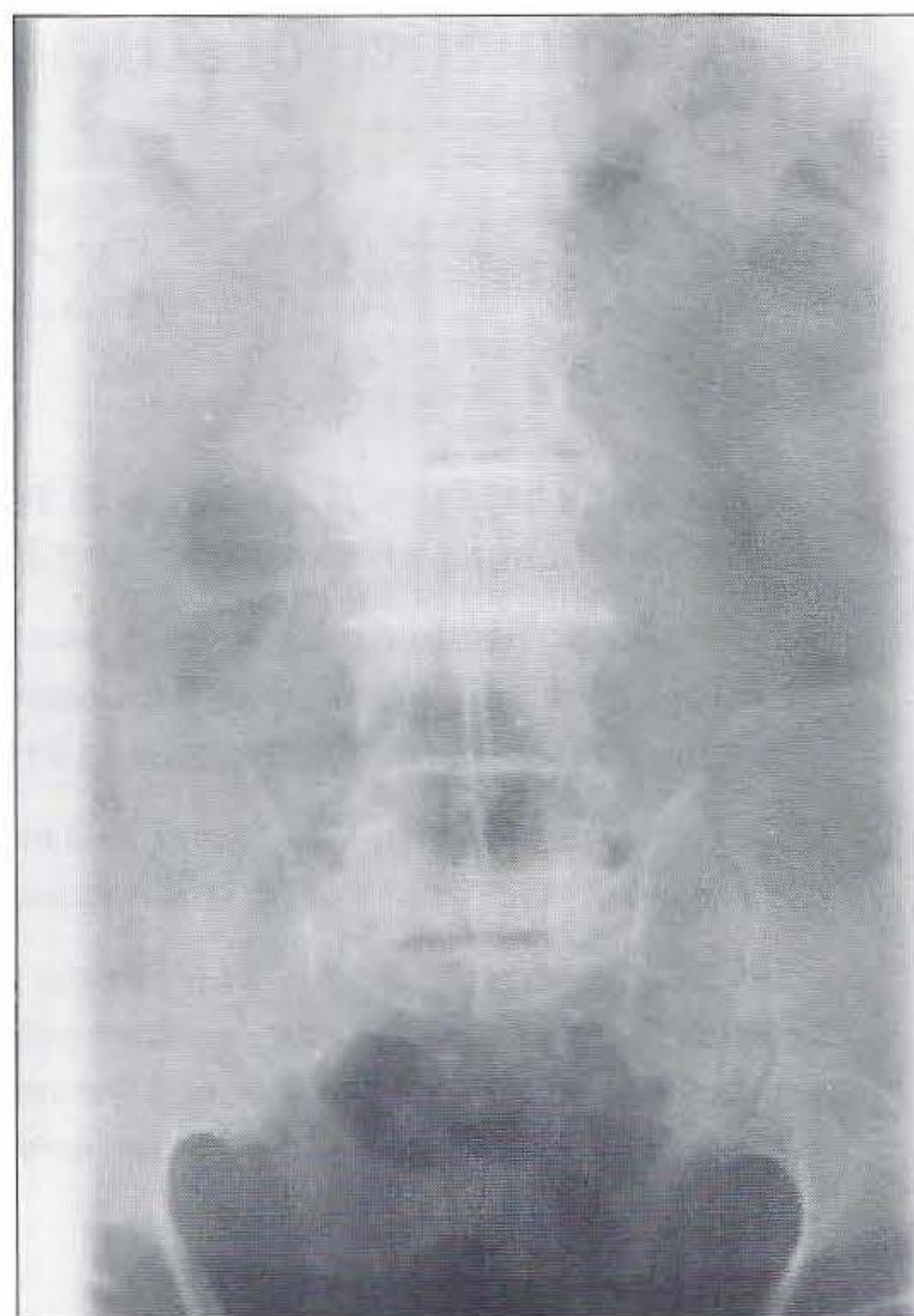

Figure 3: Dense calcification of intervertebral disc spaces

CONCLUSION

Even though alkaptonuria is a rare metabolic disorder worldwide we have a high incidence at the south of Jordan with an unusual association with epilepsy in one patient. Further studies are necessary to point out the incidence of alkaptonuria in Jordan; and there must be a national plan to eradicate the progression of this metabolic disorder.

REFERENCES

1. Fernandez-Ca NJM; Granadino B, et al. The molecular basis of alkaptonuria. *Nat Genet* 1996;1 : 19-24.
2. La Du BN. Alkaptonuria. In: Scriver CR, Beaudet AL, Sly WS, et al. *The metabolic basis of inherited disease*. 6th Edn., New York: McGraw Hill, 1989:775-90.
3. Cecil text book of medicine. 18th Edn. 1988; 1 : 866-70.
4. Gutzmer R, Herbst RA, Kiehl P, et al. Alkaptonuric ochronosis: report of two affected brothers. *JAM Acad Dermatol* 1997; 2 : 305-7.
5. Aquaron R, Fayet G, Barthelet C, et al. Parkinson disease and Alkaptonuria: Fortuitous association or striatonigral ochronosis? France. *Rev Neurol (Paris)* 1995; 151 : 63-6.
6. Gemigani G, Oliveri L, Semerari R, et al. Coexistence of ochronosis and ankylosing spondylitis. *Pasars GJ Rheumatology* 1990; 17:1707-9.