

## **Secondary Aorto-duodenal Fistulas**

Ahmed M. Al Asfoor M.D\* Nair G. R. MS MCh FACS\*\*

**Aorto-enteric fistula is a serious and fatal complication of aortic graft surgery. The difficulty in both diagnosis and management amplify the impact and seriousness of this condition. Reports about the value of the use of endoscopy as a diagnostic tool are increasing in the medical field. Here we present our experience with a case of secondary aorto-duodenal fistula (ADF) followed by discussion of the current scientific opinion about this life threatening condition.**

***Bahrain Med Bull 2007; 29(2):***

Aorto-duodenal fistulas comprise the majority of all aorto-enteric fistulas. They may be primary (occurring after aneurysms of the native aorta) or secondary (occurring as a rare complication of aortic prosthesis surgery)<sup>1</sup>. Secondary aorto-enteric fistulas were first reported by Brock in 1953 and in 1957 Herberer reported the first successful repair. Aortography and other gastrointestinal studies have a high false negative rate<sup>2</sup>. Scattered reports of the value of the use of endoscopy have appeared but it has only been emphasized in two papers in which one had five cases and the other had twenty-two cases<sup>2</sup>.

Early recognition of this condition is essential for successful management of secondary aorto-duodenal fistulas. The treatment of this condition is now standardized. It involves removal of the original graft and the aorta is over sewn and replaced by an axillofemoral Dacron prosthesis<sup>3</sup>.

---

\* Senior Surgical Resident

\*\* Consultant Thoracic and Cardiovascular Surgery  
Salmaniya Medical Centre  
Ministry of Health  
Kingdom of Bahrain

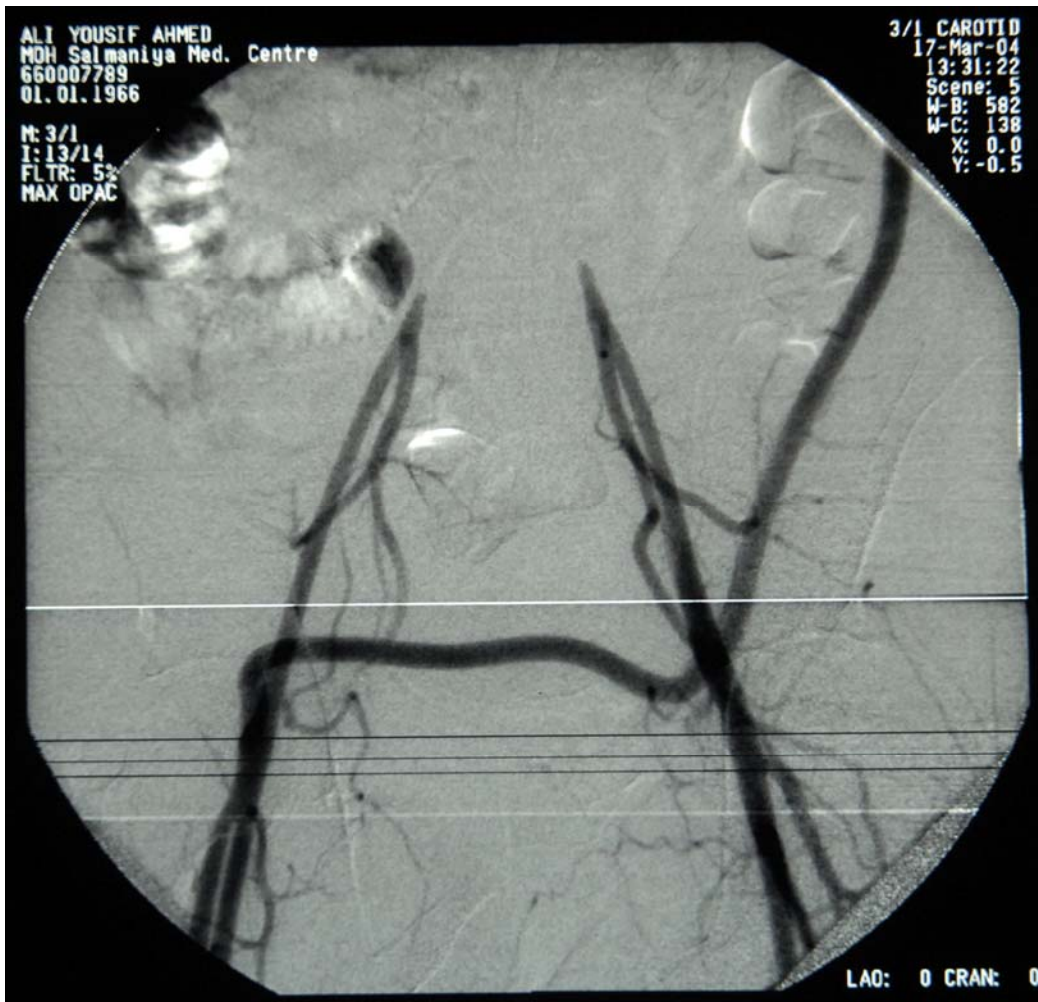
## THE CASE

A thirty-seven year old male presented with acute abdominal pain, upper gastrointestinal bleeding and tarry stool of one day duration. The pain started from peri-umbilical area migrating to epigastrium followed by hematemesis. His past history was positive for antiphospholipid syndrome, deep venous thrombosis and abdominal aortic aneurysm repair since one year. One week after the operative repair for lower gastrointestinal ulceration of the cecum and ascending colon, he had right hemicolectomy.

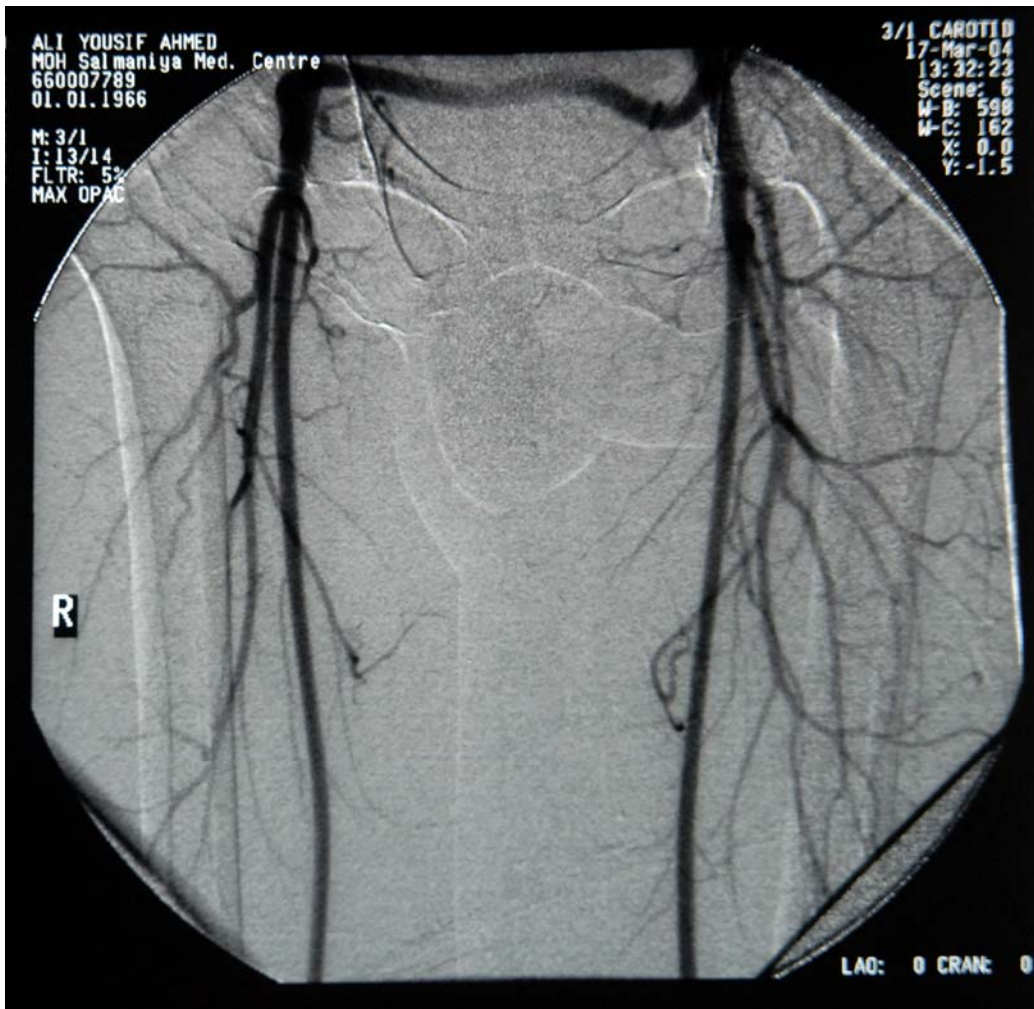
Physical examination revealed pallor, blood pressure of 95/60 mmHg and pulse 125/min. Peripheral pulses showed tachycardia with normal volume and flow. On abdominal examination mild epigastric tenderness was noticed. Stool was positive for blood on per rectum examination.

Hemoglobin level was 9.2 g/dl initially, then it dropped overnight to 7g/dl. His creatinine and urea levels were elevated.

Endoscopic evaluation showed an aorto-duodenal fistula with bulge of aortic graft into third part of duodenum and minimal ooze was noted. An urgent laparotomy was performed, which showed a 5 cm perforation in the third part of the duodenum communicating with the aortic graft, hematoma at the upper end and pus at the lower ends of the graft. Repair of the fistula in the duodenum with explantation of the aortic graft and axillobifemoral bypass was done. **(See figure 1 & 2)**



**Fig 1: Angiogram showing the axillo-bifemoral bypass with good blood flow to both lower limbs**



**Fig 2: Angiogram showing the bifemoral bypass with good blood flow to lower limb.**

The patient was admitted to ICU postoperatively and treated by antibiotics for one week. He had an uneventful recovery course. He was discharged on the 20<sup>th</sup> postoperative day and continued on Warfarin. The patient was reviewed as an outpatient at 3, 6 months, and he remains well.

## **DISCUSSION**

Secondary aorto-duodenal fistulas (ADF) are the most common variety of aorto-enteric fistula. It was first reported in 1953 after the introduction of aortic reconstructive surgery. The incidence of primary ADF is low with less than 200 patients reported in the literature.

Secondary aorto-enteric fistulization in patients with aortic graft is not a rare event as confirmed by a study of 1376 cases over 11 years, the incidence was 1.6%. Other studies showed comparable incidence of 0.6% to 4%<sup>4</sup>. The fistula occurs mostly at the

upper aorto-prosthetic anastomosis and communicates with the third part of the duodenum. Other organs involved are stomach, jejunum, or colon.

This condition has two theories for its pathogenesis. The first proposes that the fistula is the result of repeated mechanical trauma from arterial pulsations. The second, and the more probable, proposes low grade infection as the primary event with abscess formation and subsequent erosion through the bowel<sup>5</sup>. Interestingly, the majority of grafts show signs of infection at the time of bleeding and up to 85% of cases blood cultures may be positive for enteric organisms<sup>6</sup>.

Bleeding from ADF can occur at anytime postoperatively. Reports, as long as, 14 years postoperatively are documented. Mean interval was shown to be 15 months in one study and 36 months in another.

Bleeding may stop spontaneously. It may recur intermittently, usually in the form of melena, "the herald bleeding", which is brisk bleeding associated with hypotension and hematemesis which stops spontaneously. It may bleed further after hours or days which occur in 22% of patients.

The duration of bleeding is variable with a mean of 25 days. However, delay in diagnosis and interventions are common.

Every patient with gastrointestinal bleed and past history of aortic graft surgery must be considered to have ADF until proven otherwise. An upper gastrointestinal endoscopy is mandatory. The endoscope must be inserted to its limit to avoid missing any part of duodenum.

There is no conclusive evidence that shows significant differences in technical merits of medium caliber compared to thin caliber endoscope in these cases. In the medium caliber endoscope there is a possibility of dislodging the clot on the graft material.

While barium meal has been useful in diagnosis of secondary ADF, the positive yield is low<sup>7</sup>. Laparotomy has been useful when other tests fail to discern the etiology of bleeding, angiography and endoscopy yield a diagnosis only in 30% of cases<sup>1</sup>.

The overall survival of patients with ADF varies from 30% to 70% according to the surgery performed. Local repair or graft replacement has low survival rate (20%) because of either bleeding postoperatively or reinfection of the graft with refistulization<sup>2</sup>. The treatment of choice with best results is graft resection and establishment of an extra-anastomotic circulation, preferably by single axillofemoral bypass, this is the procedure, which was done for our patient.

A high index of suspicion and aggressive team approach to diagnosis and management of this condition is recommended. We believe that gastrointestinal bleeding in a patient with an aortic Dacron graft is an indication for immediate gastrointestinal endoscopy. The endoscopist should not be reassured by finding an alternative bleeding or non-bleeding lesion and must attempt to examine as much of the upper tract as possible. If massive bleeding precludes the endoscopic evaluation, emergency aortography should be performed. As infection is frequent we believe that

the original graft should be removed and the aorta over sewn and replaced by an axillofemoral Dacron prosthesis.

## CONCLUSION

**Mortality related to secondary aorto-duodenal fistulas is high and must be suspected whenever a patient with aortic prosthesis has digestive tract bleeding. Endoscopic evaluation of an episode of bleeding is one of the most helpful and efficient ways to diagnose this rare clinical entity and guide to a successful management. Removal of the graft and replacement with axillofemoral Dacron prosthesis is the optimal way of management of these patients.**

## REFERENCES

1. Capaldo GR, Amin M. Aortoduodenal fistula; case report and review of literature. *JR Cardiovasc Surg* 1996; 37:567-70.
2. Champion MC, Sullivan SN, Coles JC, et al. Aortoenteric fistula: Incidence, Presentation recognition, and management. *Ann. Surg* 1982; 195:314-78.
3. Sultan S., Madhavan P. Aortoduodenal and aortocaval fistulas with accessory left renal artery aneurysm presenting with heart failure and chronic anemia due to hematemesis: Case report. *Vascular Surgery* 1999; 33:291-4.
4. Elliot JP, Smith RF, Sizlagyi DE. Aorto-enteric and paraprosthetic-enteric fistula. Problems of diagnosis and management. *Arch Surg* 1974; 108:479.
5. Bussetil RW, Reese W, Baker JD, et al. Pathogenesis of aortoduodenal fistula, experimental and clinical correlates. *Surgery* 1979; 85:1-12.
6. Rosenthal D, Deterling Jr RA, O'Donnel Jr TF, et al. Positive blood culture as an aid in the diagnosis of secondary Aortoenteric fistula. *Arch Surg* 1979; 114:1041-4.
7. Frizelle FA, Hung HA, Heslop JH et al. Obscure gastrointestinal bleeding: idiopathic aortoduodenal fistula. *JR Cill Surg Edinb* 1991; 36:331-3.