

## **Amniotic Bands: Are They All Threat for the Fetus?**

Naeema Ahmmed A Mahmood MBBS, Arab Board\*

**Background:** Amniotic band syndrome (ABS) or amniotic band disruption is a common cause of sporadic miscellaneous fetal malformation involving limbs, trunk and the craniofacial region. Diagnosis is mainly suspected by ultrasound imaging, where the fetus is seen attached to the amniotic bands. Clinical manifestation is variable from minor constriction rings to fetal or neonatal demise secondary to severance of the umbilical cord or the associated malformation. Therefore, management options vary depending on the associated anomalies.

**Objective:** The aim of this report is to highlight this condition, emphasize that subsets of amniotic bands exist which do not pose a threat to the fetus.

**Design:** Prospective study.

**Setting:** Ultrasound unit in the Department of Obstetrics and Gynaecology, Salmaniya Medical Complex, Kingdom of Bahrain.

**Method:** Patients with suspected diagnosis of amniotic bands by ultrasound scanning during the study period (January 2005 to December 2007) were followed up till delivery to confirm the diagnosis. Patients Characteristic, clinical presentation, gestational age at the time of presentation, ultrasound images and outcome were reviewed.

**Result:** Three patients were encountered during the study period. The first patient was twenty years old primigravida, while the other two were middle age multiparous ladies. The clinical presentations were variable, however, they all presented with hydramnios. Two cases had typical severe malformations with fetal demise in the neonatal period. The third presented with only amniotic bands demonstrated in the scan but no fetal attachment, which had good outcome.

**Conclusion:** Amniotic band syndrome is a common cause of sporadic and bizarre form of fetal malformation. An isolated finding exists where the amniotic band floats freely in the amniotic fluid and do not attach to the fetal parts. These pose no threat for the fetus. We are reporting three cases of Amniotic bands. The first two cases were the typical presentation of Amniotic band syndrome; whereas the third case highlights the possibility that a subset of amniotic sheets exist that do not disturb the fetus.

*Bahrain Med Bull 2008; 30(2):*

---

\* Consultant Obstetrician & Gynaecologist  
Department of Gynaecology  
Salmaniya Medical Complex  
Kingdom of Bahrain

Amniotic bands syndrome (ABS) is a set of congenital malformations ranging from minor constriction rings and lymphoedema of the digits to complex, bizarre multiple congenital anomalies that are attributed to amniotic bands that stick, entangle and disrupt fetal parts. It occurs in 1:1200 to 1:15000 live births<sup>1,2,3,8</sup>. The exact aetiology of the syndrome is not known; early rupture of the amniotic membrane is the most accepted view<sup>1,2</sup>. However, genetic, vascular, familiar, and mesodermis disruptions have been proposed as etiological factors<sup>4</sup>. Teratogenic drugs such as methadone may play a role<sup>5</sup>.

Amniotic bands syndrome has been reported widely in the literature with at least eleven different names<sup>6</sup>. The investigators reported amputation of digit(s) or limbs in associations with multiple fetal malformations.

We are reporting three cases of amniotic bands; two with multiple malformation "Amniotic bands syndrome", while the other one having normal fetus "Amniotic bands".

We aim to highlight this prenatally detectable malformation, demonstrate that amniotic bands could be an isolated finding found in normal pregnancy and do not pose a threat to the fetus.

## **METHOD**

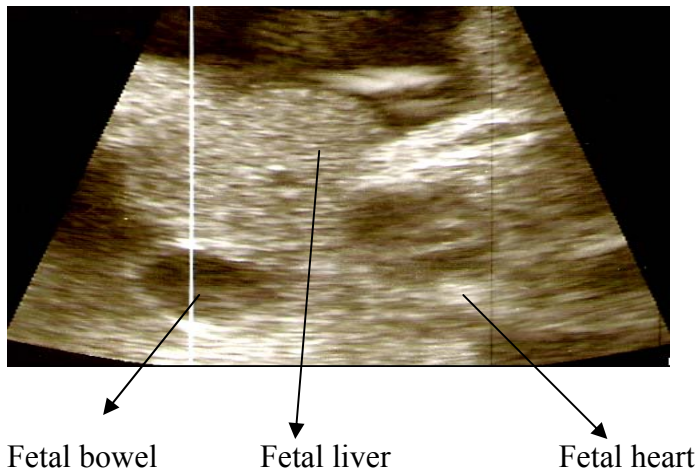
Patients with suspected diagnosis of amniotic bands by ultrasound scanning during the study period (January 2005 to December 2007) were followed up till delivery to confirm the diagnosis. Patients Characteristic, clinical presentation, gestational age at the time of presentation, ultrasound images and outcome were reviewed.

## **RESULT**

Three patients were encountered during the study period. The first patient was twenty years old primigravida, while the other two were middle age multiparous ladies. The clinical presentations were variable, however, they all presented with hydramnios. Two cases had typical severe malformations with fetal demise in the neonatal period. The third presented with only amniotic bands demonstrated in the scan but no fetal attachment, which had good outcome.

### **Case One**

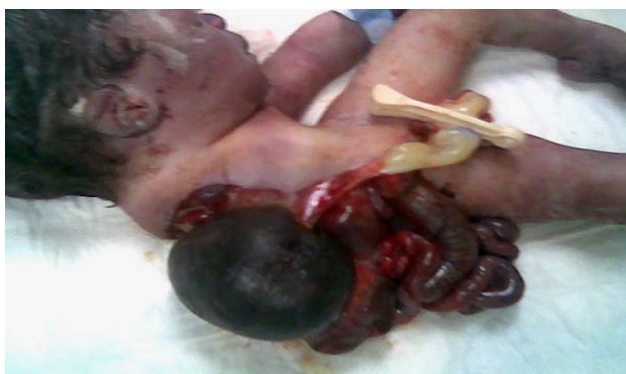A twenty-one years old primigravida at 32 weeks gestation was admitted with history of abdominal pain and per vaginal spotting. Ultrasound examination showed a single, cephalic live fetus with hydramnios. The biometry was consistent with a gestational age of 32 weeks. Large chest and abdominal wall defects were noted with the heart, liver and multiple loops of bowel floating freely in the amniotic fluid (figure 1). The fetus was noticed to have restricted movement and seemed stuck to an amniotic band. Due to restricted fetal movement, the limbs could not be clearly visualized. These associated abnormalities strongly raised the suspicion of amniotic band syndrome.



**Figure 1: Tranabdominal Ultrasound Showing Fetal Liver, Heart and Bowel Protruding through the Defect**

The mother was counselled regarding the lethal nature of these combined anomalies. However, due to religious reasons and local law, feticide and or termination of pregnancy could not be offered. Hence, the patient was discharged home in the same day to be followed in the clinic.

Six days later, at 33 weeks gestation, she presented with uterine contraction and liquor drainage. She progressed in labour and had a spontaneous vaginal delivery of a male baby weighing one kilogram and 280 grams. The neonate was born flat with slow and irregular heart beats. The antenatally diagnosed abnormalities were confirmed postnatally. In addition, the right arm was amputated from the shoulder (Figure 2). The infant expired 17 minutes post-delivery.



**Figure 2: The Baby after Delivery. Note the Amputated Right Arm, the Heart, Liver and Loops of Bowel Protruding through the Defect**

### Case Two

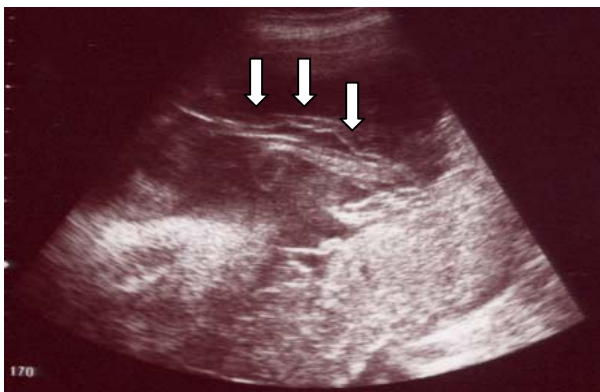A thirty-eight years old lady, gravida 6, Para 5 presented with mild per vaginal bleeding at 24 weeks gestation. Ultrasound revealed single alive fetus, with large right side abdominal wall

defect. The liver, stomach, kidney and multiple loops of bowel were floating freely in the amniotic fluid. The spine was interrupted at the site of the defect. The fetus was stuck by amniotic bands. The placenta was anterior and was covering the cervical os. The guarded fetal outcome was explained for the parent. Due to placenta praevia, the patient was kept under observation. Few days later, when bleeding subsided, she was discharged home.

She was readmitted twice for the same complains at 28 and 30 weeks gestation. Repeated scanning showed central placenta praevia with same fetal findings. Therefore, we decided to terminate the pregnancy at 31 weeks through lower segment caesarean section for maternal sake. The male fetus, weighing one kilogram and seven hundreds grams was born flat and soon expired. The mother had profuse bleeding from placental site; these were sutured and bleeding was controlled. Total blood loss was almost two litres. She received two units of packed red blood cells. She had uneventful postoperative recovery and was discharged home at the sixth postoperative day.

### Case Three

A forty years old lady, gravida 7, Para 4. Her obstetrics history was uneventful except for previous two miscarriages in the immediate proceeding pregnancy for which she underwent uterine evacuation. She was referred for ultrasound examination at 35 weeks gestations for fetal presentation. Her previous dating and anomaly scans were normal. On scanning, fetal biometry were corresponding to date, however, amniotic band were noted floating freely adjacent to the fetal head and lower limbs (Figure 3). The fetus was seen separate from the membranes. Careful fetal assessment was done and no abnormalities were detected. The mother was counselled regarding the possibilities of the fetus attaching itself to the band with the risk of developing amputation defects. Follow up scan was arranged one week later, which was reassuring. The lady had spontaneous delivery at 37 weeks gestation, a male fetus was born weighing 2890 grams. Physical examination was normal.



**Figure 3: The Amniotic Bands or Sheets Floating Freely in the Amniotic Cavity (arrows)**

### DISCUSSION

"In 1937, I observed an amazing sac. While viewing the interior of the distended fetal sac it was seen that the amnion was in the form of an open, globular pocket surrounding the placental attachment of the umbilical cord. The amnion had obviously been ruptured at about

midterm pregnancy. There was no damage to the chorionic sac, in which the fetus had continued to live. There were multiple fibrous strands issuing from the surface of the amnion sac as well as from the amnion-denuded chorion which had contained the fetus. Subsequently, a somewhat similar situation was observed in another distended fetal sac. Could these strands injure the fetus? In both of these instances, the respective fetus was found to have sustained malformations postulated by the condition of the fetal membranes" Richard Torpin, 1968<sup>7</sup>.

These are the words of Richard Torpin who was the first describe to one of the most striking fetal malformations, amniotic band syndrome.

The amniotic band syndrome or amniotic band disruption is sporadic congenital anomalies characterized by amputations, constriction bands and multiple craniofacial, visceral and body wall defects. It occurs in 1:1200 to 1:15000 live births<sup>1,2,3,8</sup>. Although the exact cause of the syndrome is not known, early rupture of the amniotic membrane- as suggested by Torpin- is the most accepted view<sup>1,2</sup>.

However, this theory does not explain fully the associated severe fetal anomalies. Instead, genetic, vascular, familiar, and mesodermic disruptions have been proposed as etiological factors<sup>4</sup>. Furthermore, teratogenic drugs such as methadone may play a role<sup>5</sup>.

The syndrome results in structural anomalies that vary from minor, such as, constriction rings around the digits to lethal forms as presented in our two cases.

Ultrasound has a pivotal role in diagnosing and documenting these fetal anomalies. The associated anomalies described in the first case should be regarded as strong evidence and raise the suspicion of amniotic bands syndrome. Furthermore, the visualization of amniotic bands attached to the fetus with restriction of motion, as in our second case, is diagnostic of the condition<sup>7</sup>. On the other hand, visualization of amniotic bands or sheets should dictate a careful survey of all fetal organs. If attachment of the amnion to the fetus is observed, a follow up scan is indicated to rule out future anomalies. However, if the fetus is normal and no attachment is seen, as in our third case, the mother could be reassured that the amniotic bands or folds are an isolated finding and do not pose threat to the fetus<sup>6</sup>. These folds may be seen in normal pregnancies as membranes floating freely in the amniotic fluid. They have been reported in patients who had instrumentation of the uterine cavity resulting in intrauterine scars or adhesions<sup>7</sup>. The band has a free edge and does not attach to the fetus, so the baby can move independently of the membrane, which is the distinctive feature. In some cases, the diagnosis is further confirmed at autopsy by the demonstration of chronic rupture of the chorion in histological sections of the placenta<sup>8</sup>.

The prognosis of these cases is much dependent on the associated anomalies. It can be quite good for infants with only minor constriction rings and lymphoedema of the digits with normal life expectancy. Children with amputations of the limbs may require reconstructive or plastic surgery. In contrast, the syndrome could be lethal if the associated anomalies are severe as in the first two cases.

The prenatal management of amniotic band syndrome will depend largely on the type and extent of malformations. Minor and isolated constriction rings are less likely to be diagnosed prenatally. However, if it is diagnosed, endoscopic release of these bands is indicated<sup>3</sup>. If left untreated, these constrictions rings could leads to amputation of the organ (s) involved; this

has been documented by serial ultrasonography<sup>1</sup>. Nevertheless, a case with spontaneous resolution has been reported<sup>2</sup>. For the severe forms, the option for terminating of the pregnancy could be offered. We did not feel that option was suitable for our first patient as termination of pregnancy is illegal in this country. In addition, in our experience, it is hard for parents to accept termination of pregnancy for religious reasons. Furthermore, since the diagnosed fetal abnormalities would be incompatible with life, we adapted the conservative plan. Nevertheless, we intervened when we felt that maternal condition could be compromised from repeated episodes of bleeding as in the second case.

It is worth noting that ABS is sporadic, with no recurrence in siblings or children even if one parent was affected. However, there are some reports of amniotic band syndrome among families with collagen disorders, such as Ehler-Danlos syndrome<sup>3,7</sup>.

## CONCLUSION

**Amniotic band syndrome is a common cause of sporadic and bizarre form of fetal malformation. An isolated finding exists where amniotic bands are detected by ultrasonography in which they do not attach to the fetal parts and these float freely in the amniotic fluid. These pose no threat for the fetus. We are reporting three cases of Amniotic band. The first two cases had the typical presentation of Amniotic band syndrome, whereas the third case highlights the possibilities that subset of amniotic bands or sheet exist that does not disturb the fetus. In this subset, if fetal attachments to these bands could not been seen by serial ultrasonography, and no fetal abnormalities could be demonstrated, then the parent need to be reassured regarding the safety of their fetus and these bands represent isolated normal findings.**

## REFERENCES

1. Tadmar PO, Kreisberg GA, Achiron R, et al. Limb Amputation in Amniotic Band Syndrome: Serial Ultrasonographic and Doppler Observation. *Ultrasound Obstet Gynecol* 1997; 10:312-5.
2. Pedersen TK, Thomsen SG. Spontaneous Resolution of Amniotic Bands. *Ultrasound Obstet Gynecol* 2001; 18:673-4.
3. Quintero RA, Morales WJ, Phillips J, et al. In Utero Lysis of Amniotic Bands. *Ultrasound Obstet. Gynecol* 1997; 10:316-20.
4. Evans MI. Opinion. Amniotic Bands. *Ultrasound Obstet Gynecol* 1997; 10:307-8.
5. Philippe J, Sandra RS. Amniotic Band Syndrome. <http://www.thefetus.net/> 1999; 05. 16-01. Accessed on 4.12.07.
6. Bronshtein M, Zimmer EZ, Opinion. Do Amniotic Bands Amputate Fetal Organs? *Ultrasound Obstet Gynecol* 1997; 10:309-11.
7. Torpin R, Knoblich RR. Fetal Malformations of Amniogenic Origin. *J Med Assoc Ga* 1969; 58(3):126-7.
8. Schwarzler P, Moscoso G, Senat MV, et al. The Cobweb Syndrome: First Trimester Sonographic Diagnosis of Multiple Amniotic Bands Confirmed by Fetoscopy and Pathological Examination. *Human reproduction* 1998; 13:2966-9.

