

**EDUCATION-FAMILY PHYSICIAN CORNER**

**Eosinophilic Cellulitis (Wells Syndrome)**

Sara Almutlaga, Saudi Board, Arab Board of Medical Specialization in Dermatology\*

**Eosinophilic Cellulitis (Wells Syndrome) is an uncommon inflammatory disease with clinical polymorphism. A thirty-five-year-old female presented with 2 weeks history of gradually progressive and painful erythematous plaque on the right foot. She had already received several types of antibiotic for the cellulitis without improvement. A diagnosis of Wells syndrome was established. Significant improvement was noted after one month of treatment with prednisolone. Awareness of this condition is necessary for early identification and management.**

*Bahrain Med Bull 2016; 38 (2): 102 - 104*

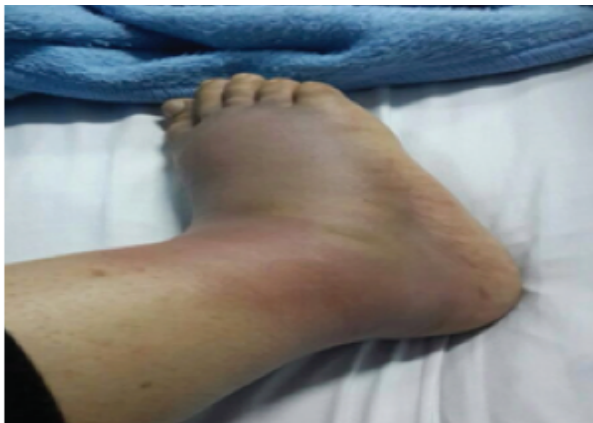Wells Syndrome is a rare inflammatory disorder, characterized by the accumulation of eosinophils in the skin. It is a skin disorder with unknown etiology characterized by recurrent pruritic or tender skin lesions resembling cellulitis; cases often resolve spontaneously, although recurrences are common over several years.

Clinically, it has wide and variable presentations; however, painful erythematous plaque is a common presentation. It is often misdiagnosed as cellulitis due to the similarity in their presentation. Although the incidence and the number of the reported cases in the literature are increasing, still the exact etiology of the disease remain unknown and further studies are required to explore the pathogenesis. Several triggers have been proposed as potential contributors to the development of the disease. Misdiagnosis leads to a delay of proper management and inappropriate use of antibiotics.

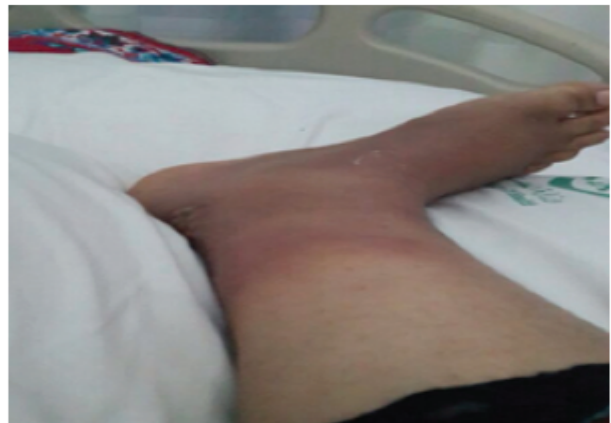The aim of this report is to present a case of eosinophilic cellulitis (Wells Syndrome), an uncommon inflammatory disease with clinical polymorphism.

**THE CASE**

A healthy thirty-five-year-old Saudi female presented with a sudden unilateral right foot pain and swelling for almost two weeks, see figures 1 A and B.



**Figure 1 A: Swelling over the Right Foot**

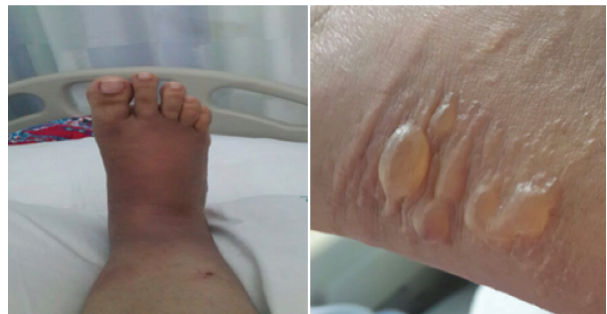

**Figure 1 B: Ill-defined Erythematous Plaque**

The patient gave a history of receiving several antibiotic treatments for cellulitis without substantial improvement. On examination, she showed fluid-filled lesions on the back of her affected foot. These lesions were pruritic and mildly tender.

There was no relevant previous personal or family history, and no preceding history of arthropod bites, vaccination or trauma. She was otherwise healthy, with unremarkable medical history and not taking any medications.

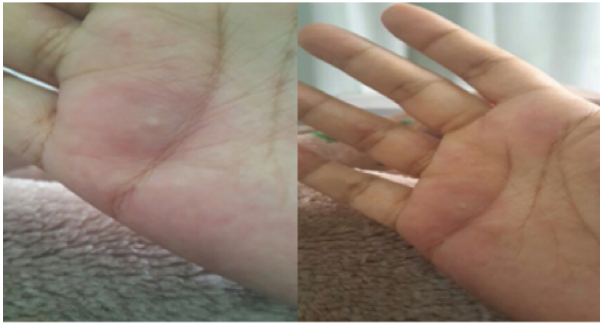On the right foot, there were ill-defined erythematous plaques, swelling associated with tense bullae on the back of her foot, see figure 2.



**Figure 2: Tense Bullae over the Erythematous Plaque**

\* Senior Registrar  
Department of Dermatology  
Najran University Hospital  
Kingdom of Saudi Arabia  
Email: dr.s\_almutlaga@hotmail.com

Scattered erythematous, slightly infiltrated edematous papules over the right thigh and both palms were seen, see figure 3.

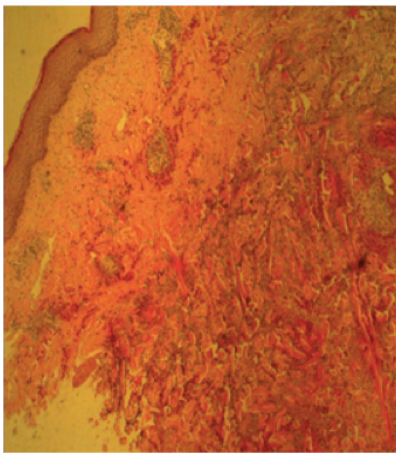


**Figure 3: Multiple Infiltrated Papules over the Palms**

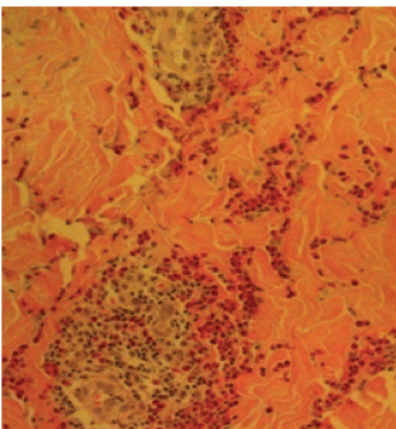
No lymphadenopathy or hepatosplenomegaly nails and mucous membranes were spared. The patient was admitted with presumed cellulitis; to rule out sweet syndrome, atypical erythema nodosum, a skin biopsy was obtained from both lesions.

Histopathology demonstrated marked collagen degeneration with infiltration by a large number of eosinophils with flame figures.

The infiltrate encroaches on the vascular walls which showed endothelial swelling, the papillary dermis showed edema and the overlying epidermis showed acanthosis, see figures 4 A and B.



**Figure 4 A: Collagen Degeneration with Eosinophils**



**Figure 4 B: Several Flame Figures**

Based on the results, the patient was diagnosed with Wells Syndrome. She was started on prednisolone oral 40 mg once daily. Cardiology, rheumatology, general medicine and neurology were consulted to rule out systemic involvement. Laboratory examination revealed leukocytosis (WBC 14.5; normal 4-10), with differential count showing prominent eosinophilia (24; normal 1-6).

Increased erythrocyte sedimentation rate (40mm/h; normal 1-20), liver function, renal function and blood sugar were normal. Virus serology for hepatitis B, C, human immunodeficiency was negative. ANCA profile and complement were within normal range.

Microbial cultures including stool and urine analysis were negative. ECG, echocardiogram and chest X-ray were normal.

A remission of the eruptions and itchiness were achieved within four days. Eosinophil count of peripheral blood recovered to normal value. The corticosteroid was gradually tapered.

## DISCUSSION

In 1971, Wells Syndrome was described by George Wells as a recurrent granulomatous dermatitis with eosinophilia. Seven years later, it was renamed as eosinophilic cellulitis<sup>1,2</sup>.

Wells Syndrome (eosinophilic cellulitis) is a poly etiologic disease with unknown pathogenesis. It is a rare inflammatory dermatosis with unspecific histopathological or clinical findings<sup>3</sup>.

Factors contributing to the development of this disorder include hypersensitivity reactions and cytokine dysregulation due to different triggering factors. New theories have shown that interleukin-5 plays a major role in the pathophysiology. It works by releasing the eosinophils and promoting their degranulation which causes their accumulation in the skin<sup>4-5</sup>.

The majority of the cases are idiopathic in nature; however, infections, arthropod bites, hematologic disorders and malignancies are proposed causes. Exposure to certain medications and several other factors, such as vaccinations were also implicated. Familial cases have been reported<sup>6-9</sup>.

Clinically, the cutaneous eruptions are not specific and vary widely. Pruritic or painful erythematous urticarial plaques are among the most common presentations. Occasionally bullous, granulomatous papular and nodular eruptions may be seen. Lower limbs are frequently involved and typically present with cellulitis-like eruptions<sup>10-11</sup>.

Wells Syndrome is usually benign in nature; it is often resolved spontaneously though recurrence is commonly reported. Arthralgia, malaise, fever, headache and myalgia are additional symptoms that frequently present<sup>12</sup>. Histopathological features depend on the time and the age of the patient when the lesions appeared. In the early acute stage, there would be dense eosinophilic infiltration forming characteristic flame figures with dermal edema. Older chronic lesions may exhibit small numbers of eosinophils with giant cells and histiocytes<sup>13</sup>.

Therapy with systemic corticosteroids considered the first line of treatment; mild cases may respond to topical steroid therapy only<sup>14</sup>. Other possible treatments include dapsone, systemic antihistamines, antimicrobial agents, colchicines, interferon- $\alpha$ , antimalarial drugs or immunosuppressive agents. New therapeutic options may be tyrosine kinase inhibitors, such as imatinib and anti-tumor necrosis factor alpha like adalimumab<sup>1,15-19</sup>.

Wells Syndrome usually has an excellent prognosis. Most cases resolve within weeks to months and the lesions tend to heal without scarring. Recurrence is also commonly reported<sup>14-19</sup>.

## CONCLUSION

**Wells Syndrome is a rare clinical entity, with unspecific presentation which could mimic a variety of diseases, especially cellulitis. If cellulitis is not responding to antibiotic treatment, Wells Syndrome should be suspected.**

---

**Potential Conflicts of Interest:** None

**Competing Interest:** None.      **Sponsorship:** None

**Submission Date:** 18 March 2015.

**Acceptance Date:** 3 April 2016

**Ethical Approval:** Approved by Department of Dermatology, Najran University Hospital, Kingdom of Saudi Arabia.

## REFERENCES

1. Wells GC. Recurrent Granulomatous Dermatitis with Eosinophilia. *Trans St John's Hosp Dermatol Soc* 1971; 57(1):46-56.
2. Wells GC, Smith NP. Eosinophilic Cellulitis. *Br J Dermatol* 1979; 100(1):101-9.
3. Renner R, Kauer F, Treudler R, et al. Eosinophilic Cellulitis (Wells' Syndrome) in Association with Angioimmunoblastic Lymphadenopathy. *Acta Derm Venereol* 2007; 87(6):525-8.
4. Mould AW, Matthaie KI, Young IG, et al. Relationship Between Interleukin-5 and Eotaxin in Regulating Blood and Tissue Eosinophilia in Mice. *J Clin Invest* 1997; 99(5):1064-71.
5. España A, Sanz ML, Sola J, et al. Wells' Syndrome (Eosinophilic Cellulitis): Correlation between Clinical Activity, Eosinophil Levels, Eosinophil Cation Protein and Interleukin-5. *Br J Dermatol* 1999; 140(1):127-30.
6. Kaufmann D, Pichler W, Beer JH. Severe Episode of High Fever with Rash, Lymphadenopathy, Neutropenia, and Eosinophilia after Minocycline Therapy for Acne. *Arch Intern Med* 1994; 154(17):1983-4.
7. Hirsch K, Ludwig RJ, Wolter M, et al. Eosinophilic Cellulitis (Wells' Syndrome) Associated with Colon Carcinoma. *J Dtsch Dermatol Ges* 2005; 3(7):530-1.
8. Heelan K, Ryan JF, Shear NH, et al. Wells Syndrome (Eosinophilic Cellulitis): Proposed Diagnostic Criteria and a Literature Review of the Drug-Induced Variant. *J Dermatol Case Rep* 2013; 7(4):113-20.
9. Winfield H, Lain E, Horn T, et al. Eosinophilic Cellulitislike Reaction to Subcutaneous Etanercept Injection. *Arch Dermatol* 2006; 142(2):218-20.
10. Odia SG, Purschel W, Worret WI, et al. Hypereosinophilic Cellulitis (Wells' Syndrome) Resembling Urticarial. *Acta Derm Venereol (Ljubljana)* 1994; 6:193-195.
11. Spinelli M, Frigerio E, Cozzi A, et al. Bullous Wells' Syndrome Associated with Non-Hodgkin's Lymphocytic Lymphoma. *Acta Derm Venereol* 2008; 88(5):530-1.
12. Mutasim DF, Cooper CH. A Case of Wells' Syndrome in a Patient with Lymphocytic Lymphoma. *Geriatr Dermatol* 1996; 4(1):11-14.
13. Steffen C. The Man behind the Eponym. George Crichton Wells: Eosinophilic Cellulitis (Wells Syndrome). *Am J Dermatopathol* 2002; 24(2):164-5.
14. Caputo R, Marzano AV, Vezzoli P, et al. Wells Syndrome in Adults and Children: A Report of 19 Cases. *Arch Dermatol* 2006; 142(9):1157-61.
15. Aberer W, Konrad K, Wolff K. Wells' Syndrome Is a Distinctive Disease Entity and Not a Histologic Diagnosis. *J Am Acad Dermatol* 1988; 18(1 Pt 1):105-14.
16. Odia SG, Puerschel W, Worret WI, et al. Hypereosinophilic Cellulitis (Wells' syndrome) Resembling Urticaria. *Acta Dermatovenerologica Alpina Panonica et Adriatica (APA)* 1994; 4:193-6.
17. Herr H, Koh JK. Eosinophilic Cellulitis (Wells' Syndrome) Successfully Treated with Low-dose Cyclosporine. *J Korean Med Sci* 2001; 16(5):664-8.
18. Husak R, Goerdts S, Orfanos CE. Interferon Alfa Treatment of a Patient with Eosinophilic Cellulitis and HIV Infection. *N Engl J Med* 1997; 337(9):641-2.
19. Davis RF, Dusanjh P, Majid A, et al. Eosinophilic Cellulitis as a Presenting Feature of Chronic Eosinophilic Leukaemia, Secondary to a Deletion on Chromosome 4q12 Creating the FIP1L1-PDGFR $\alpha$  Fusion Gene. *Br J Dermatol* 2006; 155(5):1087-9.