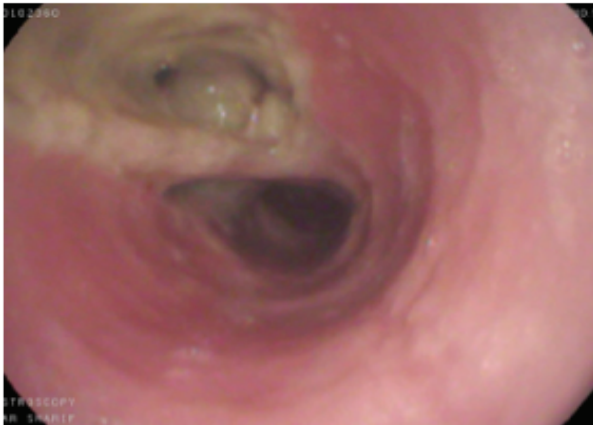

## Medical Quiz

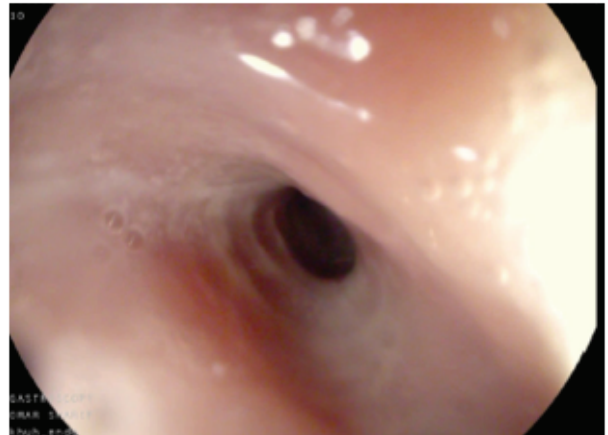
Hafsa Abdulla, MD\* Jenan Obaid, MBBCh BAO\*\* Omar Sharif, MD\*\*\*

A thirty-year-old male not known to have any medical illnesses presented to the Emergency Department with history of inability to swallow solids and liquids for few hours; the episode was evident after having food. On examination, the patient was unable to swallow his saliva. Endoscopy was performed; X-rays and a chest CT scan were taken.

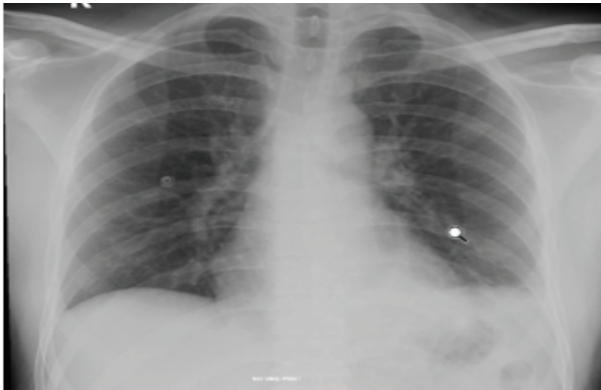Look at the figures below and answer the following questions:



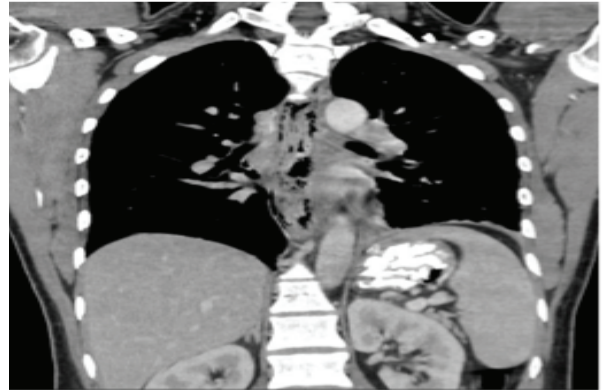
**Figure 1**



**Figure 2**



**Figure 3**



**Figure 4**

Q1: Describe the endoscopic findings in figures 1 and 2.

Q2: Name the complication revealed in figures 3 and 4.

Q3: Name other complications associated with this condition.

Q4: List three disorders known to cause the condition as shown in figures 1 and 2.

Answers on page 129

---

\* Senior House Officer

\*\* Consultant

Department of Internal Medicine

King Hamad University Hospital

Kingdom of Bahrain

E-mail: hafsa.bucheery@gmail.com