

Spiramycin: A Safe and Effective Option for Treatment of Ocular Toxoplasmosis

Seemantini Ayachit, MBBS, DOMS, PGDM-HM*

Kevin Dunne, MB BChir, FRCPC, DCH, MBBS, FRCPC** Wael Wagih, PhD, FRCS***

Ocular Toxoplasmosis is a non-curable infectious disease caused by *Toxoplasma Gondii* and is one of the leading causes of severe visual impairment due to the involvement of posterior segment of the eye. Involvement of posterior pole causes severe visual impairment in many patients.

We report a case of ocular Toxoplasmosis in a 12-year-old female child. The child was clinically diagnosed as having ocular Toxoplasmosis involving the whole posterior pole of the left eye and few parafoveal lesions in the right eye. Follow-up visit revealed new chorioretinitis lesions in the left eye. The patient was treated with oral Spiramycin 1500 mg/day in two divided doses with prednisolone tablet (1mg/kg body weight) for a period of 6 weeks. The chorioretinitis lesions regressed in 3 weeks and follow-up one year after cessation of treatment revealed no recurrence. Spiramycin proved to be effective, safe, economic and easy to administer as twice daily oral dose.

Bahrain Med Bull 2016; 38 (2): 116 - 118

Toxoplasma Gondii is a protozoan parasite; humans are the intermediate host and cats are final hosts^{1,2}. The three main forms of the parasite are oocyst, spore form which is excreted in cat's feces, Tachyzoites, actively proliferating form and Bradyzoite, inactive encysted form found in human tissues. Toxoplasmosis is widely prevalent around the world, affecting a large number of individuals in Europe, 26% to 47%, Latin America, 23% to 98%, Asia, 25% to 70%, Africa, 24% to 46%, USA, 9% to 14% and Canada, 28%^{3,4}. Ocular toxoplasmosis is a non-curable infectious disease caused by *Toxoplasma Gondii* and is one of the leading causes of severe visual impairment due to the involvement of posterior segment of the eye.

Toxoplasmosis causes chorioretinitis (CR) with a typical predilection for the posterior pole of the eye and is bilateral in 80% of cases¹. Involvement of posterior pole causes severe visual impairment in many patients; however, some are detected on a routine fundus examination. Several therapeutic regimens have been used for the treatment of ocular Toxoplasmosis. Triple drug therapy with Pyrimethamine, Sulfadiazine and prednisolone are most commonly used^{5,6,7}. This regimen is accompanied by headache, nausea, vomiting and a persistent feeling of ill-being. Patients often discontinue this regimen owing to a large number of tablets and ensuing side effects.

The aim of this presentation is to report the successful use of Spiramycin for the treatment of recurrence of ocular Toxoplasmosis in a 12-year-old female child.

THE CASE

A twelve-year-old female child complained of poor vision in the left eye. There was no history of any medical illness, and the poor vision was noticed at school by the teacher.

Best Corrected Visual Acuity in her right eye was 6/6 and in left eye 5/60. The cover test revealed a constant left exotropia (15* distance and 10* near). Anterior segment eye examination with slit-lamp was within normal limits. Dilated fundus examination revealed two chorioretinal scars in the right posterior pole and three scars in the left eye posterior pole, one of which was a large involving the whole of the fovea, see figures 1 and 2.

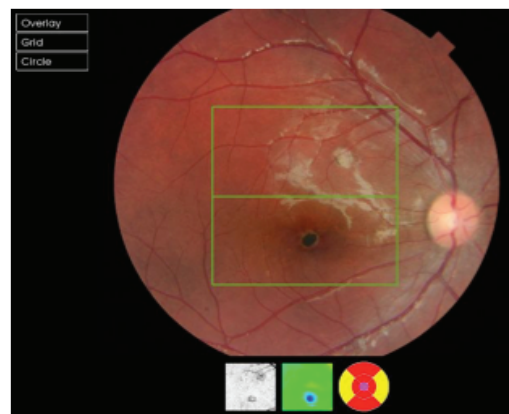

Figure 1: Right Eye Fundus before Reactivation of the Disease

* Registrar
Department of Ophthalmology
** Consultant
Department of Pediatrics
*** Head of Department
Department of Ophthalmology
King Hamad University Hospital
Kingdom of Bahrain
Email: seemantini.ayachit@khuh.org.bh

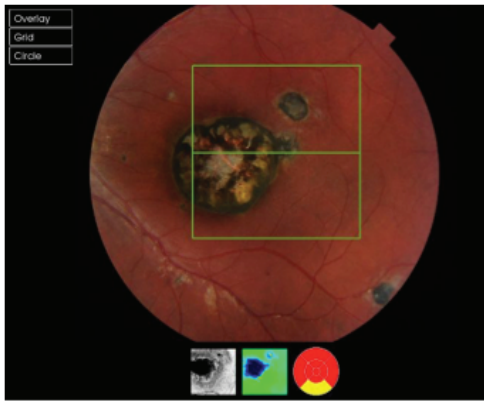


Figure 2: Left Eye Fundus before Reactivation of the Disease

A clinical diagnosis of ocular toxoplasmosis was made. Patient's mother denied any exposure to *Toxoplasma* infection. The mother and three siblings were screened for toxoplasmosis and were found negative. Most likely, the child had acquired the infection in early childhood as the parents confirmed the presence of cats as pets in their house. The lesions were documented with 3D Optical Coherence Tomography (OCT). The patient was followed-up 3-monthly intervals and at six months, new chorioretinitis lesions were detected on OCT. The child was referred to pediatric OPD for further assessment and management. Other systemic examination revealed no abnormality. Immunological tests revealed elevated *Toxoplasma*-specific IgG and IgM titers⁸.

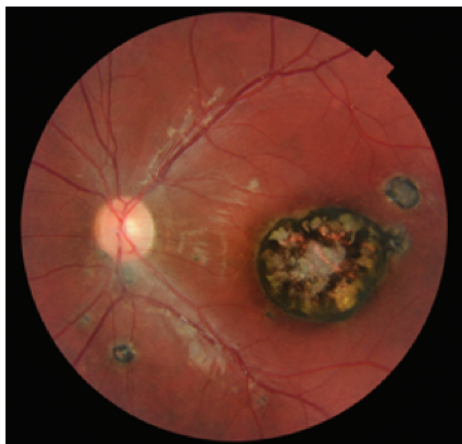


Figure 3: Active Retinitis with Fresh Lesion in the Left Eye

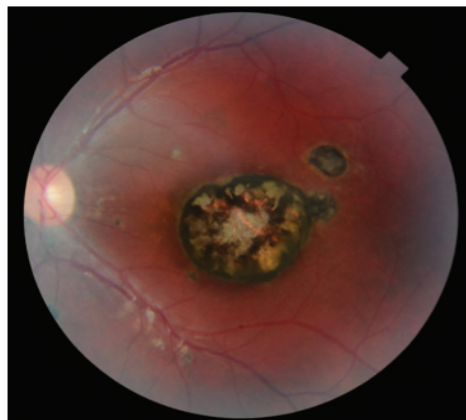

Figure 4: Four Weeks of Spiramycin Showing Regression of Active Retinitis

The patient was treated with oral spiramycin 1500 mg/day in two divided doses with prednisolone tablet (1 mg/kg body weight) for six weeks; the prednisolone was gradually tapered after four weeks. Follow-up OCT revealed regression of active chorioretinitis after three weeks. IgM titers reduced after four weeks. There was no side-effect related to spiramycin, although prednisolone caused facial puffiness and slight water retention. The child was regularly followed up in the Departments of Ophthalmology and Pediatrics for over one year after cessation of treatment with no new lesions appearing in the retina.

DISCUSSION

Toxoplasma Gondii is a protozoan parasite; humans are the intermediate host and cats are final hosts^{1,2}. The three main forms of the parasite are oocyst spore form which is excreted in cat's feces, Tachyzoites actively proliferating form and Bradyzoite inactive, encysted form found in human tissues.

Human beings are infected with *Toxoplasma* commonly through ingestion of oocysts, which are present in cat feces. These may also come from fruits and vegetables contaminated with *Toxoplasma* oocysts. Consumption of raw meat or deer blood is commonly the source of infections in some countries². Contaminated drinking water could be a source of infection in developing countries¹. *Toxoplasmosis* is known for its trans-placental transmission, neonates with infected mothers should be routinely screened for early detection and treatment of toxoplasmosis⁹.

Most *Toxoplasma* infections go unnoticed as they are sub-clinical, some patients may present with flu like symptoms. Ocular infestation with the parasite typically affects the posterior pole causing retinitis followed by choroiditis. The host-immune response is responsible for the conversion of *Toxoplasma* tachyzoites to bradyzoites, followed by their encystment¹⁰. These cysts may remain inactive for years; however, if they rupture, the organisms are released causing new lesions in the retina. In our patient, active retinitis was seen in the left eye with the appearance of a new lesion.

Many clinicians do not treat *Toxoplasmosis* due to its self-limiting nature. The aim of the treatment is to arrest the multiplication of parasites and to reduce the retinal destruction. The classical triad of pyrimethamine, sulfadiazine and corticosteroids are the most widely used treatment option^{5,6,7}. The most discouraging fact with this treatment is inconsistent results, non-compliance due to the large number of tablets to be swallowed every day and complications associated with this regimen which includes headache, nausea, vomiting, persistent feeling of ill-being and formation of sulfonamide crystals in renal tubules.

We used Spiramycin to treat this patient, a macrolide antibiotic which is used in a variety of infections including bacterial, protozoal and even in some viral diseases. Spiramycin is the drug of choice to treat pregnant women with *Toxoplasmosis*.

It is available in tablet and capsule forms and has been successfully and safely used in pregnant women and children. Adult dose varies from 1.5 to 2 grams, three times daily and in children 25 mg/kg body weight, twice daily for four to six weeks, depending on the response.

Our patient was treated with a combination of Spiramycin and prednisolone to prevent destructive response due to immune reactions. There was no major side-effect except facial puffiness and slight water retention due to prednisolone. The active retinitis regressed in four weeks with no new scarring in the retina.

CONCLUSION

Ocular Toxoplasmosis is a common and important cause of ocular morbidity in children and once detected in a child, should be followed up regularly as recurrences are a common feature of this disease. In this case Spiramycin was chosen as a drug of choice to treat active chorioretinitis due to its high safety indices in children and pregnant women.

Author Contribution: All authors share equal effort contribution towards (1) substantial contribution to conception and design, acquisition, analysis and interpretation of data; (2) drafting the article and revising it critically for important intellectual content; and (3) final approval of manuscript version to be published. Yes.

Potential Conflicts of Interest: None.

Conflict of interest: None. **Sponsorship:** None.

Submission Date: 13 August 2015.

Approval Date: 23 March 2016.

Ethical Approval: Approved by Research and Ethics Committee, King Hamad University Hospital, Bahrain.

REFERENCES

1. Béraud G, Pierre-François S, Foltzer A, et al. Cotrimoxazole for Treatment of Cerebral Toxoplasmosis: An Observational Cohort Study During 1994-2006. *Am J Trop Med Hyg* 2009; 80(4):583-7.
2. Specific Igm, Igg And Igg1 Directed Against Toxoplasma Gondii Detected by Flow Cytometry and Their Potential as Serologic Tools to Support Clinical Indirect Fundoscopic Presumed Diagnosis of Ocular Disease. Martins Lm, Rangel Al, Peixe Rg. *J Immunol Methods*. 2015; 417:97-106.
3. Pappas G, Roussos N, Flagg ME. Toxoplasmosis Snap Shots-Global Status of Toxoplasma Gondii, Seroprevalence and Implication for Pregnancy and Congenital Toxoplasmosis. *Int J Parasitol* 2009; 39(12):1385-94.
4. Jiménez-Coello M, Acosta-Viana KY, Guzmán-Marín E, et al. Toxoplasmosis: A Relevant Zoonotic Food Borne Disease Intropical Conditions. *African Journal of Microbiology Research* 2012; 6(12):2956-64.
5. Harrell M, Carvounis PE. Current Treatment of Toxoplasma Retinochoroiditis: An Evidence-Based Review. *J Ophthalmol* 2014; 2014:273506.
6. Montoya JG, Remington JS. Management of Toxoplasma Gondii Infection during Pregnancy. *Clin Infect Dis* 2008; 47(4):55466-.
7. Standford MR, See SE, Jones LV, et al. Antibiotics for Toxoplasmosis Retinochoroiditis: An Evidence-Based Systematic Review. *Ophthalmology* 2003; 110(5):926-31.
8. Meroni V, Genco F, Tinelli, et al. Spiramycin treatment of Toxoplasma gondii infection in pregnant women impairs the production and avidity of T.gondii-specific IgG antibodies- *Clin Vaccine Immunol* 2009; 16(10):1517-20.
9. Palanisamy M, Madhavan B, Balasundaram MB, et al. Outbreak of Toxoplasmosis in Coimbatore, India. *Indian J Ophthalmol* 2006; 54(2):12931-.
10. Congenital Toxoplasmosis. Center for Disease Control and Prevention, CDC Recommendations, 2006. <http://www.cdc.gov/parasites/toxoplasmosis/publications.html> Accessed on 8 August 2015.