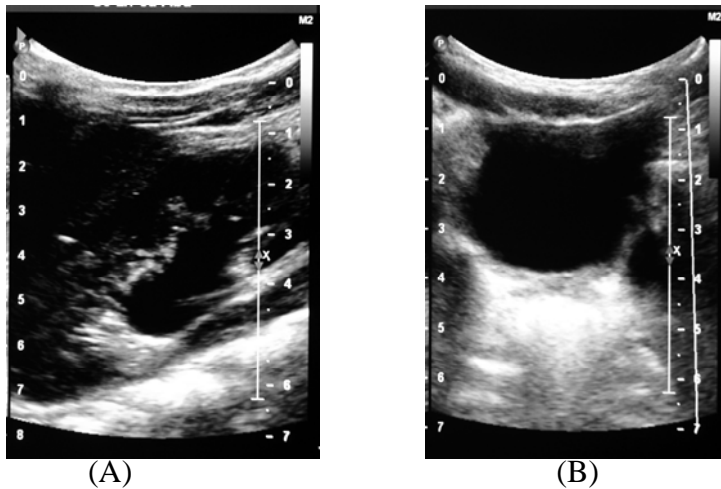


Medical Quiz

Saeed Alhindi, MD, CABS, FRCSI*

Ten-month-old male patient presented to Salmaniya medical complex with history of urinary tract infection of one-week duration. Physical examination was unremarkable. The patient had the following radiological tests.



Please answer the following:

- Q.1.** Describe the findings.
- Q.2.** Mention one common cause and one rare cause.
- Q.3.** What are the laboratory investigations, which could confirm the diagnosis?
- Q.4.** What is the most likely diagnosis if the above radiological test is normal?

Answers on page No. 50

* Assistant Professor, Arabian Gulf University
Senior Consultant Pediatric Surgeon
Salmaniya Medical Complex
Kingdom of Bahrain
Email: sjalhindi@yahoo.com