

Brain Tumor in Pregnancy

Khalil E Rajab, FRCOG, FFFP * Nouf Behzad N, MD, Arab Board**

A thirty-four year old Bahraini woman, para 4, at 32 weeks of gestation had developed progressive loss of vision, headaches and nausea. She was referred from neurosurgery to obstetrics department for urgent premature induction of labor. A Cesarean section was performed. A premature baby was resuscitated by neonatal pediatrics and the patient was referred to neurosurgery for excision of the tumor. The tumor was diagnosed as meningioma.

This case was reported because of its rarity and to present an update on methods of treating brain tumor in pregnancy.

Bahrain Med Bull 2013; 35(1):

Extra or intracranial brain tumor is an uncommon diagnosis during pregnancy. It poses a challenge to the obstetrician, to the pregnant woman and to her unborn fetus.

In general, the most common type of benign tumor of the brain is meningioma, its incidence is 27% of all primary tumors of the brain; women are more predisposed than men¹. A survey from Saudi Arabia revealed that 600 cases of brain tumor seen in pregnancy over 15 years' period, only 18 patients had meningioma². Another study revealed that 7 cases were diagnosed with brain tumor and 5 were due to meningioma during pregnancy³. In Bahrain, this is the first reported case of meningioma complicating pregnancy treated in Salmaniya Medical Complex (SMC) over the past ten years.

The aim of reporting this case is its rarity and the potential variability of its clinical presentation.

THE CASE

A thirty-four year old, gravida 5, para 4, Bahraini woman presented at 32 weeks of gestation with a history of gestational diabetes and a gradual loss of vision over 10 weeks and culminated into complete loss of vision prior to admission. She also complained of occasional mild

* Professor of Obstetrics and Gynecology

AGU

** Senior Resident

Department of Obstetrics and Gynecology

Salmaniya Medical Complex, Bahrain

Email: yonrajab@batelco.com.bh

headache and nausea. The patient was originally followed-up by an ophthalmologist who did a fundoscopy, which revealed total optic atrophy in the left eye with pale disc in the right eye. He recommended standard MRI sequences of the skull according to the pituitary protocol.

The MRI showed a large mainly suprasellar mass measuring 4x3.9x3.2 cm which was indenting the adjacent cerebral peduncle, and seen surrounding the vessels in the suprasellar region which might be due to dural tear interiorly. Another small dural tear suspected anteriorly, more pronounced on the sagittal sequence. Contrast was not used because of pregnancy. A suprasellar meningioma was suspected, see figure 1. A neurosurgeon confirmed the diagnosis and advised terminating the pregnancy and excision of the tumor.

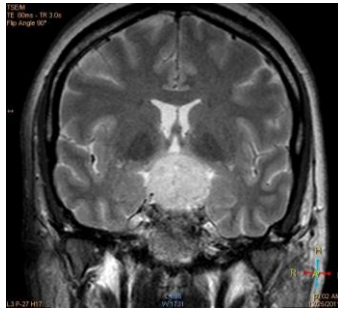


Figure 1: A Mass at the Suprasellar Region, Surrounding and Encasing the Blood Vessels on the Suprasellar Cistern and Displacing the Cerebral Peduncle Laterally

Ultrasound showed a single viable fetus 32 weeks of gestation without apparent malformation. Growth hormone was 0.337 (N - 16 mg/L), prolactin 109.0 (3.4 - 24.1 ng/nL), TSH 1.1 (0.5 - 5 μ U/mL), HbA1c 20-23(\leq 6.5). Dexamethasone (Decadron®) injection was given to stimulate pulmonary surfactant in fetal lungs. The pregnancy was terminated by a lower segment Cesarean section. A live premature baby was born and was looked after in the premature unit.

On the third postoperative day, the patient had bifrontal and orbito-zygomatic osteotomy and excision of the tumor. Postoperatively, she developed generalized seizures and was kept on diazepam 5 mg PRN. Her general condition gradually improved and she was discharged on the seventh postoperative day.

The histopathology of the excised tumor was reported to be a meningioma. Her vision slightly improved but remained with major impairment six weeks later.

DISCUSSION

Meningiomas are the most common type of brain tumor, which arise from the cells of the arachnoids villi of the meninges. They are usually located intracranially, but could arise in the spinal column and account for 20-25% of all brain tumor. Meningioma is usually single, but multiple meningiomas have been reported in the brain. Almost, 90% of tumors are benign as the case presented, but 10% shows signs of malignancy. However, benign meningioma might be associated, on occasion, with severe symptoms, disability and can be life threatening⁴⁻⁷.

Symptoms of brain tumor in pregnancy might be due to increased intracranial pressure, which include nausea, vomiting, headaches, seizures, visual disturbances or blindness due to involvement of the pituitary fossa or the optic chiasma. Sensory loss, paralysis or behavioral changes are uncommon^{8,9}. In our patient, the symptoms encountered were mainly loss of vision, vomiting and headache.

Discovery of meningioma during pregnancy constitute a challenge to the attending obstetrician and generate the need for a multidisciplinary approach, which includes neuro-oncology. The tumor progression increases with pregnancy¹⁰⁻¹¹. MRI is suitable imaging in pregnancy because it does not involve ionic radiation exposure. CT scan is used with caution particularly in early pregnancy. Not enough studies were performed to determine the safe use of contrast medium in pregnancy¹².

Treatment of brain tumor in pregnancy requires an integrated multidisciplinary approach, which includes neurosurgery, ophthalmology, radiology, obstetrics, neonatal pediatrics and ethics expert to consider the question of termination if the tumor was diagnosed in early pregnancy. Fortunately, this case was referred at 32 weeks of gestation when the fetus was viable. Early premature induction should be considered if chemo or radiotherapy is required in pregnancy. Cranial irradiation in early pregnancy should not be entertained which could result in fetal demise, malformation or abortion; others suggested the use of focal instead of whole brain radiation, and the use of photon instead of heavy charged particles radiation; a better option would be to postpone radiation after delivery if tumor is diagnosed in the third trimester. Chemotherapy includes drugs that may be teratogenic if given in the first trimester. Although the risk of these drugs to the fetus is minimal in the second trimester, most experts recommend that chemotherapy should not be used in pregnancy. Symptoms related to increase in intracranial pressure or due to brain edema, such as, headaches, nausea, blurring of vision or blindness may be treated with glucocorticoids or mannitol. These drugs can be given during pregnancy with some precautions. The mainstay of managing pituitary tumor is surgery¹³.

CONCLUSION

This case was reported because of its rarity and to present an update on methods of treating brain tumor in pregnancy.

Optimizing management of brain tumor in pregnancy needs a multidisciplinary approach and difficult decisions have to be made between the safety of the pregnant patient and the viability of her unborn infant.

Author contribution: All authors share equal effort contribution towards (1) substantial contributions to conception and design, acquisition, analysis and interpretation of data; (2) drafting the article and revising it critically for important intellectual content; and (3) final approval of the manuscript version to be published. Yes

Potential conflicts of interest: None

Competing interest: None **Sponsorship:** None.

Submission date: 12 September 2012 **Acceptance date:** 13 February 2013

Ethical approval: Department of Obstetrics and Gynecology, Salmaniya Medical Complex.

REFERENCES

1. Cowppli-Bony A, Bouvier G, Rue M, et al. Brain Tumors and Hormonal Factors: Review the Epidemiological Literature. *Cancer Causes Control* 2011; 22(5): 697-74.
2. Kanaan I, Jallu A, Kanaan H. Management Strategy for Meningioma in Pregnancy: A Clinical Study. *Skull Base* 2003; 13(4): 197-203.
3. Allumimi I, AL-Anazi AR. Meningioma in Pregnancy. *Bah Med Bull* 2004; 26(2): 45-8.
4. Pavlidis NA. Coexistence of Pregnancy and Malignancy. *Oncologist* 2002; 7(4): 279-87.
5. Patel V, Woodward A, Feigin V, et al. Mental and Neurological Public Health: A Global Perspective. 1st Ed. UK: Academic Press, 2011: 1-560.
6. Rockhill J, Murgala M, Chamberlain MC. Intracranial Meningiomas: An Overview of Diagnosis and Treatment. *Neurosurg Focus* 2007; 23(4): E1.
7. Palma L, Celli P, Franco C, et al. Longterm Prognosis for Atypical and Malignant Meningioma: A study of 71 Surgical Cases. *J Neurosurg* 1997; 86(5): 793-800.
8. Doyle LW, Kitchen WH, Ford GW, et al. Effects of Antenatal Steroids Therapy on Mortality and Morbidity in Very Low Birth Weight Infant. *J Pediatrics* 1986; 108(2): 287-92.
9. Batchelor T. Neuro-oncologic Diseases of Women. Available at: <http://brain.mgh.harvard.edu/WomensTumors.htm>. Accessed on 15.1.2012.
10. McCollough CH, Schueler BA, Atwell TD, et al. Radiation Exposure and Pregnancy: When Should We Be Concerned? *Radiographics* 2007; 27(4): 909-17; discussion 917-8.
11. Weiseler KM, Bhagava P, Kanal KM, et al. Imaging in Pregnant Patients. Examination Appropriateness. *Radiographics* 2010; 30(5): 1215-29; discussion 1230-3.
12. Black P, Morokoff A, Zauberman J, et al. Meningioma: Science and Surgery. *Clin Neurosurg* 2007; 54: 91-9.
13. Van Calsteren K, Berteloot P, Hanssens M, et al. In Utero Exposure to Chemotherapy: Effects on Cardiac and Neurologic Outcome. *J Clin Oncol* 2006; 24(12): e16-7.