

## Pulmonary Arteriovenous Malformation: A Culprit of Middle Lobe Syndrome?

Hasan S. Massloom, American Board of Surgery, American Board of Thoracic Surgery\*

**Middle lobe syndrome (MLS) refers to lobar atelectasis and bronchiectasis and is either obstructive or non-obstructive type. A 63-year-old asthmatic female patient presented with recurrent pneumonia and unrelenting cough which proved to be due to pulmonary arteriovenous malformation that led to obstructive MLS. CT scan showed right middle lobe volume loss, bronchiectasis and dilated pulmonary vessels. The patient was operated for right middle lobectomy.**

**The pathological examination revealed pulmonary arteriovenous malformation with post obstructive changes. Pulmonary arteriovenous malformation should be part of the differential diagnosis of MLS and should prompt early referral for surgery. Middle lobe is anatomically susceptible to obstruction of the bronchus and to atelectasis due to its poor drainage and ventilation. Conservative treatment with antibiotics, bronchodilators, and chest physiotherapy are effective in 33.3 to 66.6% of patients. Lobectomy is required in a third of MLS patients who fail conservative management or have persistent symptoms that last more than 6 months or have malignant obstruction.**

*Bahrain Med Bull 2016; 38(1): 50 - 52*

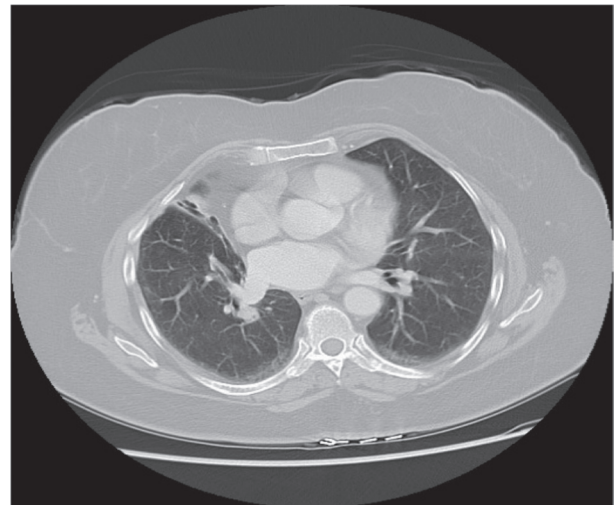Middle lobe syndrome is a lung disease that presents mainly as lobar atelectasis and bronchiectasis; it is either obstructive or non-obstructive type. Obstructive MLS is due to endobronchial or extrinsic lesions, which could be inflammatory or neoplastic. Pulmonary arteriovenous malformation as a cause of MLS has not been widely reported. Although this rare diagnosis was reached postoperatively, pulmonary arteriovenous malformation should be suspected as a cause of MLS, especially if CT scan shows dilated pulmonary vessels in the proximity of lobar atelectasis and bronchiectasis. Lobectomy is recommended for this type of MLS.

The aim of this presentation is to report a case of arteriovenous malformation that led to obstructive middle lobe syndrome in an asthmatic patient.

### THE CASE

A sixty-three-year-old asthmatic female was admitted with history of fever, cough and dyspnea. The patient denied history of hemoptysis, tuberculosis or weight loss. She was treated with antibiotics for right middle lobe pneumonia and was discharged after apparent improvement. The patient continued to suffer from wheezing and persistent cough for a few months. CT chest revealed volume loss of the right middle lobe with bronchiectatic changes consistent with long-standing obstructive process within its central tracheobronchial supply, see figure 1. Dilated pulmonary arteries were seen, which were initially assumed to be related to possible pulmonary hypertension.

The patient underwent right middle lobectomy. Gross pathology revealed middle lobe measuring 6.5 x 3.5 cm with dilated



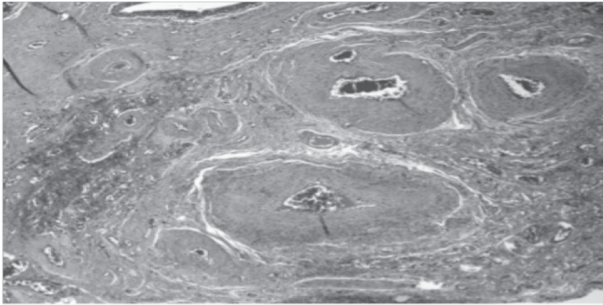
**Figure 1: CT Scan Reveals Volume Loss of the Right Middle Lobe with Bronchiectatic Changes**

bronchi. Microscopic examination revealed collapsed alveolar space, intra-alveolar clusters of hemosiderin-laden macrophages and alveoli lined by respiratory and bronchial epithelium filled with inspissated secretions. Large dilated bronchi with surrounding mild chronic inflammation were seen, predominantly lymphocytes. An unusual vascular lesion displayed numerous thickened arteries and focal dilated venous structures, see figures 2 and 3.

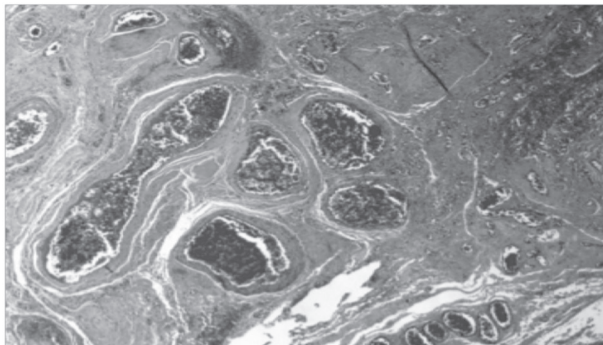
The arteries were characterized with medial hypertrophy and intimal fibroplasia. Venous structures were also present near the pleural space and were dilated with focal intimal fibroplasia, see figure 4. Furthermore, numerous post-obstructive changes

\* Consultant Cardiothoracic Surgery  
Johns Hopkins Aramco Healthcare  
Saudi Aramco  
Dhahran Kingdom of Saudi Arabia  
Email: Hasan.massloom@JHAH.com

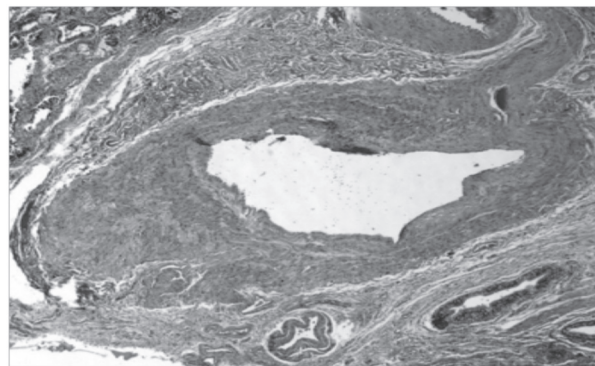
were evident, such as parenchymal fibrosis, bronchiectasis with luminal mucin and numerous carcinoid tumorlets, see figure 5. The vascular pathology and its location at the subpleural level could be attributed to arterio-venous malformation that has impinged on the lobar airway causing post-obstructive changes. The focal hemosiderosis may give further support that abnormal vessels were the underlying cause of the middle lobe syndrome, see figure 6.



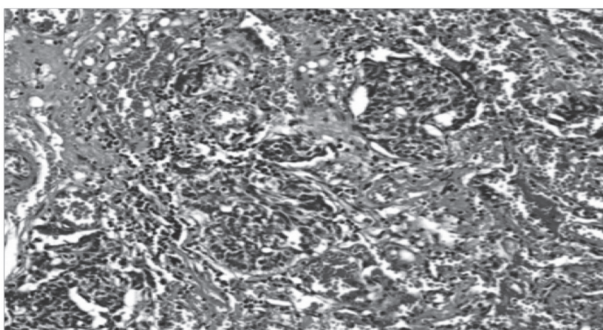
**Figure 2: Numerous Abnormally Thickened Arteries**



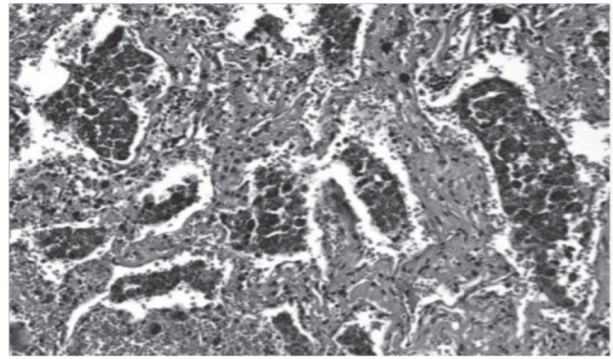
**Figure 3: Dilated Venous Structures**



**Figure 4: Dilated Veins with Intimal Fibroplasia**



**Figure 5: Carcinoid Tumorlets**



**Figure 6: Focal Hemosiderosis**

## DISCUSSION

The hallmark of middle lobe syndrome is atelectasis concomitant with bronchiectasis of the right middle lobe or lingula. Bronchiectasis, which is the most common histological feature, could be associated with myriad findings such as bronchitis, bronchiolitis, organizing pneumonia, thrombi, granulomatous inflammation and abscesses.

Two types of MLS were described, namely obstructive and non-obstructive. The two causal factors in both types are airway obstruction and poor lobar drainage. Obstructive MLS is caused by endobronchial lesions, broncholiths, inspissated secretions, endoluminal granulomas, foreign body or extrinsic compression of the middle lobe bronchus, such as hilar or peribronchial lymphadenopathy or tumors<sup>1</sup>. The enlargement of the peribronchial lymph nodes is the most common mechanism of the obstructive type; it could be due to granulomatous infections such as histoplasmosis, other fungal infections, typical and atypical mycobacterial infections and sarcoidosis<sup>2</sup>.

Non-obstructive MLS is due to narrow bronchus, juxtaposed to a cluster of lymph nodes and drains the middle lobe and lower lobe, and its take-off is almost at a right angle from the intermediate bronchus, which creates poor conditions for drainage<sup>3</sup>. Furthermore, the middle lobe is anatomically insulated from other lobes in a deep fissure with flimsy parenchymal passages through which insufficient collateral ventilation occurs, thus decreasing the likelihood of reinflation once atelectasis occurs<sup>4</sup>.

Middle lobe syndrome is one and a half to three times more common in females; MLS is recurrent and intermittent<sup>1,2</sup>. Patients with MLS present with cough, dyspnea, chest pain, wheezing, fever and chills<sup>1</sup>. Hemoptysis, weight loss, fatigue and low-grade fever may indicate suppurative infections. The disease is rarely subclinical and discovered by routine chest radiography.

Most often, chest radiographs show abnormal findings in the lateral view, such as volume loss of the right middle lobe seen as a triangle of increased density between the minor fissure and lower half of the major fissure<sup>5</sup>. The posterior-anterior radiograph may show obscuring of the right cardiac border (silhouette sign) because of the medial segment of the middle lobe is contiguous with the right atrium. Previous granulomatous infection may appear, such as calcified pulmonary nodules or hilar lymph nodes. Recently thin-slice

CT scan has enabled detection of subtle endobronchial lesions, distal bronchiectasis, lymphadenopathy, calcification and could delineate the etiology of extrinsic compression of the airway<sup>6</sup>.

Middle lobe syndrome warrants further evaluation with flexible bronchoscopy. It assesses patency of the airway, excludes malignant obstruction and allows specimen collection for infectious and neoplastic workup<sup>7</sup>.

Most cases of non-obstructive MLS respond to bronchodilators, mucolytics, antibiotics and avoidance of bronchial irritants, such as tobacco<sup>8</sup>. MLS associated with asthma is treated with inhaled corticosteroids and bronchodilators. Antibiotics are used to eradicate infection that could be associated with bronchiectasis, and are often continued for several weeks or months, as recurrences are common. Flexible bronchoscopy plays a bigger role; broncholiths and foreign bodies could be removed bronchoscopically. Several options are available to treat non-malignant obstruction, such as balloon dilatation, stent placement, argon plasma coagulation, electrocautery, cryosurgery and laser therapy. Chest physiotherapy and postural drainage are useful to enhance drainage and combat lung collapse in both types of MLS<sup>9</sup>. It is important to utilize bronchoscopic therapeutic options early in the course of the obstructive MLS to halt the progress of the disease into advanced bronchiectasis and recurrent pneumonitis. Approximately one to two-thirds of MLS patients sustain cure or show improvement in response to conservative treatment especially when bronchoscopy is utilized early in the course of treatment<sup>10</sup>. Best response occurs in the pediatric age group and the non-obstructive type of MLS.

Surgical lobectomy is reserved for refractory and complicated cases, recurrent hemoptysis unresponsive to interventional radiology, malignant biopsy or malignant cell in bronchial washing, scarred middle lobe, fibrosis and persistent symptoms with atelectasis for more than six months<sup>4,8</sup>. Surgery for MLS is similar to surgery for non-small lung carcinoma with the caveat of increased tendency to bleeding because of the extensive inflammation of the middle lobe and extensive dissection in the operative field. Most patients report relief of symptoms and excellent long-term survival.

## CONCLUSION

**Middle lobe syndrome is a lung disease that manifests predominantly as lobar atelectasis and bronchiectasis; it is either obstructive or non-obstructive. Pulmonary arteriovenous malformation should be suspected as a cause of obstructive MLS, especially if CT scan shows dilated pulmonary vessels in the proximity of lobar atelectasis and bronchiectasis. Lobectomy is recommended for this etiology of MLS.**

**Potential Conflicts of Interest:** None.

**Competing Interest:** None. **Sponsorship:** None.

**Submission Date:** 15 December 2015.

**Acceptance Date:** 6 February 2016.

**Ethical Approval:** Approved by Johns Hopkins Aramco Healthcare, Saudi Aramco, Kingdom of Saudi Arabia.

## REFERENCES

1. Gudbjartsson T, Gudmundsson G. Middle Lobe Syndrome: A Review of Clinicopathological Features, Diagnosis and Treatment. *Respiration* 2012; 84(1): 80-6.
2. Romagnoli V, Priftis KN, de Benedictis FM. Middle Lobe Syndrome in Children Today. *Paediatric Respiratory Rev* 2014; 15(2): 188-93.
3. Einarsson JT, Einarsson JG, Isaksson H, et al. Middle Lobe Syndrome: A Nationwide Study on Clinicopathological Features and Surgical Treatment. *Clin Respir J* 2009; 3(2): 77-81.
4. Shah A, Behera S, Panjabi C. Middle Lobe Syndrome: A Rare Presentation of Allergic Bronchopulmonary Aspergillosis. *Eur Ann Allergy Clin Immunol* 2014; 46(4): 147-151.
5. Arab A, Voduc N, Moyana T, et al. Middle Lobe Syndrome Due to Calcified Adenopathy. *Can Respir J* 2014; 21(4): 211-2.
6. Juggal TS, Garg A, Sethi GR, et al. Multi-Detector Computed Tomography Imaging of Large Airway Pathology: A Pictorial Review. *World J Radiol* 2015; 7(12): 459-74.
7. Ayed AK. Resection of the Right Middle Lobe and Lingula in Children for Middle lobe/Lingula Syndrome. *Chest* 2004; 125(1): 38-42.
8. Gudmundsson G, Gross TJ. Middle Lobe Syndrome. *Am Fam Physician* 1996; 53(8): 2547-50.
9. Priftis KN, Mermiri D, Papadopoulou A, et al. The Role of Timely Intervention in Middle Lobe Syndrome in Children. *Chest* 2005; 128(4): 2504-10.
10. Hamad AM, Elmistekawy E, Elatafy E. Chronic Atelectasis of the Left Lower Lobe: A Clinicopathological Condition Equivalent to Middle Lobe Syndrome. *Interact Cardiovasc Thorac Surg* 2012; 15(4): 618-21.