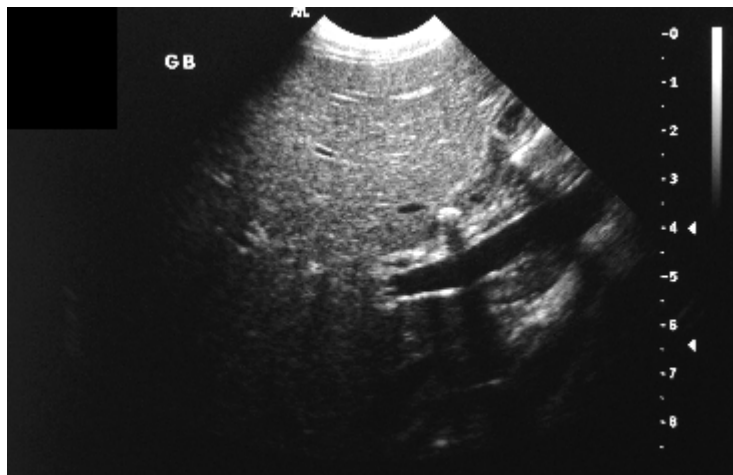


## Medical Quiz

Saeed Alhindi, MD, CABS, FRCSI\*

A nine-year-old Bahraini female presented to the outpatient clinic at Salmaniya hospital with history of recurrent right upper quadrant abdominal pain of three years duration. The pain is associated with vomiting. This patient is known sickle cell disease. The patient had the following radiological test, please answer the following questions.



**Q1.** Name the radiological test and describe the findings.

**Q2.** What is the diagnosis?

**Q3.** Mention three complications of this condition.