

Medical Quiz

Saeed Alhindi, MD, CABS, FRCSI*

A one-year-old male patient presented with irritability, vomiting and abdominal distention. The patient is ill-looking with generalized tenderness. The patient had repair of meningomyelocele after birth and after few weeks underwent surgery for hydrocephalus.

Look at the radiological images below and answer the following questions.

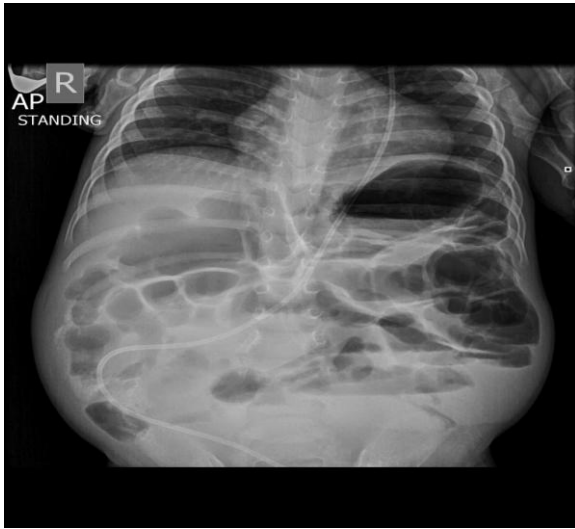


Figure 1

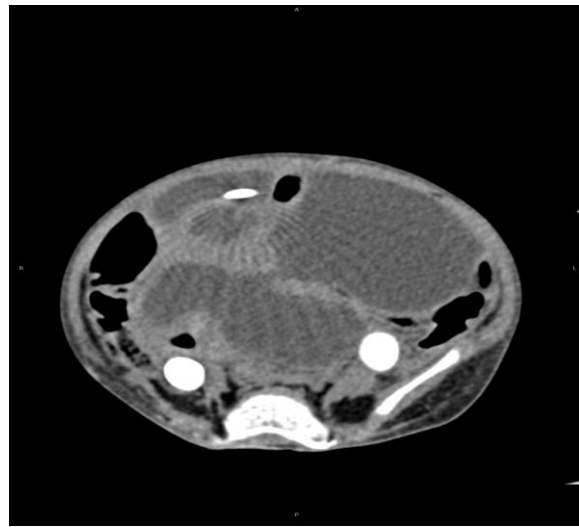


Figure 2

- Q1. Describe the findings in figures 1 and 2.
- Q2. Mention two complications related to ventriculoperitoneal shunt.
- Q3. What is the diagnosis?
- Q4. What is the name of surgery for hydrocephalus?

* Assistant Professor, AGU
Consultant Pediatric Surgeon
Department of Surgery
Salmaniya Medical Complex
Kingdom of Bahrain
Email: sjalhindi@gmail.com