

Medical Quiz

Saeed Alhindi, MD, CABS, FRCSI*

A twelve-year-old female patient presented with abdominal pain and vomiting of two days duration. Clinical examination revealed tenderness of lower abdomen. No history of fever or trauma.

Look at the figures below and answer the following questions:

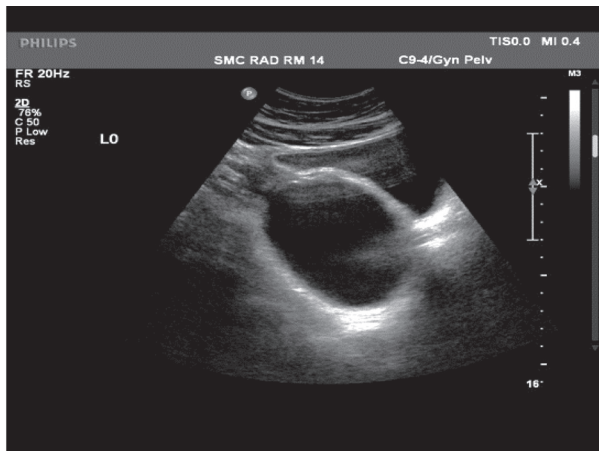


Figure 1

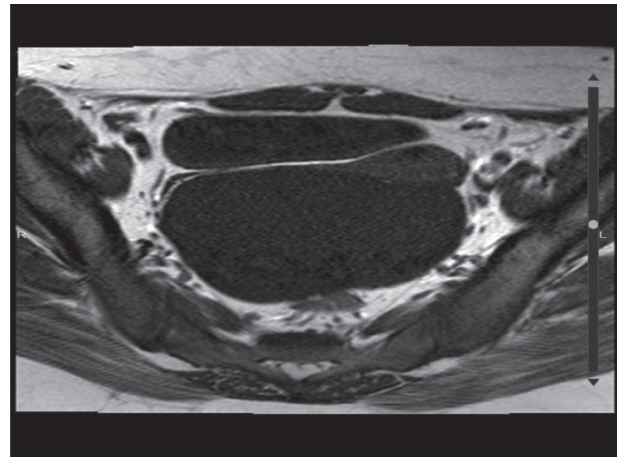


Figure 2

- Q1. Mention the radiological tests in both figures 1 and 2.
- Q2. Describe the findings in both figures 1 and 2.
- Q3. What is the diagnosis?

Answers on page 186

* Assistant Professor and Senior Consultant Pediatric Surgeon
Department of Surgery
Salmaniya Medical Complex
P.O. Box 12, Manama
The Kingdom of Bahrain
Email: sjalhindi@gmail.com