

FIGURE 3

M-mode Echocardiogram Showing the Myxoma Occupying the Mitral Orifice During Diastole

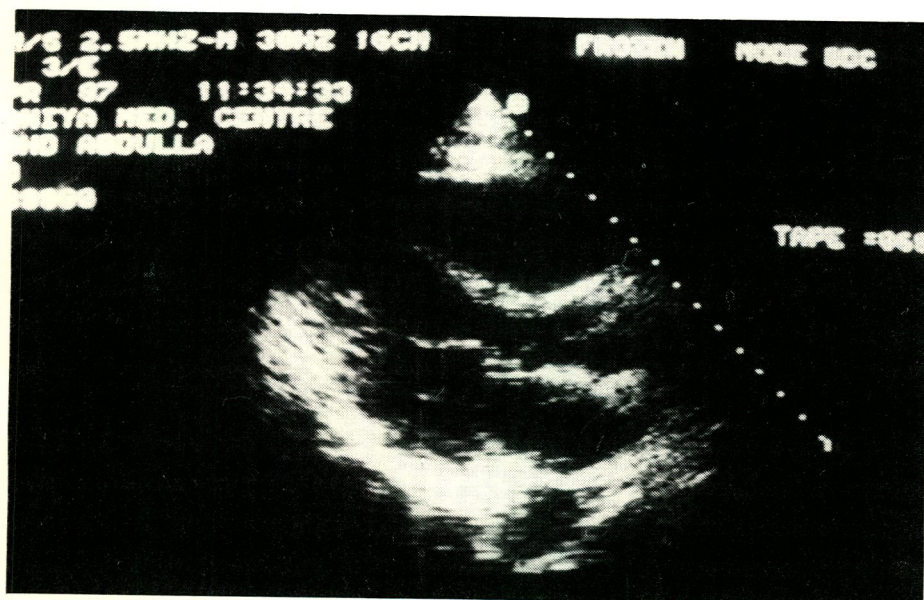
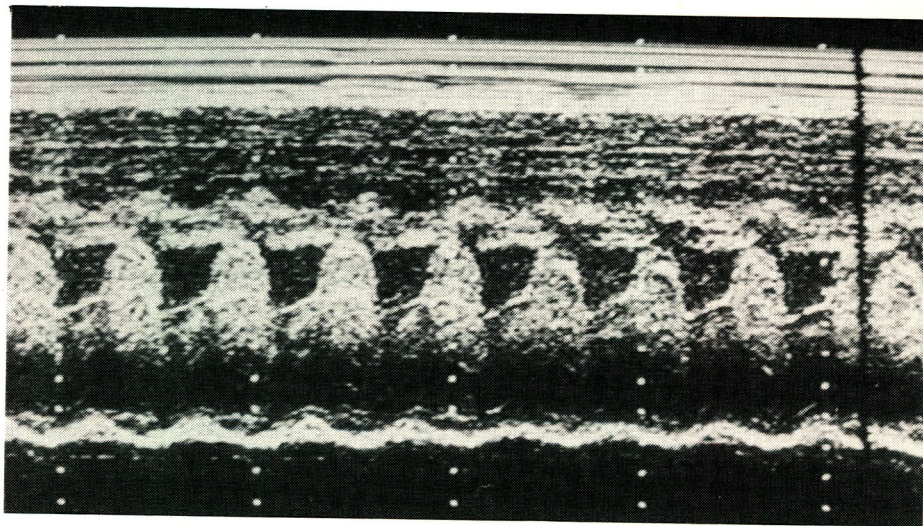


FIGURE 4

Post-operative Two-dimensional Echocardiogram in the Parasternal Long Axis View Showing Complete Removal of the Tumour

FIGURE 5

Normal Post-operative M-mode Echocardiogram. Note absence of the Mass in the Mitral Valve Orific

