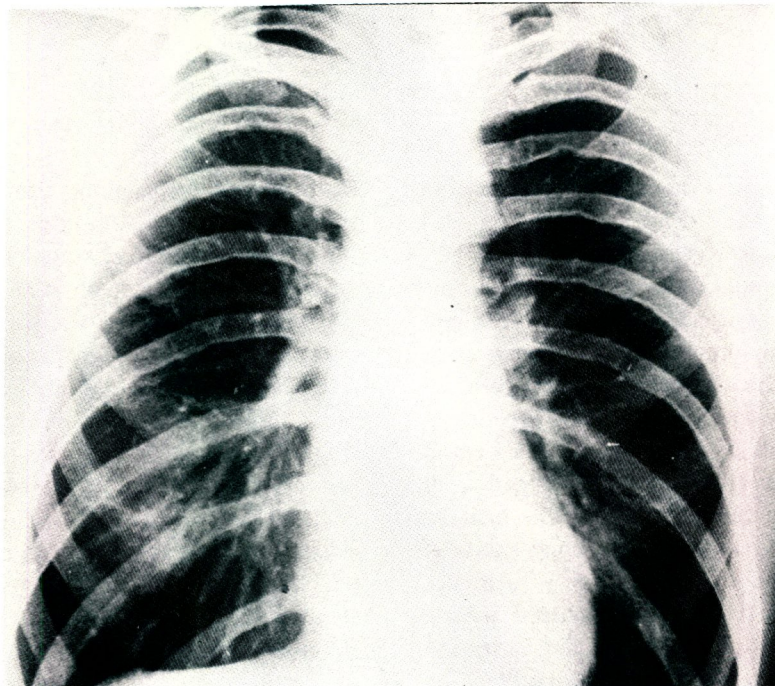


MEDICAL QUIZ

Dr Akbar Mohsin Mohammed
Dr Babiker Hassan



This is the plain film of the chest in a 10 year old hypertensive boy.

Q1. What is the radiological abnormality in this film?

Q2. What is the clinical significance of this abnormality?

Q3. What genetic disease should be suspected if this was a female patient?

Answers on Page No. 97
