

Acute Isolated Posterior Cerebral Artery Occlusion Successfully Treated with Combined Pharmacological and Mechanical Thrombectomy

Alaa Ayad, FRCR* Hossam Eldin Mohamed, MD**
Wael Ebrahim, MD, PhD***

Posterior cerebral artery (PCA) and other posterior circulation strokes are challenging to diagnose compared to anterior circulation strokes because of non-specific and fluctuating symptoms. This may delay timely diagnosis, treatment and affect patients' outcome and prognosis.

We report a case of an acute isolated PCA occlusion that was successfully treated with endovascular mechanical thrombectomy.

A sixty-nine-year-old female presented with dizziness, confusion, nausea and severe headache. Stroke code was activated. Plain CT was negative for hemorrhage or recent infarction. CT angiography (CTA) revealed total occlusion of P2 segment of right PCA. MRI showed acute infarction of the right deep temporal and occipital regions indicating diffusion restriction and dark signals in Apparent Diffusion Coefficient (ADC) map with diffusion-fluid-attenuated inversion recovery (FLAIR) mismatch. Systemic intravenous (IV) thrombolysis was given immediately after the diagnosis, followed by endovascular mechanical thrombectomy. Complete PCA endovascular recanalization and reperfusion was obtained 4 hours after the onset of symptoms with complete clinical recovery.

Endovascular mechanical recanalization prompt reperfusion is beneficial and results in a good clinical course in patients with PCA strokes.

Posterior circulation strokes represent approximately 20% of all ischemic strokes; the incidence of PCA strokes can be estimated from 5% to 10%¹. PCA and other posterior circulation strokes could be challenging to diagnose because of the presenting symptoms and clinical evaluation compared to anterior circulation strokes. Time of symptoms onset is essential in eligibility criteria for thrombolytic therapy (within 4.5 hours of symptoms onset)¹.

There are fewer reports on endovascular recanalization for acute isolated PCA occlusion compared to acute occlusion of the vertebro-basilar arteries²⁻³.

The aim of this report is to present a case of endovascular recanalization in the management of acute PCA stroke and its impact on patient clinical outcome.

THE CASE

A sixty-nine-year-old female patient presented with dizziness, confusion, nausea and severe headache of 2 hours duration. Neurological examination revealed acute right-sided cerebellar signs with National Institute of Health Stroke Scale (NIHSS) score of 9¹. The patient had residual right-sided weakness from a previous stroke two years ago (left MCA territory infarction). The CT was negative for hemorrhage or recent infarction. CTA revealed total occlusion of P2 segment of right PCA, see figures 1 (A) and 1 (B).

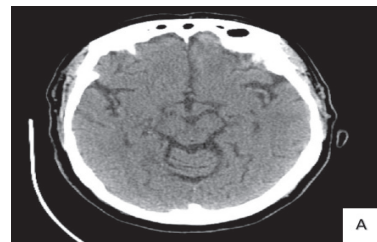

Figure 1 (A)

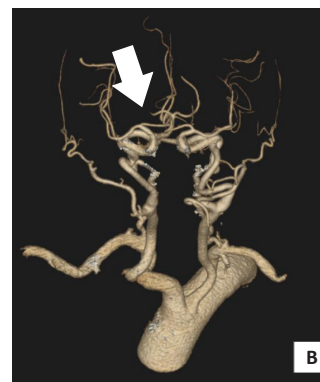

Figure 1 (B)

Figure 1: (A) Plain CT: Unremarkable (B) 3D Reconstructed CTA Showed Occluded Right PCA (Blue Arrow)

* Registrar
** Consultant
*** Consultant
Department of Interventional Radiology
King Hamad University Hospital
Kingdom of Bahrain
E-mail: wael.ebrahim@khuh.org.bh; alaa.ayad@khuh.org.bh

MRI diffusion showed a high-intensity area of restrictive diffusion involving right deep temporal and occipital regions with dark signals in ADC map and diffusion-FLAIR mismatch, see figure 2 (A-C).

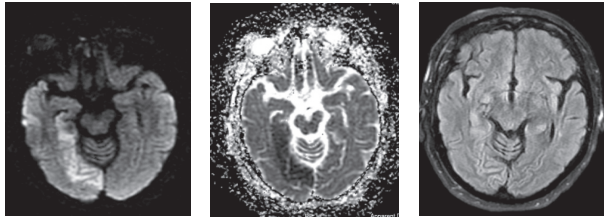


Figure 2 (A) **Figure 2 (B)** **Figure 2 (C)**
Figure 2: (A) MRI Diffusion: Right Deep Temporal and Occipital Diffusion Restriction (B) Low Signal in ADC Map Images (C) Diffusion – Flair Mismatch

Immediate systemic IV thrombolysis was given (loading dose of 7 mg, followed by 70 mg infusion over one hour) followed by mechanical endovascular thrombectomy.

Puncture of the right common femoral artery was performed, followed by the insertion of 6Fr femoral sheath. Selective catheterization of right common carotid artery (CCA) was performed using 6F Chaperon guiding catheter (Microvention Terumo-Japan). Diagnostic CCA revealed normal anterior cerebral circulation. Selective cannulation of right vertebral artery was performed using 6F Chaperon guiding catheter and diagnostic angiogram revealed total occlusion of P2 segment of right PCA, see figure 3 (A). Selective cannulation of right PCA was performed by Headway 1.7 Fr micro-catheter (Microvention-USA) over 0.014 Traxcess microwire (Microvention - USA). The thrombus was retrieved by Eric (4mm) stent (Microvention - USA). Post-thrombus retrieval, right vertebral angiogram revealed complete clearance of the thrombus with normal opacification of right PCA, see figure 3 (B).

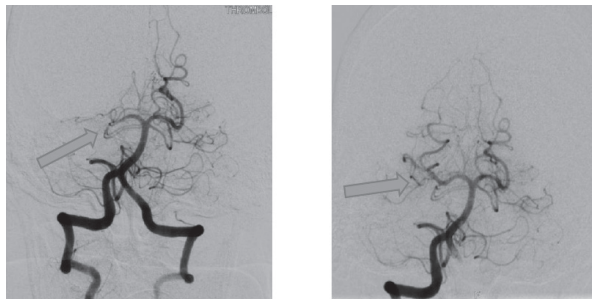


Figure 3 (A) **Figure 3 (B)**

Figure 3: (A) Angiography: Occluded Right PCA (Blue Arrow) (B) Well Recanalization of Right PCA after Mechanical Thrombectomy (Blue arrow)

DISCUSSION

Remarkable progress has been made in endovascular treatment (EVT). It is an effective therapeutic option in acute ischemic strokes due to large vessel occlusion. Approximately 5% to 10% of acute ischemic strokes occur in the area of PCA. Lacunar

infarction is the most frequent stroke subtype, followed by atherothrombotic and cardioembolic infarctions^{2,3}. PCA strokes present with various symptoms and are sometimes not properly described by the patient. Patients are frequently unaware of their symptoms, or symptom recognition is delayed. Therefore, the diagnosis is often delayed and the patient presents late for thrombolytic therapy.

Studies have shown that EVT for posterior circulation major artery occlusion, such as vertebral artery (VA) or basilar artery (BA) achieve a high rate of recanalization and a low rate of complications. EVT for small vessels like PCA is still controversial regarding efficacy and safety⁴⁻⁷. The rate of recanalization was higher in EVT and the rate of complications showed no difference compared to medical treatment⁴⁻⁷.

In this case, we used a tissue plasminogen activator (t-PA) (the patient's NIHSS score was 9), immediately followed by stent retriever mechanical thrombectomy with successful clot removal.

CONCLUSION

PCA stroke severely affects the quality of life. Therefore, the treatment decision should be based on a general view of the patient as well as their NIHSS score. Prompt reperfusion leads to a good clinical course.

To the best of our knowledge, this is the first reported case of acute isolated PCA occlusion in Bahrain which was successfully treated with mechanical thrombectomy using stent retrieval immediately after systemic thrombolysis with t-PA.

Author Contribution: All authors share equal effort contribution towards (1) substantial contributions to conception and design, acquisition, analysis and interpretation of data; (2) drafting the article and revising it critically for important intellectual content; and (3) final approval of the manuscript version to be published. Yes.

Potential Conflicts of Interest: None.

Competing Interest: None.

Sponsorship: None.

Acceptance Date: 25 August 2019.

Ethical Approval: Approved by the Research and Ethics Committee, King Hamad University Hospital, Bahrain.

REFERENCES

1. Lyden PD, Lu M, Levine SR, et al. A Modified National Institutes of Health Stroke Scale for Use in Stroke Clinical Trials: Preliminary Reliability and Validity. *Stroke* 32: 1310– 1317, 2001.
2. Breuer L, Huttner HB, Jentsch K, et al. Intravenous Thrombolysis in Posterior Cerebral Artery Infarctions. *Cerebrovasc Dis* 31: 448– 454, 2011.

3. Arboix A, Arbe G, Garcia-Eroles L, et al. Infarctions in the Vascular Territory of the Posterior Cerebral Artery: Clinical Features in 232 Patients. *BMC Research Notes* 4: 329, 2011.
4. Meier N, Fischer U, Schroth G, et al. Outcome after Thrombolysis for Acute Isolated Posterior Cerebral Artery Occlusion. *Cerebrovasc Dis* 32: 79– 88, 2011.
5. Nakamura K, Murata K, Kawakami T, et al. Percutaneous Transluminal Angioplasty for Stenosis of the Posterior Cerebral Artery in Progressive Stroke Case Report. *Neurol Med Chir (Tokyo)* 49: 351– 353, 2009.
6. van Houwelingen RC, Luijckx GJ, Mazuri A, et al. Safety and Outcome of Intra-Arterial Treatment for Basilar Artery Occlusion. *JAMA Neurol* 2016; 73(10):1225-1230.
7. Sarraj A, Sangha N, Hussain MS, et al. Endovascular Therapy for Acute Ischemic Stroke with Occlusion of the Middle Cerebral Artery M2 Segment. *JAMA Neurol* 2016; 73: 1291– 1296.