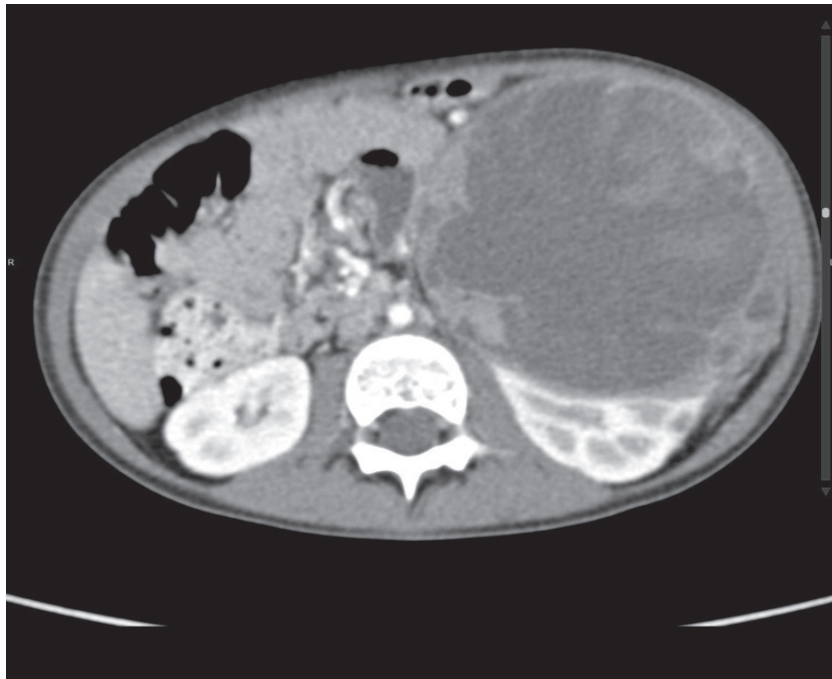


Medical Quiz

Saeed Alhindi, MD, CABS, FRCSI*

A three-year-old male presented with abdominal pain of 5 days of duration. This pain was associated with vomiting, fever and loss of appetite. Palpable mass was felt in the left upper quadrant. The patient had radiological investigations. Look at the figure below and answer the following questions.



- Q1. Mention the radiological test in the figure.
- Q2. Describe the findings in the figure.
- Q3. What is the diagnosis and management of this case?

Answers on page 286

* Assistant Professor, Arabian Gulf University
Consultant Pediatric Surgeon, Salmaniya Medical Complex
P.O. Box 12
Kingdom of Bahrain
E-mail: sjalhindi@yahoo.com, sjalhindi@gmail.com