

Post-adenotonsillectomy and Diffuse Large B-Cell Lymphoma

Dalal Burshaid, MBBCh, SSCP* Marwa Sameer BSc, MD** Shatha Hasan Mohamed, MD, MRCPCH*** Hiba Alreefy, AFRCS, FRCS-ORL HNS, CCT****

A one-year-and-10-month-old twin boy presented with a history of breathing difficulty which started two days after adenotonsillectomy. He clinically improved with nebulizer; however, two days later, his difficulty of breathing worsened and was associated with a runny nose, central cyanosis, snoring, apnea and reduced feeding and activity. MRI with contrast revealed a large extensive soft tissue mass involving the sinonasal tract.

Histopathological findings of the endoscopic biopsy were conclusive for Non-Hodgkin's lymphoma; diffuse large B cell lymphoma was confirmed.

Induction chemotherapy was given for two weeks. PET scan after the chemotherapy revealed that the patient was disease-free at the time of this report.

Bahrain Med Bull 2019; 41(4): 266 - 269

Non-Hodgkin's lymphoma (NHL) is considered the most common type of lymphoma diagnosed worldwide¹.

The most common type of sinonasal NHL is the large B cell lymphoma and it is primarily located in the nasal cavity and maxillary sinus¹. This type of lymphoma is most common in patients above the age of 60.

The aim of this report is to present a rare case of a boy who was diagnosed with Diffuse Large B Cell Lymphoma (DLBCL) at the age of 1 year and 10 months.

THE CASE

A one-year-and-10-month-old twin boy with a history of breathing difficulty which started two days post-adenotonsillectomy. He clinically improved with a nebulizer and was discharged accordingly. Two days later, his difficulty of breathing worsened and was associated with a runny nose, central cyanosis, snoring, apnea and reduced feeding and activity. The adenoidectomy was performed in a private hospital and the patient was transferred to our center for further management because of respiratory difficulty.

Past medical history was remarkable for recurrent episodes of breathing difficulty for which adenoidectomy was performed and a right-sided nasal mass was found. Physical examination revealed increased effort of breathing with intercostal recessions and increased respiratory rate. An episode of apnea was detected with a heart rate of 40 bpm.

He was electively intubated due to increased respiratory distress and generalized fatigue. Laryngoscopy was performed and revealed a nasopharyngeal mass.

MRI with contrast revealed a large extensive soft tissue mass involving the right maxillary sinus, sphenoid sinus, right nasal cavity extending to the floor and apex of the right orbital cavity superiorly, ethmoid sinus superomedial, soft palate inferiorly and masticator space laterally and the involvement of the adjacent bone and muscles. Infiltration of the cavities, sphenoid bone, right orbital cavity bony wall and lymph node involvement in the retropharyngeal space were found. A computed tomography (CT) of paranasal sinuses was performed, which confirmed the MRI findings, see figure 1.

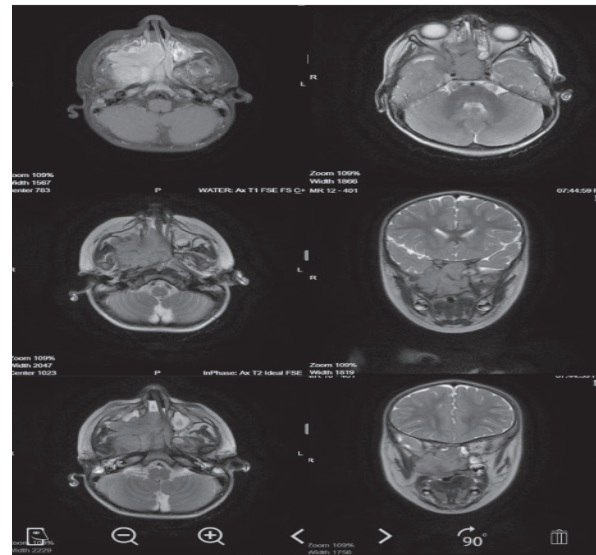


Figure 1: MRI Showing Large Extensive Soft Tissue Mass Involving Right Maxillary Sinus, Sphenoid Sinus, Right Nasal Cavity

* Registrar
** Senior House Officer
*** Consultant
Department of Pediatrics
**** Consultant and Head of Department
Department of ENT
King Hamad University Hospital
Kingdom of Bahrain
E-mail: dalal.burshaid@khuh.org.bh

The ophthalmological evaluation was performed and the initial examination revealed early right eye disc swelling.

An endoscopic biopsy was taken under general anesthesia, which revealed three pieces of tissue collectively measuring 12x10x6 mm, firm in consistency and tan in color with focal congested area. The histopathological evaluation revealed fragments of nasal tissue, infiltrated by a malignant cellular neoplasm and showing monotonous population of atypical cells with hyperchromatic nuclei and scanty cytoplasm. Immunohistochemical staining of cells was positive for CD45/CD19/CD20 with a proliferative index of 80%. These histopathological findings were conclusive for Non-Hodgkin lymphoma; diffuse large B cell lymphoma was confirmed.

Induction chemotherapy was given for two weeks. PET scan was performed after the chemotherapy and revealed that the patient was disease-free at the time of this report.

DISCUSSION

Lymphoma is a malignant disease affecting the immune system arising from the lymphocytes. There are two types of lymphomas: Hodgkins and Non-Hodgkins lymphoma².

In young children, Non-Hodgkins lymphoma is a very common malignancy compared to Hodgkin's lymphoma. However, both are considered the third most common cancer in pediatric age group³.

Non-Hodgkin's lymphoma is divided into three types. The most common is mature B-cell lymphoma, followed by lymphoblastic lymphoma, and anaplastic large cell lymphoma³. Mature B cell lymphoma is further subdivided into diffuse large B-cell lymphoma (DLBCL) and Burkitt lymphoma³.

NHL of the sinonasal tract is not a common malignancy; it accounts for 3% to 5% of all other malignancies⁴. However, it is considered the primary site of NHL in 90% of the cases with male predominance¹.

Several factors were found to contribute to B-cell lymphoma. Gene mutation, as well as EBV virus, can play a role in the diagnosis¹.

Patients with NHL present according to their histological types. Low-grade lymphoma usually presents with obstructive symptoms such as shortness of breath, wheezing, and high pitch breathing sounds¹. High-grade lymphoma presents more aggressively with non-healing ulcers and cranial nerve manifestations, facial swelling and has a tendency to involve orbital bones¹.

The gold standard diagnostic method is biopsy and histopathology, however, contrast CT scan/MRI/ PET scan are used for staging³.

The best treatment for DLBCL is chemotherapy. R-CHOP chemotherapy is a combination of 1 monoclonal antibody (rituximab), 3 chemotherapy agents (cyclophosphamide, doxorubicin, vincristine) and 1 steroid (prednisolone)¹⁻⁴.

Before 2018, there were only 36 reported cases with large B cell lymphoma in patients from 4 to 18 years old, most of them were males⁵. Furthermore, before 2015, only eight adult case reports and six adult cases within case series were reported in the literature to have large B cell lymphoma⁶. In April 2019, five cases were reported in Japan, and only one case was reported in China with nasal B cell lymphoma⁷.

CONCLUSION

DLBCL is considered the most common type of NHL in the world. Any mass in the nasocranial area should be investigated by contrast CT and biopsy.

Further study is advised to evaluate the link between B cell lymphoma and gene mutations.

Author Contribution: All authors share equal effort contribution towards (1) substantial contributions to conception and design, acquisition, analysis and interpretation of data; (2) drafting the article and revising it critically for important intellectual content; and (3) final approval of the manuscript version to be published. Yes.

Potential Conflicts of Interest: None.

Competing Interest: None.

Sponsorship: None.

Acceptance Date: 27 August 2019.

Ethical Approval: Approved by the Research and Ethics Committee, King Hamad University Hospital, Bahrain.

REFERENCES

- Zagolski O, Dwivedi C, Subramanian R, et al. Non-Hodgkin's Lymphoma of Sino-Nasal Tract in Children. *Journal of Cancer Research and Therapeutics* 2010; 6(1): 5-10.
- Abuaffan AH, Altayeb TM, Eltohami YI. Diffuse Large B cell Lymphoma: Case Report. *Journal of Otolaryngology-ENT Research* 2017; 8(6): 00268.
- Children's Hospital of Philadelphia. Non-Hodgkin Lymphoma in Children (2019). <https://www.chop.edu/conditions-diseases/non-hodgkin-lymphoma> Accessed on 18 May 2019.
- Atikah H, Hashimah I, Rosli M, et al. Burkitt's Lymphoma of Nasal Cavity and Bilateral Maxillary Sinuses. *Egyptian Journal of Ear, Nose, Throat and Allied Sciences* 2017; 18(2): 203-205.
- Chapman Wei, Chaplin Wei, Omar Alhalabi, et al. T-cell/Histiocyte-Rich Large B-cell Lymphoma in a Child: A Case Report and Review of Literature. *World J Clin Cases* 2018; 6(6): 121-126.
- Khan NR, Lakičević G, Callihan TR, et al. Diffuse Large B-Cell Lymphoma of the Frontal Sinus Presenting as a Pott Puffy Tumor: Case Report. *J Neurol Surg Rep* 2015; 76(1): e23-e27.
- Hao S, Sun Y, Hu C, et al. Primary Nasal Diffuse Large B-Cell Lymphoma with Synchronous Pulmonary Involvement: A Case Report. *Medicine (Baltimore)* 2019; 98(17):e15439.