

THERE are three principal types of Tattoo : Traumatic, Medical and Decorative.

Traumatic Tattoo is the accidental deposition of pigmented particles within the dermis. Carbon in the form of black spots is the most common material found imbedded in the dermis.

Medical Tattooing involves the deposition of pigments into the skin using sterile techniques and multiple minute punctures in order to conceal, replace or recreate a state that appears anatomically pigmented. Surgical Tattooing was first pioneered by Hance and Co-workers (1) in 1944, since that time it has been utilized on the cornea (To conceal leukomatous spots). In the recreation of the breast areola (following loss from burn or from trauma), and to cover skin blemishes particularly port wine stains (nevus flammeus).

Decorative tattooing consists of planned impregnation of fine particulate material into the skin to create an artistic design or pattern. This can be divided into two categories; professional (Figure 1a) practiced by artistically trained personnel and non-professional (Figure 2a). The latter have irregular, illdefined out-lines which are also thick and contain variable amounts of pigmentation. The designs are rather simple and they are usually placed on the distal portion of the extremities. Since 40-50 percent are self-inflicted and most people are right-handed, the majority of such tattoos are found on the arm or the left leg. The majority of tattooing is done when the subject is between 12 and 24 years of age, a time when there may be great emotional instability and when the need for identification with peer group is very strong (2) often these tattoos combine letters,

The Religious Aspects of Tattoo Excision

By Abdul Aziz Hamzah*

* Department of Surgery
Salmaniya Medical Centre

numbers, dots, and interposed lines In a symbolic pattern intended to be understood only by those in Group (Figure 1a & 2a).

It is usually in the mid of the late twenties that the individual finds the decorative tattoo a liability. It is at this point that social pressure and stigmata related to the tattoo becomes apparent to the individual, and the removal of the tattoo is sought.

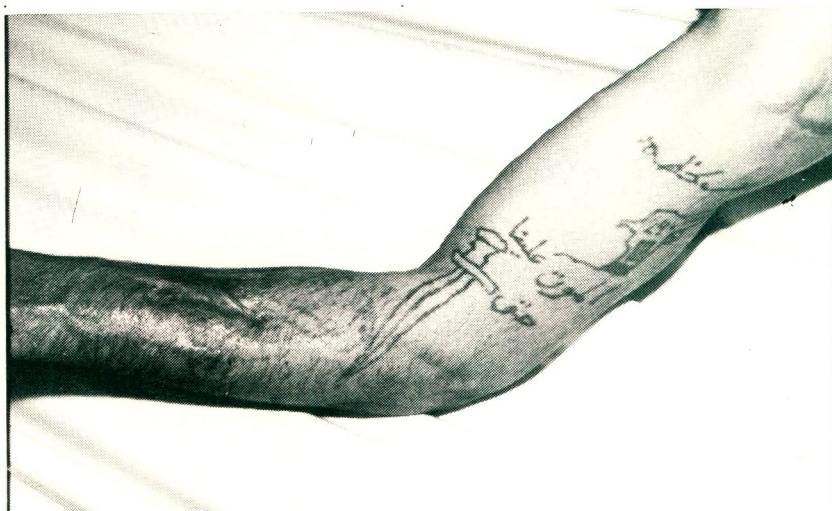

Figure 1a. :

Professional tattooing and scar of burn in the forearm after self attempt to remove it.

Figure 1b.:

Early post-operative view after excision and skin grafting.

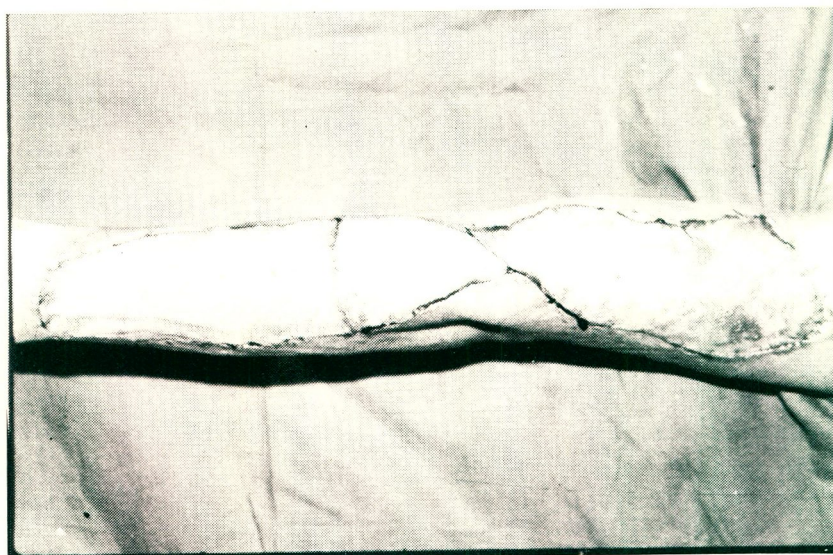

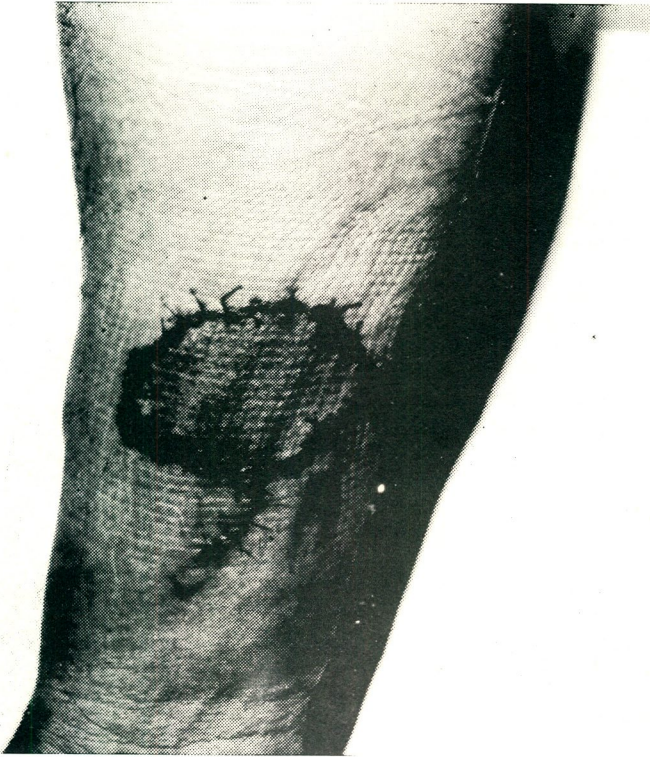
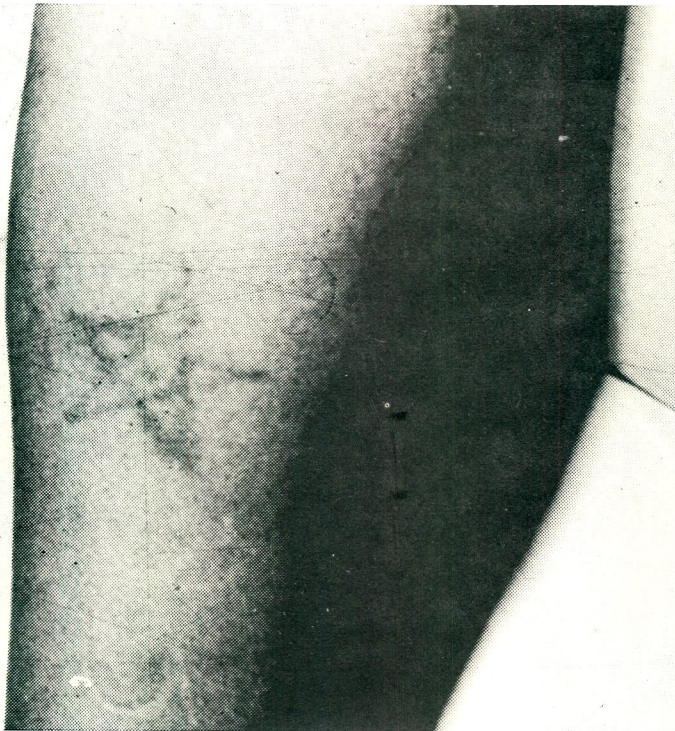

Figure 2a.:
Non-professional Tattooing

Figure 2b.:
Non-professional tattooing after excision and skin grafting.



Often such individuals have attempted to remove a portion of the tattoo themselves by burning (figure 1a) the area with a hot object or abrading the area with salt or sand paper, only to find the procedure painful and the scarring that results as objectionable as the tattoo itself.

REMOVAL OF DECORATIVE TATTOOS :

A wide variety of techniques have been described for the obliteration of decorative tattoos (3, 4, 5, 6).

No one techniques is completely satisfactory, and each case must be individualized.

It should be ascertained that it is the individual who wants his tattoo removed and not the parent, spouse, or close friend. The physician must also explain to the patient what the residual will be following removal.

Tattoos are removed by the following methods:-

1. Surgical Removal :

- A. Biopsy, punch method
- B. Direct Incision
- C. Multiple Excisions
- D. Excision and Flap transfer
- E. Excision and Grafting

2. Mechanical removal

- A. Pure dermabrasion (full thickness)
- B. Superficial Dermabrasion

3. Chemical Removal

4. Combination methods

- A. Mechanical and Chemical removal
- B. Surgical and Chemical removal

5. Superimposed tattooing or retattooing

6. Electrical removal

- A. Cautery
- B. Laser Beam
- C. Combination with chemical
- D. Combination with mechanical

ISLAM AND TATTOOING

During the period between September 1979 and June 1981 twelve tattoos were removed at Salmaniya Medical Center by excision and skin grafting (Figures 1-2). The age of individuals ranged between 20 and 40 years. In all cases the removal was the understanding that tattooing is against the religious practice of Islam.

ISLAMIC OUTLINES CAN BE QUOTED

1. As narrated by Imam Bukhari and Imam Muslim after IBN Umar, that prophet said Allah cursed who takes false hairs and who dresses others with false hairs, and who marks, herself with others with tattoos (7).

عن ابي عمر رضي الله عنه ، ان النبي
صلى الله عليه وسلم قال :
« لعن الله الواصلة والمستوصلة
والواشمة والمستوشمة »
- متفق عليه -

2. ABD Allah IBN Masoud reported that Allah cursed those who mark themselves with tattoos and who mark others with tattoos (8).

عن عبدالله بن مسعود رضي الله عنه
قال :
« لعن الله الواشمة والمستوشمة » •

REFERENCES :

1. Hance, G., Brown, J.B., Byars, L.T., and McDowell, F. : colour matching of skin grafts and flaps with permanent injection. Surg. gynecol and obstet. 70: 624, 1944.
2. Agric, J., Tattoos. Plastic surgery little, Brown and company Boston, U.S.A., page 559 — 566. 1979
3. Shie, M.J: The study of tattooing, a methods of its removal. J.A.M.A. 90: 94, 1928.
4. Agris, J. Tattoos In women, plast. reconstr. surg. 60: 22, 1977.
5. Manchester, G.H.: Tattoo Removal a new simple technique, Calif. Med. 18: 10, 1973.
6. McDowell, A.J., Brown, J.B., and Cannon, B.: Permanent pigment Injection of capillary hemangioma. Plast. reconstr. surg. 1: 106, 1946.
7. Al-Haj Maulana Fazlul Karim : Al-Hadis : An english translation and commentary of mishrat Al-Masabih. Published by the book house, Lahore, Pakistan. Volume I : Page 613, number 44.
8. Ibid., Number 45. □□