

MEDICAL QUIZ

Prepared By Salwa Al-Mahroos*

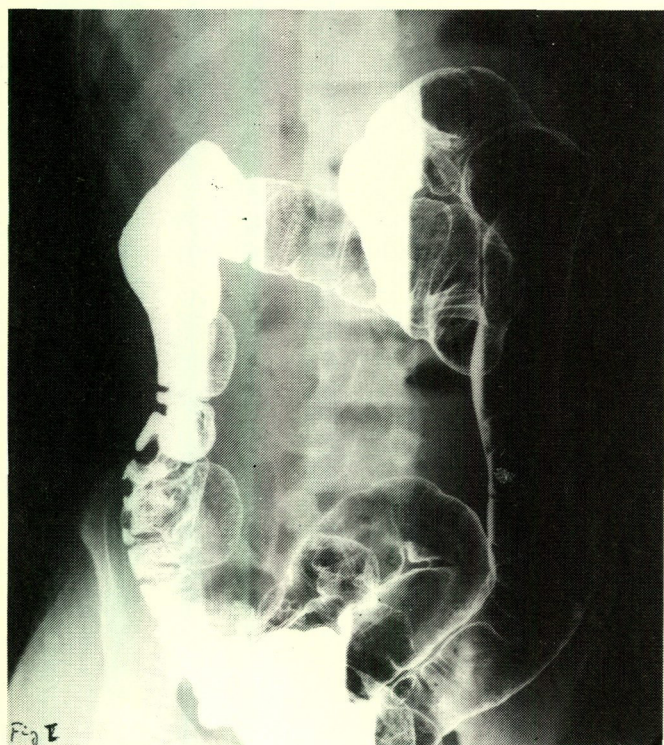

Figure 1

1. What is this investigation ?
2. What anatomical part is shown ?
3. What is the main pathology ?

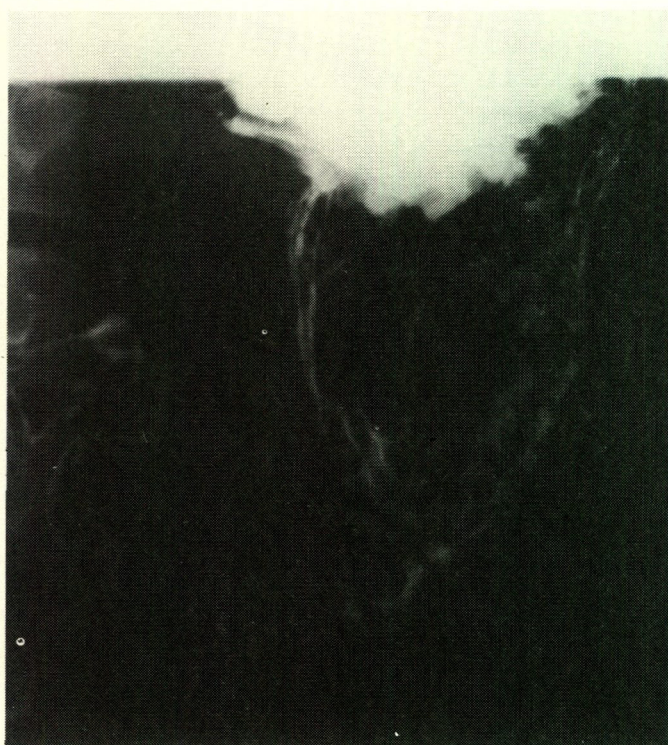

Figure 2

1. What is this investigation ?
2. What anatomical part is shown ?
3. What is the main pathology ?

* Consultant Physician
Salmaniya Medical Centre
State of Bahrain

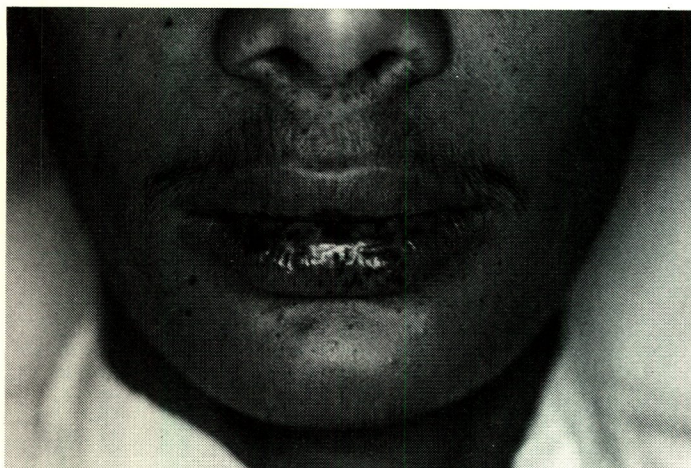


Figure 3

1. What is the lesion which can be seen on the lips ?

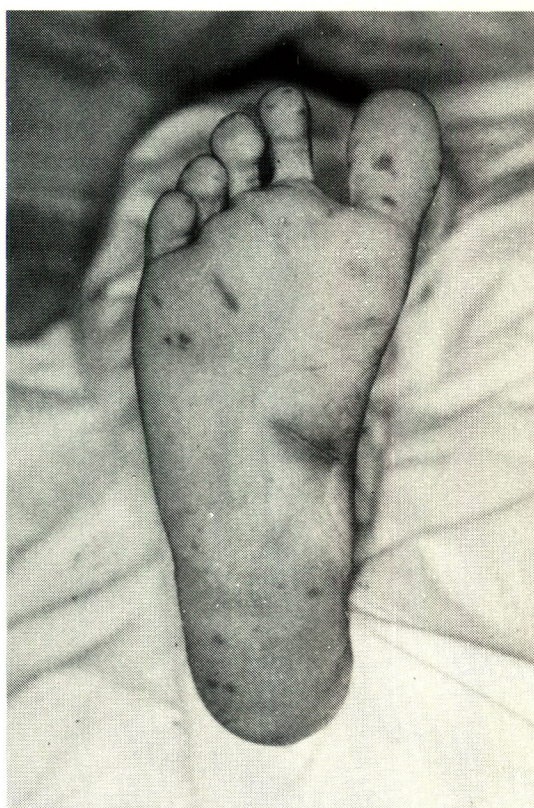

Figure 4

1. What is the lesion which can be seen on the sole of the foot ?

Do all these figures (1, 2, 3, 4) represent a syndrome that you know ?

Answers on page 154