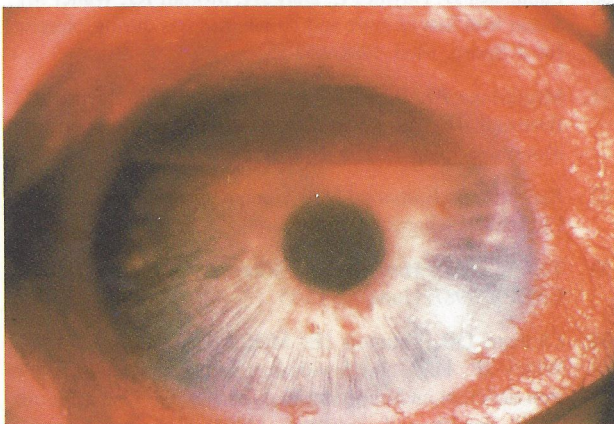


MEDICAL QUIZ

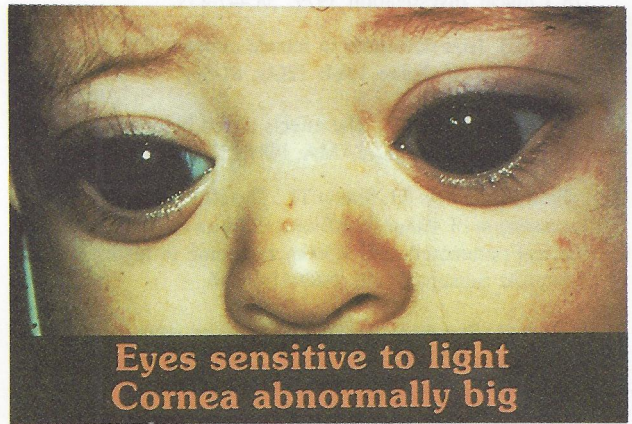
By Hassan H. Al-Arayed*



CASE I

A 31 year old Bahraini athlete sustained a severe blunt trauma to the eye by a football. Provided is a frontal photo of the eye. What is inside the eye?

1. Blood
2. Hyphema
3. Foreign body



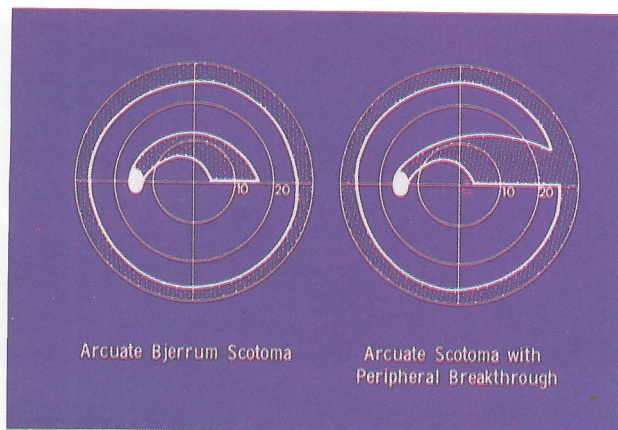
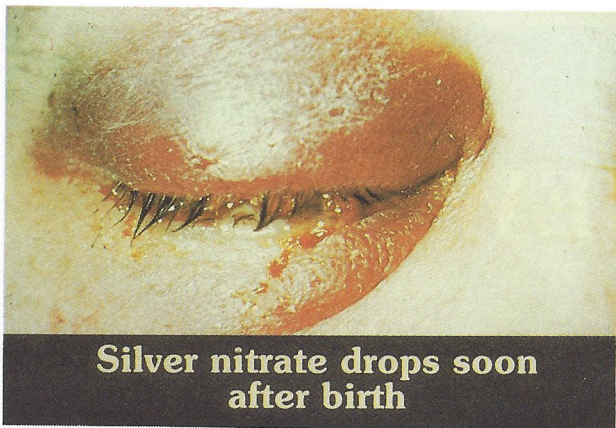
**Eyes sensitive to light
Cornea abnormally big**

CASE II

This is a photo of the eyes of a newborn. The corneae are abnormally big and hazy. There is also occasional watering, and the eyes are sensitive to light. What is your diagnosis?

1. Congenital obstruction Naso-lacrimal Duct
2. Megalocornea
3. Congenital glaucoma

* Chairman & Consultant
Ophthalmology Department
Salmaniya Medical Centre



CASE III

A one week old newborn with severe ophthalmia neonatorum. What is the most probable causative organism?

- 1. Streptococcus
- 2. Staphylococcus
- 3. Gonorrhoea

CASE IV

This is the visual field of a 50 year old Bahraini male with history of headache especially while reading. What is the diagnosis?

Answers on Page No. 160
