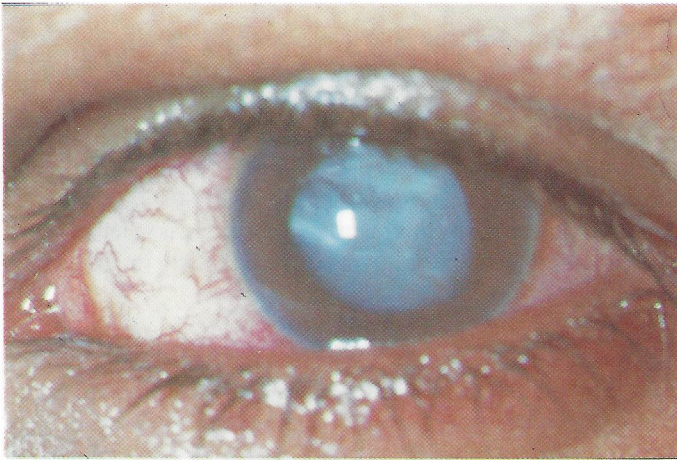


MEDICAL QUIZ

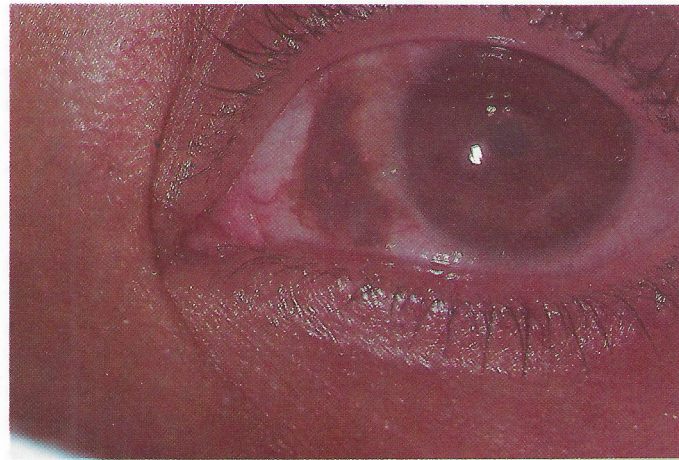Hassan Al Arrayed, MD, FRCS(Ed), FCOPTH
Pelın Kaynak, MD



CASE 1

A 30 year old Bahraini gentleman came with chief complaint of a lesion in the right eye of few years duration. Examination by slit lamp showed a pigmented lesion, irregular, well-delineated rather flat.

- Q1. What could be this lesion ?
- Q2. Is it malignant or benign ?



CASE 2

A young Bahraini labourer sustained a penetrating ocular injury. The photograph showing the eye with central opacity.

- Q1. What is the nature of the opacity ?
- Q2. After cataract extraction usually we advise optical correction. Which one is better: Intraocular implants or glasses ?

Answers on page 108