

Management of Alkali Eye Injury

Abdulla A. Almoosa, MD* Muhammad Atif Mian, FRCSEd**

Chemical eye injury is a common ophthalmic emergency which needs immediate aggressive management to maximize visual outcome. The outcome ranges from full recovery to permanent vision loss. Treatment includes medical and surgical interventions.

We present a case of an adult male who sustained a grade II alkali burn in his right eye after an accidental exposure to chemical powder while working. The patient was managed with preservative-free artificial tear drops, erythromycin eye ointment, moxifloxacin eye drops, Tobradex eye drops (tobramycin + dexamethasone 0.1%) and cyclopentolate eye drops. He recovered his vision fully and his cornea fully epithelized.

Bahrain Med Bull 2018; 40(2): 112 - 114

Chemical eye injuries could occur as a result of accidental exposure or criminal assault. It occurs with exposure to alkali or acidic agents, solvents and irritants in liquid, powder, solid or vapor form; alkali injuries are encountered more frequently¹⁻³.

Alkali burns are more severe than acidic burns because of their rapid penetrating effect through the cornea. Alkali agents cause saponification of fatty acids in the cell membrane with subsequent destruction of mucopolysaccharides at the same time; they enhance the collagenolysis process causing tissue necrosis and perforation. On the other hand, acidic agents precipitate tissue protein in which they create a barrier to further ocular penetration; an exception to this is hydrofluoric acid¹⁻³. Common causative agents in chemical eye injuries include¹: acids such as sulfuric acid, bleach and refrigerants, hydrochloric acid, acetic acid and hydrofluoric acid; alkali, such as ammonia, lye; lime, plaster and mortar, potassium hydroxide and magnesium hydroxide.

Chemical eye injuries are classified according to Roper-Hall classification system, which is based on the degree of corneal haze and limbal ischemia^{1,4}. The new "Dua classification" was based on clock hours of limbal ischemia in addition to the degree of conjunctival involvement^{1,5}. Both classifications are necessary to predict the prognosis of the patient.

The aim of this report is to present a case of an adult male who sustained a grade II alkali burn in his right eye after accidental exposure to chemical powder at work.

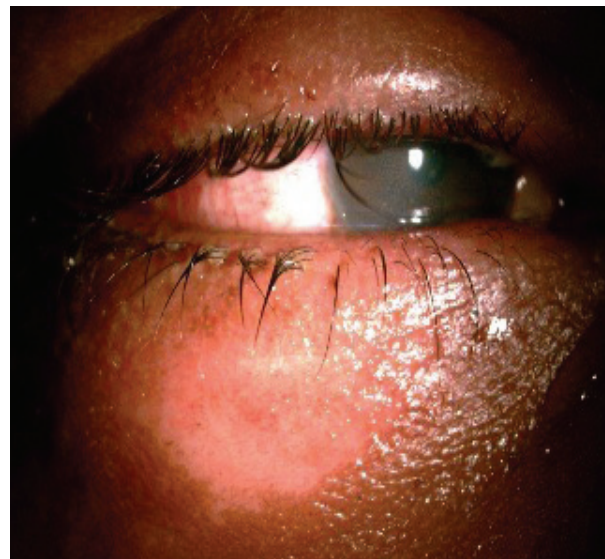THE CASE

A twenty-one-year-old chemical technician presented two hours after accidental exposure to caustic soda powder in his right eye; he had no known medical illnesses. Although the patient was wearing protective eyewear, a splash of powder managed to affect his right eye while trying to open one of the chemical bottles for inspection.

Irrigation of the right eye with four liters of normal saline was performed until the litmus test was negative. The right

nasolacrimal duct was also irrigated with one liter of normal saline.

The patient had pain and photophobia. His best-corrected visual acuity was 6/9 in the affected eye while 6/6 in the unaffected eye. Right eye examination revealed a lower lid grade I burn 20x10 mm with ulceration around the eyelashes, see figure 1 (A). Bulbar conjunctiva had a similar burn inferior to cornea measuring 15x9 mm. Limbal ischemia was from 5 to 7 o'clock position, see figure 1 (B). The cornea was hazy with visible iris details. There was a corneal epithelial loss from 4 to 11 o'clock position, extending a vertical line to the limbus, see figure 1 (C). The anterior chamber was deep and quiet, the lens was clear, there was hazy fundus view showing flat retina. The left eye had normal anterior and posterior chambers.



1 (A)

* Acting Registrar

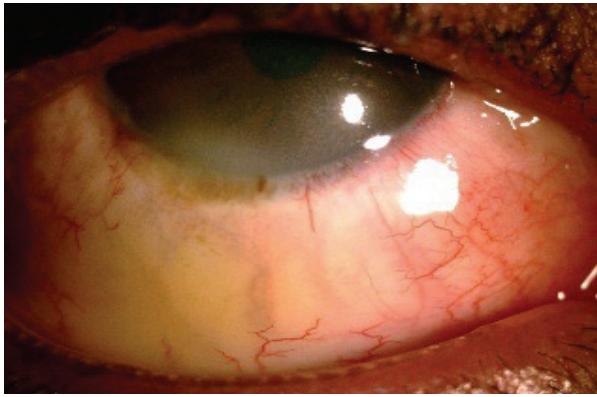
** Consultant

Department of Ophthalmology

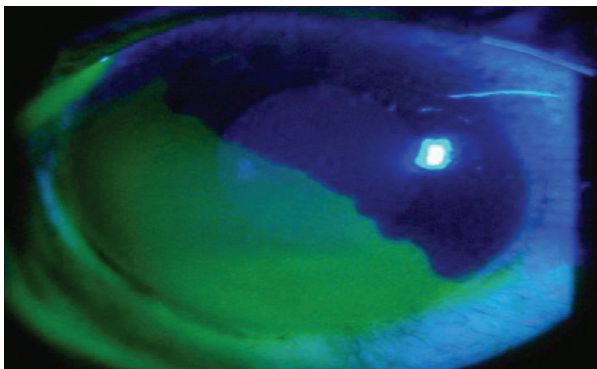
King Hamad University Hospital

Kingdom of Bahrain

E-mail: abdulla.almoosa@khuh.org.bh



1 (B)

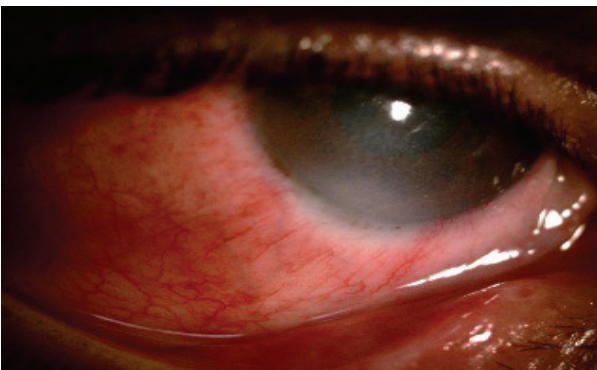
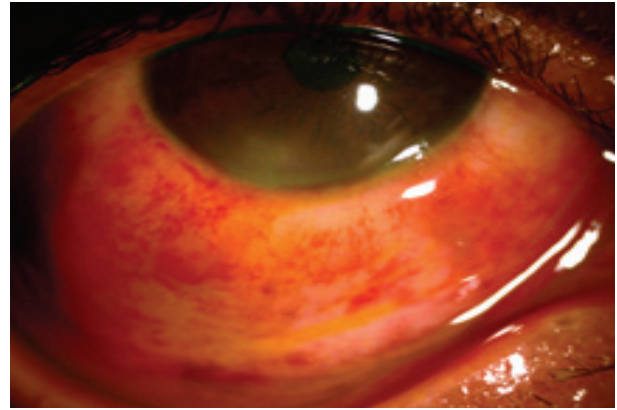



1 (C)

Figure 1 (A-C): First Day of Chemical Exposure

The patient was diagnosed with grade II alkali chemical eye injury. He was treated with preservative-free artificial tear drops every one hour, erythromycin eye ointment every two hours, moxifloxacin eye drops every four hours, Tobradex eye drops (tobramycin + dexamethasone 0.1%) every six hours and cyclopentolate eye drops every 8 hours.

On the second day of admission, the patient recovered 6/6 vision in the affected eye, and the limbal ischemia decreased in size by one clock hour from 6-7 o'clock position as seen in figure 2. The corneal defect decreased daily. On the third day, the limbal ischemia had disappeared completely, see figure 3. The patient was discharged after complete reversal of limbal ischemia and total corneal reepithelialization, see figure 4. He was discharged with the same treatment except for cyclopentolate, which was stopped on the third day. The patient was reviewed once after ten days; steroids were discontinued and other medications were tapered.

**Figure 2: Second Day Post-Chemical Exposure****Figure 3: Third Day Post-Chemical Exposure Showing Complete Reversal of Limbal Ischemia****Figure 4: Eighth Day Post-Chemical Exposure Showing Complete Corneal Reepithelialization**

DISCUSSION

MuCulley divided the clinical course of chemical eye injuries into four phases^{1,2,6}. Immediate phase (day 0): starts with the injury of the cornea, conjunctiva and corneal limbus. As epithelial stem cells are anatomically located in the limbus, the degree of limbal ischemia is a critical indicator of the prognostic outcome. Acute phase (day 0-7): inflammatory process and epithelial regrowth starts, therefore, the management is directed towards enhancing tissue reepithelialization and stabilizing the inflammation. Raised intraocular pressure (IOP) needs to be monitored. Early reparative phase (day 8-21): mild injury should be fully reepithelialized by this stage. The collagenases digesting enzyme activity peaks during the third week. On the other hand, the collagen synthesis enzyme and keratocytes proliferation continue; therefore, the treatment should enhance collagen synthesis for scarring formation and inhibit collagen breakdown to prevent corneal melting by subsiding collagenase enzyme. Late reparative phase (after day 21): mild injuries would be fully healed with good prognosis. Severe injuries may end up with complications which could not be managed further medically, such as corneal scarring and neovascularization, eye dryness, symblepharon formation, secondary glaucoma, secondary cataract, eyelid entropion or ectropion.

According to the pathophysiology of chemical eye injury, as described by MuCcully, clinical management has improved. The management is divided into three stages: emergency phase, acute phase and late phase^{1,3,7,9}. Emergency Phase Management depends on early copious irrigation until the pH is neutralized. Acute phase management focuses on promoting

reepithelialization, augmenting collagen synthesis, collagenase inhibition, preventing superinfection, inflammation control, pain relief, treating high intraocular pressure and preventing symblepharon formation. Various surgical options are available for the late phase management: amniotic membrane grafts, conjunctival/tenons advancement, limbal stem cell transplant and penetrating keratoplasty or permanent Boston keratoprosthesis implantation.

Most chemical injuries are occupational; industrial workers who deal with chemical materials must be educated on the safety precautions when using chemicals and the importance of wearing protective gear at the workplace. Emergency eyewash bottles, first aid kits and/or sinks at reachable stations must be provided by the industry wherever chemicals are used. Workers must learn how to handle situations involving chemical exposure and must be educated on the importance of immediate irrigation at the scene; the earlier the irrigation is started, even with tap water, the better the outcome could be¹⁰.

CONCLUSION

Chemical eye injuries must be treated aggressively to achieve the best outcome. Irrigation must not be delayed. Irrigation is considered to be the most important step in management. Steroid usage in ocular chemical burn should be used initially; however, it still should be used with caution, and patients who are under steroid drops should be under close observation. Using safety equipment will reduce the incidence of severe injuries and will result in a better visual outcome.

Author Contribution: All authors share equal effort contribution towards (1) substantial contribution to conception and design, acquisition, analysis and interpretation of data; (2) drafting the article and revising it critically for important intellectual content; and (3) final approval of manuscript version to be published. Yes.

Potential Conflicts of Interest: None.

Competing Interest: None.

Sponsorship: None.

Acceptance Date: 21 April 2018.

Ethical Approval: Approved by the Research and Ethics Committee, King Hamad University Hospital, Bahrain.

REFERENCES

1. Singh P, Tyagi M, Kumar Y, et al. Ocular Chemical Injuries and their Management. *Oman J Ophthalmol* 2013; 6(2): 83–86.
2. Eslani M, Baradaran-Rafii A, Movahedan A, et al. The Ocular Surface Chemical Burns. *J Ophthalmol* 2014; 2014:196827.
3. Ikeda N, Hayasaka S, Hayasaka Y, et al. Alkali Burns of the Eye: Effect of Immediate Copious Irrigation with Tap Water on Their Severity. *Ophthalmologica* 2006; 220(4):225-8.
4. Gupta N, Kalaivani M, Tandon R. Comparison of Prognostic Value of Roper Hall and Dua Classification Systems in Acute Ocular Burns. *Br J Ophthalmol* 2011; 95(2):194-8.
5. Dua HS, AJ King, Joseph A. A New Classification of Ocular Surface Burns. *The British Journal of Ophthalmology* 2001; 85(11): 1379-83.
6. McCulley JP. Chemical Injuries. In: Smolin G, Thoft RA, Eds. *The Cornea: Scientific Foundation and Clinical Practice*. Boston: Little Brown and Co, 1987; 527–42.
7. Colby K. Chemical Injuries of the Cornea. *Focal Points in American Academy of Ophthalmology* 2010; 28(1):1-14.
8. Chemical Injuries of the Cornea: Management Strategies. *American Academy of Ophthalmology*. <https://www.aaopt.org/focalpointssnippetdetail.aspx?id=e323160e-b88b-4c90-b649-3225aa76643b> Accessed on 10 February 2016.
9. Panda A, Jain M, Vanathi M, et al. Topical Autologous Platelet-Rich Plasma Eyedrops for Acute Corneal Chemical Injury. *Cornea* 2012; 31(9):989-93.
10. Eye Injuries - Chemical Burns. <https://www.betterhealth.vic.gov.au/health/conditionsandtreatments/eye-injuries-chemical-burns> Accessed on 10 February 2016.