

Medical Quiz

Saeed Alhindi, MD, CABS, FRCSI

A twenty-three-year-old male presented with scrotal swelling increasing in size for one month. No history of fever or trauma. Physical examination revealed a non-tender mass on the left side of the scrotum. The patient underwent radiological investigations. Look at the figures below and answer the following questions:

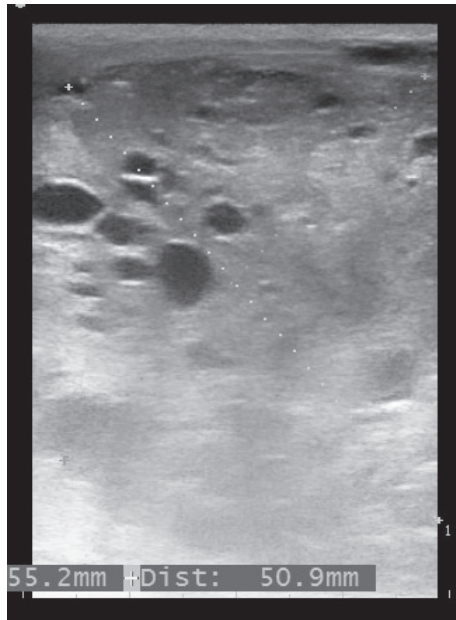


Figure 1

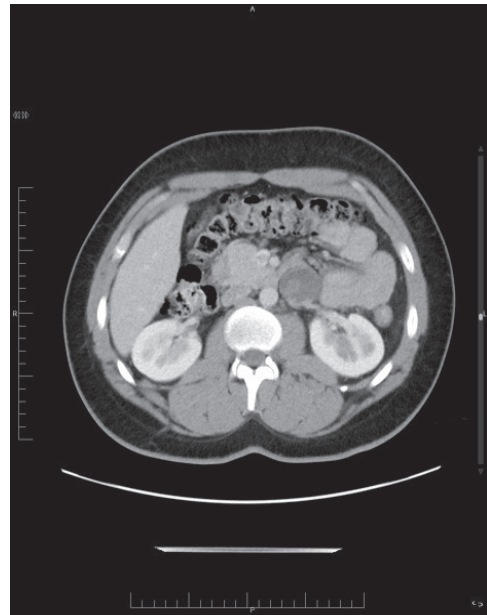


Figure 2

- Q1. Mention the radiological test in figure 1 and figure 2.
- Q2. Describe the findings in the figures.
- Q3. What are the diagnosis and initial management of this case?

Answers on page 161

* Assistant Professor, Arabian Gulf University
Consultant Pediatric Surgeon, Salmaniya Medical Complex
P.O. Box 12
Kingdom of Bahrain
E-mail: sjalhindi@yahoo.com, sjalhindi@gmail.com