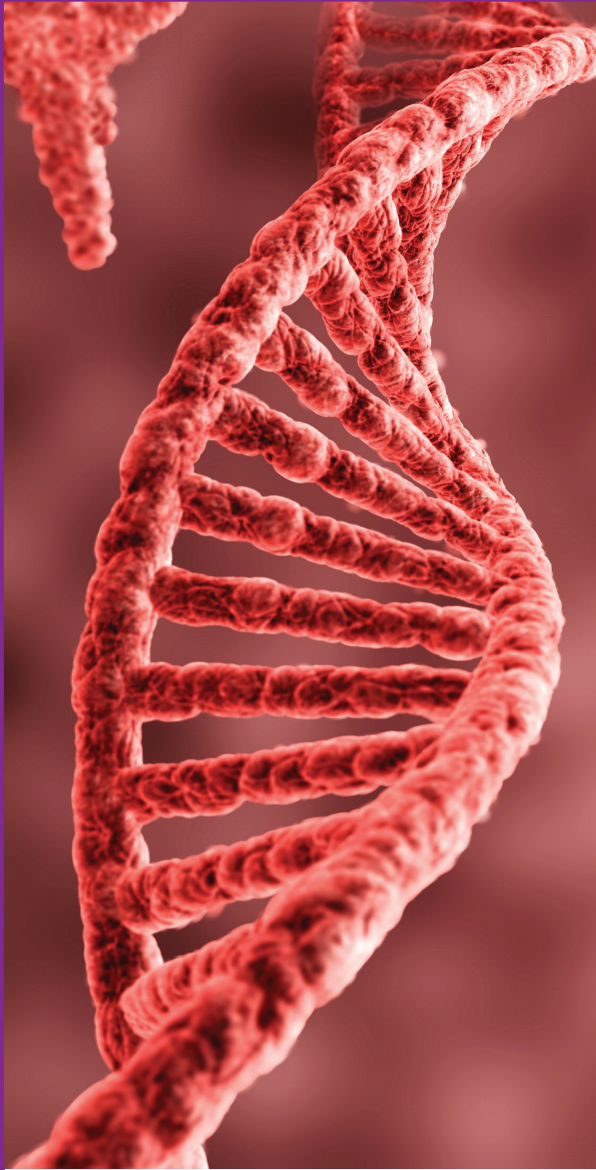




BAHRAIN MEDICAL BULLETIN



ORIGINAL

Outcomes of Surgery for Adolescent Idiopathic Scoliosis (AIS)
Yusuf Omran, Badryia Toorani, Youssry M. K. El-Havary

Histopathological Characteristics of Mediastinal Tumors through 11 Years
Muneera Al-Khalifa, Sara Alsaad, Aishah Al-Kulaib, Muzoon Al-Muawda, Habib Al-Tareef, Abdulla Darwish

Clinical Presentation, Culture and Sensitivity Pattern of Urinary Tract Infection in Patients
Feras Husain Abuzeyad, Muhammad Kashif Ashraf, Appas Ebrahim, Saleem Ullah, Muhammad Usman Yaqub, Muhammad Shoaib, Salah Farahat Alam

Diabetes Care and Outcomes
Mahmood Alawainati, Habib Abdulla, Hussain Taha Abdulwahab Radhi, Ahmed Husain, Fatema Kayed, Sara Naser

Does Elevated White Blood Cell (WBC) Count Aid in the Diagnosis of Acute Appendicitis?
Ali Alhawaj

Randomly Selected Smear Test Screening Outcome
Bessy Varghese, Mariam Tamimi, Abida Qureshi, Nawal Dayoub

Diverticular Disease: Risk Factors and Predictors of the Outcome
Islam Omar, Hani Alsaati, Hala Kalaji, Raneem El-Jabri, Abeer Malalla

Evaluation of Dry Eye after Cataract Surgery
Mouna M. Al Saad, Amin B. Shehadeh, Saif Aldeen S. Al Ryalat, Ahmad Al Amer, Hiba Mihar

The Impact of the Open-Access Ophthalmology Journals Status on Journal Indices
Saif Aldeen AlRyalat, Mouna Al Saad, Ahmed Al Amer, Siraj Mohammad Saleem, Mohammad Madi Ahmad, Hamad Alrashidi, Fayez Alazmi, Yousef Mallah, Hussain Dashti, Eid Albuainain, Alaa Abed

Effect of Booking Status on Mode of Delivery and Postnatal Maternal Outcome
Danyal Qureshi, Rawan Abduljalil, Aysha Nabeel Nadham, Abeer AlSada, Abida Qureshi, Nawal Dayoub

MEDICAL QUIZ

Saeed Alhindi

EDUCATION-FAMILY PHYSICIAN CORNER

Huntington Disease with Psychiatric Presentation
Shahla A. Karim, Feras Al Saif

CASE PRESENTATION

Postoperative Free Air is Not Always Normal! Necrotizing Enterocolitis Leading to Concurrent Colonic and Gastric Perforation
Batool Abdulla Almoallem, Hind Zaidan, Hussein Ahmed, Martin T. Corbally

Massive Optic Disc Edema with Central Retinal Vein Occlusion Post In-Vitro Fertilization
Seemantini Ayachit, Saad A. S. Al Khalifa, Sayed Mohamed Al Saffar

An Infant with a Severe Combined Immunodeficiency Caused by Zeta Chain-Associated Protein 70 (ZAP-70) Deficiency
Mohamed Al-Shaikh, Abdulla Ali Isa, Maryam Fuad Ali, Hasan M. Isa

Awake Fiberoptic Intubation in a Patient with Lingual Hematoma
Saqib Hussain Khan, Priti Narayan, Vishal Shah

Sanjad Sakati Syndrome
Husain Y. Ahmed, Fatema M. Almeshkhas, Zahra A. Hasan, Hasan M. Isa

Congenital Goiter, Is it a Medical or Surgical Disease?
Marwa A. Mohamed, Mai A. Nasser, Haya M. Al Khayyat, Mohammed H. Al Shehabi

Negative Pressure Pulmonary Edema Post-Appendicectomy
Ali Al Bshabshe, Tarique Ashraf, Sara Hadi, Muhamad Abid Khan, Yahya Ayed Al Garni

Hemophagocytic Lymphohistiocytosis (HLH) with History of Kawasaki's Disease (KD)
Omar E. Alalawi, Salman M. Al-Khalifa

Ketamine Induced Generalized Convulsive Seizure in a Healthy 6-Year-Old Male Undergoing Procedural Sedation
Moza Al Noaimi, Shaibaz Hussain, Ghada Al Qassim

Rheumatoid Arthritis-Associated Swan Neck Deformity Improved with Adalimumab Therapy
Zahra Sayed, Adla B. Hassan

TALENT IN MEDICINE

1. Deep Sleep!
 2. O My!
- Anil Kumar Chawla*



Volume 42 Number 1

March 2020

<http://www.bahrainmedicalbulletin.com>

ISSN 1012-8298
US NLM ID 8503052