

## Virgin Female with Undetected Cervical Fibroid

Hasan Isa Almajed, MBBCh\* Hasan Ali Radhi, MBBCh\*\*  
Zainab Aljufairi, MHPE, FRCOG\*\*\*

**A virgin female in her early forty presented with heavy menstrual bleeding (HMB). She had a long history of HMB and intermenstrual bleeding (IMB) which required recurrent admissions for the past 6 years. The patient had a history of irregular periods for 12 days. The patient reported abdominal pain. Per vaginal and speculum examination and endometrial biopsy were not performed due to patient's refusal to maintain intact hymen. Subsequent ultrasound imaging was unremarkable. CT scan suggested cervical mass (fibroid) with hyaline degeneration and foci of calcification and no evidence of malignancy. The fibroid was resected. Histopathology report showed features compatible with leiomyoma with hyaline degeneration and foci of calcification. Postoperatively, the patient had uneventful hospital course.**

*Bahrain Med Bull 2019; 41(1): 42 - 44*

Cervical fibroids are not common, they account for about 1-2% of all leiomyomas<sup>1</sup>. Cervical fibroid develops usually in the supra-vaginal part of the cervix<sup>2</sup>. The most common presentations are retention of urine, menstrual abnormalities, constipation, asymptomatic abdominal mass and may mimic an ovarian tumor<sup>3</sup>.

The aim of this report is to present a case of cervical fibroids with Abnormal Uterine Bleeding (AUB) and refusal of proper examination due to societal norms and cultural beliefs.

### THE CASE

A forty-year-old unmarried virgin Bahraini female presented with a history of heavy menstrual bleeding (HMB), palpitation, shortness of breath, tinnitus, dizziness and mild abdominal pain for three days. She had a long history of HMB and intermenstrual bleeding (IMB) that required recurrent admissions for blood transfusion, treatment, and investigations in the past 6 years. The patient had history of irregular periods for 12 days (2-3 days of mild flow then continuous heavy bleeding), history of secondary dysmenorrhea and IBM. Her menarche was at the age of 13 years. She had history of an excision of fibroepithelial polyp with lipomatous stroma from the leg. There was no family history of endometrial cancer or other gynecological malignancies.

On examination, the patient was alert, conscious and pale. She was morbidly obese with BMI 49.5 and vitally stable. Chest examination revealed equal air entry bilaterally and the cardiovascular system was normal. The abdomen was soft, lax, non-tender with no palpable masses. She declined vaginal and speculum examinations and endometrial biopsy under general

anesthesia as she was concerned about her virginity. The patient was admitted several times to the hospital for the same reason and refused invasive measures that may affect the integrity of the hymen. The patient was treated with tranexamic acid 1 g QID, Norethisterone 10 mg PO BID for 21 days and several courses of Zoladex (Goserelin) to control her unexplained bleeding but with no improvement in the last 6 years.

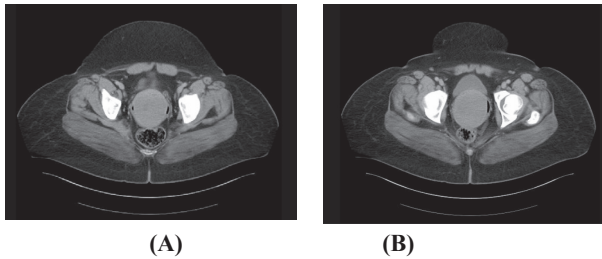
Hemoglobin was 6.5 g/dL. Coagulation profile, iron studies, folic acid, vitamin B12, TSH, prolactin, FSH, LH,  $\beta$ -hCG, progesterone and estrogen were normal. Pelvic ultrasound was difficult due to obesity, but the report was unremarkable with uterine measurement 9.4x4.8x5.1 cm. Transvaginal ultrasound was refused by the patient. She had CT scan of the pelvis on her last admission which revealed that the uterus and both ovaries were normal. The cervix was enlarged measuring 6.1x7.3 cm and appeared homogeneous in density with peripheral air suggestive of either polyp, fibroid or cervical lesion extending to the vagina, see figure 1. There was no calcification, no invasion of the adjacent structures, no pericervical fat stranding or lymphadenopathy and no bony suspicious lesions.

The patient was offered examination under anesthesia but she refused. She was readmitted for another episode of heavy bleeding and agreed to the examination, which showed a large posterior cervical lip sessile fibroid 10x7 cm. The uterus was anteverted, mobile and normal in size. The excision of the cervical fibroid was a challenge due to its sessile shape and large size, obesity and intact hymen. The fibroid was resected in pieces by traction with tenaculum and cutting diathermy. Dilatation and curettage were performed and no tissue was obtained. Histopathology report showed fragmented masses with lobulated surface weighing 198 g and the cut section

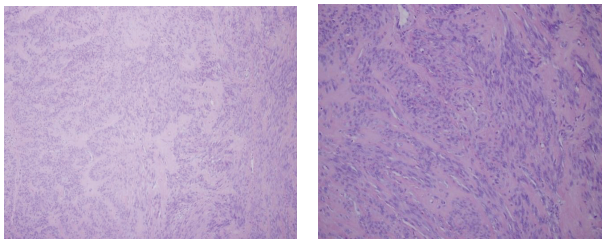
---

\* General Practitioner  
Clinical Attachment  
\*\* General Practitioner  
\*\*\* Senior Consultant  
Obstetrics and Gynecology Department  
Salmaniya Medical Complex  
Kingdom of Bahrain  
E-mail: hnmajed@gmail.com

revealed homogenous whorled appearance with brownish areas within. Microscopic features were compatible with leiomyoma with hyaline degeneration and foci of calcification, see figure 2. Postoperatively, the patient had uneventful hospital course.



**Figure 1 (A & B): The Cervix is Enlarged and Measuring About 6.1x7.3 cm. It Appears Homogeneous in Density Peripheral Air Suggesting Polyp/Fibroid/Mass Lesion Extending to the Vagina**



**(A) Power 10**

**(B) Power 20**

**Figure 2 (A-B): Fascicular Pattern of Smooth Muscle Bundles Proliferation towards the Periphery with Hyaline Degeneration. Scattered Focal Lymphocytes and Plasma Cell Infiltration with Focal Mast Cells Sprinkling**

## DISCUSSION

Investigation and management of AUB among non-gravid women is confusing and challenging due to the lack of categorization and deficiency of standardized. International Federation of Gynecology and Obstetrics (FIGO) in 2011 presented the new classification system for AUB, taking in consideration that the system must be universal, practical for everyone (clinician, researchers, and patients) and acknowledging all the causes with the probability of coexistence of multiple causes. In the proposed classification system, the term menorrhagia and metrorrhagia were discarded and replaced by HMB and IMB respectively and the term dysfunctional uterine bleeding (DUB) was discarded while the term AUB was accepted as the term suitable for disturbed menstrual bleeding<sup>4-6</sup>. The new classification system acronym is PALM-COEIN (Polyp; Adenomyosis, Leiomyoma, Malignancy and hyperplasia, Coagulopathy, Ovulatory dysfunction, Endometrial latorgenic, Not yet classified). The first group PALM can be diagnosed by imaging or histopathology, while the diagnosis of the second group COEIN is variable with each disease.

Persistent AUB that is unexplained or not adequately treated requires endometrial sampling and if possible in association with hysteroscopy evaluation of the uterine cavity to rule out cervical or endometrial polyp, endometrial hyperplasia or malignancy. Our patient had a long history of AUB and

was initially diagnosed as ovulatory dysfunction as she was morbidly obese and all initial investigations were normal. She declined vaginal examination, endometrial biopsy as she was concerned about her virginity.

Cervical fibroid is very rare and most of the cases were described during pregnancy<sup>7</sup>. In some cases, it increases in size significantly which leads to recurrent and heavy vaginal bleeding mandating frequent blood transfusion<sup>8,9</sup>. Proper examination facilitates early detection of the fibroid and can prevent unnecessary events. Compromising the doctors' investigative methods by culture and norms can be harmful to the patient and may increase morbidity and mortality. Cervical fibroid previously has been reported in a few different clinical circumstances; however, it has not been reported in patients with an intact hymen.

## CONCLUSION

**Investigating and diagnosing AUB needs a proper systematic approach to reach the final diagnosis. The recent FIGO system established a new universal systematic way in distinguishing different causes of AUB. However, without patient's cooperation diagnosis, management of AUB will be delayed.**

**Author Contribution:** All authors share equal effort contribution towards (1) substantial contributions to conception and design, acquisition, analysis and interpretation of data; (2) drafting the article and revising it critically for important intellectual content; and (3) final approval of the manuscript version to be published. Yes.

**Potential Conflicts of Interest:** None.

**Competing Interest:** None.

**Sponsorship:** None.

**Acceptance Date:** 15 January 2019.

**Ethical Approval:** Approved by the Obstetrics and Gynecology Department, Salmaniya Medical Complex, Bahrain.

## REFERENCES

1. Bhatla N. Tumours of the Corpus Uteri. In: Jeffcoates Principles of Gynecology. 8th ed. Jaypee Brothers Medical Publishers, 2014: 461.
2. Suneja A, Taneja A, Guleria K, et al. Incarcerated Procidientia due to Cervical Fibroid: An Unusual Presentation. Aust N Z J Obstet Gynaecol 2003; 43:252-25.
3. Munro MG, Critchley HO, Broder MS, et al. FIGO Classification System (PALM-COEIN) for Causes of Abnormal Uterine Bleeding in Nongravid Women of Reproductive Age. Int J Gynaecol Obstet 2011; 113(1):3-13.
4. Fraser IS, Critchley HO, Munro MG, et al. A Process Designed to Lead to International Agreement on Terminologies and Definitions Used to Describe Abnormalities of Menstrual Bleeding. Fertil Steril 2007;87(3):466-76.

5. Fraser IS, Critchley HO, Munro MG, et al. Can We Achieve International Agreement on Terminologies and Definitions Used to Describe Abnormalities of Menstrual Bleeding? *Hum Reprod* 2007; 22(3):635–43.
6. Donnez J, Dolmans MM. Uterine Fibroid Management: From the Present to the Future. *Human Reproduction Update* 2016; 22(6): 665-686.
7. Karan S, Djavid A. Fibroids in Pregnancy: Management and Outcomes. *The Obstetrician & Gynaecologist* 2018; 20(3):187-195.
8. Keriakos R, Maher M. Management of Cervical Fibroid during the Reproductive Period. *Obstetrics and Gynecology* 2013; (2013).
9. Davis BJ, Haneke KE, Miner K, et al. The Fibroid Growth Study: Determinants of Therapeutic Intervention. *J Womens Health (Larchmt)* 2009; 18(5):725–32.