

## Unilateral Proptosis as Presentation of Fungal Sinusitis

Mohamed Naeem Nasir, FRCS\* Mohamed Abdulnoor, MBCh\*\* Ahmed Asal, MD\*\*  
Sarah Al Baridi, MD\*\*\* Layan Al Bassam, MD\*\*\*

**Proptosis is a very common manifestation of orbital and sinus pathology. Careful attention for the cause and precise diagnosis is essential for the favorable outcome.**

**In this report, we present a seventeen-year-old female with painless proptosis of the left eye associated with irritation in the eye and nasal blockage. The patient was treated with Cefuroxime 500 mg every 12 hours orally with otrivin nasal spray three times daily and Zantac 150 mg at bedtime orally. Fungal infection was confirmed by histopathological examination of the material. Microbiology fungal culture and sensitivity revealed candida species growth. Functional endoscopic sinus surgery was performed under general anesthesia and the patient was discharged in stable condition.**

*Bahrain Med Bull 2019; 41(1): 51 - 52*

Proptosis is a very common manifestation of diseases involving the orbit where fungal sinusitis account for only 15.9%<sup>1</sup>. Overall, 7% of patients who have chronic sinusitis will have allergic fungal sinusitis<sup>2</sup>. Immunocompetent patients with chronic sinusitis develop a non-invasive hypersensitivity response to extramucosal fungi found within the sinuses<sup>3</sup>. The presentation of proptosis is of significant importance as it may reflect the cause and in some cases could be the only manifestation of paranasal sinus pathology<sup>1,4</sup>.

The aim of this report is to present the management of eye proptosis case secondary to chronic reactive fungal sinusitis in an immunocompetent patient.

### THE CASE

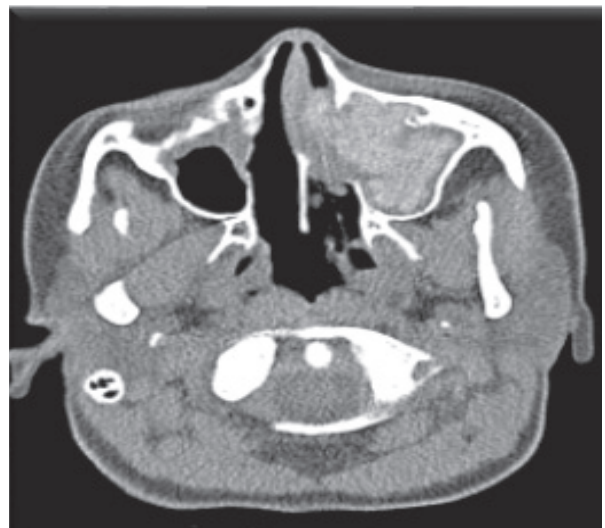
A seventeen-year-old Bahraini female presented with a two-week history of painless proptosis of the left globe associated with irritation and nasal blockage, see figure 1.

She is a known case of bronchial asthma and was using a nebulizer as needed and has no other medical comorbidities. The proptosis was recently developed. A plastic ruler used to compare both eyes revealed asymmetry of more than 2 mm in favor of left eye proptosis. On examination, the patient was afebrile with fully intact sensorium; left globe was displaced outward and superiorly with visual acuity of 6/6 unaided in both eyes and normal intraocular pressure of 14 mmHg. The proptosis was non-reducible and non-pulsatile with white uncongested conjunctiva and clear cornea. The anterior chamber was deep and quiet with a normal reactive pupil and no afferent relative pupillary defect. Dilated fundus examination revealed that the retina was flat with normal vascularity and cup to disc ratio of 0.3 with clear margins of the optic nerve. Rigid rhinoscopy examination revealed pale nasal mass posteroinferior to middle turbinate and arising from the lateral nasal wall.



**Figure 1: Prominent Left Eye Proptosis as Indicated by the Scleral Show**

Complete blood count, electrolytes, thyroid stimulating hormone, erythrocyte sedimentation rate and C-reactive protein were within normal. In addition, CT scan revealed the following findings: complete opacification of nasal passages, left side frontal, maxillary and sphenoidal sinuses filled with hyperdense soft tissue material causing mass effect on left medial rectus muscle and pushing the intraocular content, see figure 2.

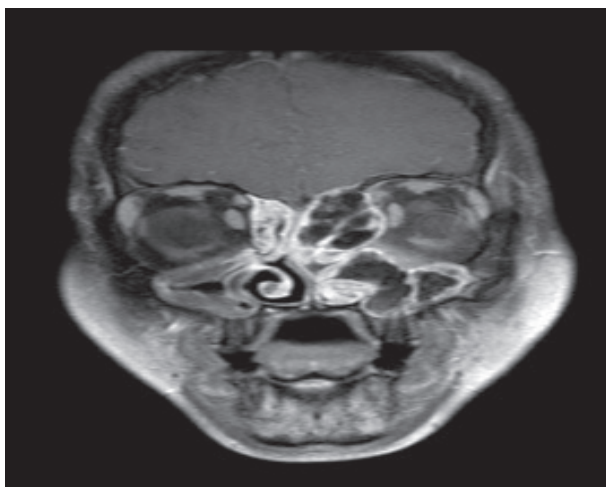


**Figure 2: Complete Opacification of Left Nasal Passage and Sinuses Filled with Hyperdense Soft Tissue Material Causing Mass Effect on Left Medial Rectus Muscle and Pushing the Intraocular Content**

The patient was treated with Cefuroxime 500 mg every 12 hours orally, otrivin nasal spray three times daily and Zantac 150 mg at bedtime orally. MRI revealed significant thinning of lamina papyracea with bulging into left orbit along medial wall indenting medial rectus muscle; however, there was no definite evidence of a breach of the bony wall or extension of soft tissue within the orbit, see figure 3. The optic nerve was unremarkable and seen throughout its intraorbital and intracranial segment

\* Head of Ophthalmology Department  
\*\* Resident  
\*\*\* Medical Student  
Department of Ophthalmology  
Salmaniya Medical Complex  
Kingdom of Bahrain  
E-mail: dr-ahmed-asal@hotmail.com

clearly. Hypointense growth obliterating left nasal cavity filling adjacent sinuses could be seen. A focal meningeal enhancement in the left side was suggestive of fungal infection that was confirmed by histopathological examination of the material. Fungal culture and sensitivity revealed candida species growth. Functional endoscopic sinus surgery was performed under general anesthesia and the patient was discharged in stable condition. Three months postoperatively, the patient had no complaints and had a normal nasal passage and clear throat.



**Figure 3: MRI Image Showing Significant Thinning of Lamina Papyracea with Bulging into Left Orbit along Medial Wall**

## DISCUSSION

In this case, the proptosis was outward and upward; the differential diagnoses could be carcinoma of maxillary antrum, carcinoma of the ethmoid and nasopharyngeal tumor. On the other hand, unilateral proptosis can be a presentation of a developmental anomaly, inflammatory conditions and endocrinological disorders, such as Graves' disease.

The primary cause was a chronic fungal infection by candida. Candida infection has the potential to cause periorbital necrotizing fasciitis in immunocompetent adults<sup>5</sup>. The challenge of the case lied in its varied and non-specific clinical presentation in immunocompetent patients; where patients are frequently misdiagnosed and on some occasions treated with steroids which will worsen the condition and may lead to grave complications<sup>6</sup>.

Although fungal sinusitis commonly occurs in immunocompromised patients, a number of reported cases have shown an increased incidence of fungal sinusitis, both chronic and acute, in immunocompetent patients<sup>7</sup>. Immunocompetent patients have a better prognosis with short course of management<sup>8</sup>. CT and MRI could reveal the sinus pathology; however, none can distinguish between bacterial and fungal infection. Therefore, a biopsy of the sinus tissue is the gold standard for accurate diagnosis<sup>7</sup>. Using steroids to suppress inflammation are contraindicated in most ophthalmic fungal infection. The standard treatment remains surgical extensive debridement of the infection, and systemic chemotherapy, usually with systemic amphotericin B<sup>9,10</sup>.

## CONCLUSION

**Although fungal sinusitis is a very common causes of eye proptosis, accurate identification of the causative pathogen**

**and proper treatment plan, makes it one of the top diagnosis to bear in mind while managing such a condition. Early identification and avoidance of steroids is of utmost importance.**

**Author Contribution:** All authors share equal effort contribution towards (1) substantial contributions to conception and design, acquisition, analysis and interpretation of data; (2) drafting the article and revising it critically for important intellectual content; and (3) final approval of the manuscript version to be published. Yes.

**Potential Conflicts of Interest:** None.

**Competing Interest:** None.

**Sponsorship:** None.

**Acceptance Date:** 19 January 2019.

**Ethical Approval:** Approved by the Department of Ophthalmology, Salmaniya Medical Complex, Bahrain.

## REFERENCES

1. Venugopal M, Sagesh M. Proptosis: The ENT Surgeon's Perspective. *Indian J Otolaryngol Head Neck Surg* 2013; 65(Suppl 2): S247–S250.
2. Carter KD, Graham SM, Carpenter KM. Ophthalmic Manifestations of Allergic Fungal Sinusitis. *Am J Ophthalmol* 1999; 127: 189–195.
3. Coop CA, England RW. Allergic Fungal Sinusitis Presenting with Proptosis and Diplopia: A Review of Ophthalmologic Complications and Treatment. *Allergy and Asthma Proceedings* 2006; 27(1): 72-76.
4. Williamson-Noble FA. Disease of Orbit and its Contents Secondary to the Pathological Condition of Nose and PNS. *Ann R Coll Surg Engl* 1954; 15:46–64.
5. Rath S, Kar S, Sahu SK, et al. Fungal Periorbital Necrotizing fasciitis in an Immunocompetent Adult. *Ophthal Plast Reconstr Surg* 2009; 25(4):334-5.
6. Mukherjee B, Raichura ND, Alam MS. Fungal Infections of the Orbit. *Indian J Ophthalmol* 2016; 64(5):337-45.
7. Heier JS, Gardner TA, Haves MJ, et al. Proptosis as the Initial Presentation of Fungal Sinusitis in Immunocompetent Patients. *Ophthalmology* 1995; 102(5):713-717.
8. Harris GJ, Will BR. Orbital Aspergillosis. Conservative Debridement and Local Amphotericin Irrigation. *Ophthal Plast Reconstr Surg* 1989; 5:207-11.
9. Dortzbach RK, Segrest DR. Orbital Aspergillosis. *Ophthalmic Surg* 1983; 14:240-4.
10. Thomas PA. Current Perspectives on Ophthalmic Mycoses. *Clin Microbiol Rev*; 16(4):730-97.