

# Intra-gastric Balloon Induced Gastric Perforation- Late Presentation >A Combined Endoscopic and Laparoscopic Approach for the Management- Case Report

Fatema Nabeel Nedham, MRCS\* Thamer AlAbbasi, MBBCh BAO ( NUI ) , MRCS (Ireland), FRCS( Canada), FACS(USA)\*\*

## ABSTRACT

Intra-gastric balloon has been used for weight loss purposes since long time, and as with any other procedure it has a lot of variable complications at different time periods. Having an intra-gastric Balloon in place keeps the patient Under major implication to be complaint to using PPI and to stop smoking . All these measures in order to prevent such avoidable complication. that will be presented in the following case report.

Hereby a case representing a 30 years old male with IGB kept a year before presentation and exchanged 3 months back presented with sudden onset epigastric pain with Air under diaphragm on an Erect Chest radiograph and as he was stable a CT abdomen was obtained to reveal gastric perforation.

Therefore he had a combined endoscopic and laparoscopic approach in managing him. The former used to deflate the balloon and the latter for balloon extraction and closure of the perforation.

So we can conclude that the exact mechanism of this adverse effect was not clearly understood. But to avoid further such effect those patient has to be complaint to their PPI and H.pylori has to be treated if present as presence of the balloon could add further source of increased risk of contact induced ulceration on top.

**Keywords:** Perforation, Intra-gastric Balloon, Laparoscopic, Endoscopic, Deflation

## INTRODUCTION

Intra-gastric balloon (IGB) has been introduced in 1980's for weight reduction as an alternative to weight reduction surgeries. There are many types for the IGB such as adjustable Spatz and traditional non adjustable IGB. Gastric perforation is a rare but life threatening complication of intra-gastric balloon. A gastric Ulcer and Perforation could be the Consequence of a constant pressure of the balloon on the gastric wall, explaining why gastric perforation is a medium - or long-term complication leading to the importance to its removal in 6 months<sup>1</sup>. Previously it was managed using Exploratory laparotomy, removal of the balloon and wedge resection of the involved part of the stomach, but nowadays A new less invasive approach for quick recovery, by Using combined Endoscopic and Laparoscopic Approach.

Here in we present a case of late IGB induced gastric perforation in a 30 years old male in BDF hospital in 2021. Where we used combined endoscopic deflation of the balloon and then laparoscopic extraction of the balloon and closure of the perforation and finally peritoneal washout.

## CASE REPORT

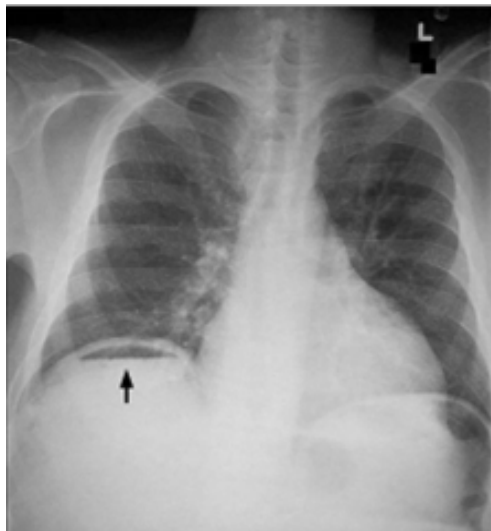
A 30 years old male with a Body Mass Index of 38.5 and a weight of 117 Kg was admitted to the hospital with severe acute onset epigastric pain. He had IGB inserted one year back outside Bahrain and exchanged 3 months before presentation to our facility with his complain. He had an acute onset epigastric pain started few hours before seeking medical attention. It was located in the epigastric region radiating to the left upper quadrant. It was constant in nature with noaggravating or relieving factors. He reported being stable and fine since insertion

of the balloon with no similar such pain. He was non complaint to his Medications including (PPI: Proton Pump Inhibitor) and reported no other associated symptoms. He denied any history of NSAIDs use. He is heavy smoker and underwent appendectomy 10 years back. Physical examination revealed stable vital signs, with severe epigastric tenderness and focal guarding in that region, otherwise the rest of the abdomen was soft and lax. His laboratory test were unremarkable except for high WBC of 22. Chest radiography showed air under diaphragm (Figure 1). Computed tomography with oral gastrograffin and IV contrast showed the balloon within the stomach with free intraperitoneal air (Figure 2). The provisional Diagnosis was Gastric perforation. Patient was taken to the operation theatre for a combined Endoscopic and laparoscopic management. Endoscopy initially done to reveal intra-gastric balloon covered with food particle and evidence of the gastric ulcer 0.5 by 0.5 cm in the lower gastric body (antrum) anterior wall with perforation at its base. The balloon was punctured and 500 ml Saline was drained. Multiple failed endoscopic attempts to remove the deflated balloon were tried but with unsuccessful attempts . So the surgeons introduced the the laparoscope simultaneously, explored the abdominal cavity and the ulcer was identified from the external gastric wall. The perforation was extended cephalad and the intra-gastric balloon was retrieved in an endo-catch bag (Figure 3). Then the perforation with the induced gastrotomy were repaired primary and omental patch was applied to the site of the repair. Vigirous wash done and drain was kept. Patient did well post operatively, started on clear fluids and proceeded to regular oral intake smoothly. He was discharged in a stable condition with no acute Events during his stay. On his follow up he showed up in a very good satisfactory condition, was kept on Regular PPIs, and asked to quit smoking.

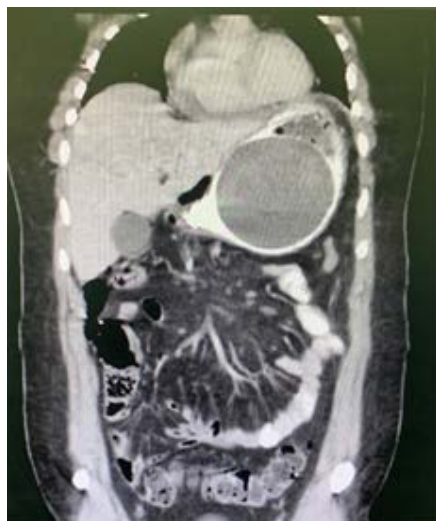
---

\* Surgical Resident  
BDF Hospital  
Bahrain. E-mail: fatemakhonji@hotmail.com

\*\* Consultant Trauma and Acute Care Surgery



**Image 1 :** Erect plain chest xray showing Air Under Diaphragm



**Image 2 :** CT scan of the abdomen with IV and Oral contrast showing the free intraperitoneal air + Intra-gastric Balloon in the stomach with the impression of gastric perforation



**Image 3 :** the intra-gastric balloon after retrieving it

## DISCUSSION

Although IGB is a safe technique but it has some complications. Abdominal pain, Nausea and Gastro esophageal reflux in 33.7, 29 and 18.3% of patients were reported respectively<sup>2</sup>. Spontaneous deflation was evident in variable proportions that will hence lead to migration and Small bowel obstruction (3-23 %) <sup>3-5</sup>. Gastric Ulcer developed in about 0.4% of patients and perforation developed in about 0.21% of patients<sup>6</sup>. So gastric ulcer is the most serious complication as it may lead to perforation and bleeding. Late IGB-induced gastric perforation is a rare major complication presenting as acute abdominal pain weeks to months after the insertion of the balloon<sup>7</sup>.

A review of case series showed that the most common location of IGB induced gastric ulcer will be at the lower anterior gastric body explained by the space that the IGB is occupying in the upper body with food stasis in the fundus leaving the lower body more prone to ulceration<sup>8</sup>. The underlying mechanism is explained as the lower body and the angle of the stomach are more prone to pressure ulceration secondary to the balloon continuous contact to the gastric wall so it will lead to decreased in the microcirculation in those areas<sup>8,9</sup>. That would explain why gastric perforation is a medium - or long-term complication leading to the indication to its removal in 6 months<sup>1</sup>.

This Case report showed a rare late complication after intragastric balloon insertion. One of the weaknesses in this presenting case report is the rarity of this complication and the approach of management is not yet studied whether to choose laparotomy vs minimally invasive approach in the management. On the other Hand it will add to the literature the successful outcome in using this minimally invasive combined endoscopic and laparoscopic approach in managing such complication.

From what have been discussed, the underlying mechanism of intragastric balloon induced perforation is not yet well understood, but it can be prevented by treating any underlying gastritis by being compliant to PPI and treat any underlying H.Pylori infection. Add to that regular follow up for the IGB and regular Exchange of the balloon is necessary. Further studies has to be done for the ideal interval at which the IGB has to be exchanged or removed to avoid any unwanted adverse events<sup>10</sup>.

## CONCLUSION

**So we can conclude that complication resulted from intragastric balloon can be challenging due to the non specific symptoms. So, in order to decrease the complication many steps can be taken such as: balloons should not stay more than 6 months and the patient should be compliant to PPI in last but not least H-pylori eradication is crucial to protect the gastric mucosa from such fatal complication<sup>10</sup>.**

**Authorship Contribution:** All authors share equal effort contribution towards (1) substantial contributions to conception and design, acquisition, analysis and interpretation of data; (2) drafting the article and revising it critically for important intellectual content; and (3) final approval of the manuscript version to be published. Yes.

**Potential Conflict of Interest:** None

**Competing Interest:** None

**Acceptance Date:** 20 January 2022

## REFERENCES

1. Lucidoa FS, Scotti L, Scognamiglio G, et al. Gastric perforation by intragastric balloon: Laparoscopic gastric wedge resection can be a strategy? *Int J Surgery Case Rep* 2020;77:88-91.
2. Abu Dayyeh BK, Edmundowicz SA, Jhonnalagadda S, et al. Endoscopic Bariatric Therapies. *Gastro Intest Endosc* 2015;81:1073-86.
3. Dolhi SB, Micheletto G, Perrini MN, et al. Intragastric balloon: Another option for treatment of obesity and morbid obesity. *Hepatogastroenterol* 2004;51(55):294-7.
4. Herve J, Wahlen CH, Schaeken A, et al. What becomes of patients one year after the intragastric balloon has been removed? *Obes Surg* 2005;15(6):864-70.
5. Loffredo A, Cappuccio M, De Luca M, et al. Three years experience with the new intragastric balloon, and a preoperative test for success with restrictive surgery. *Obes Surg* 2001;11(3):330-3.
6. Dumonceau JM. Evidence based review of bioenteric intragastric balloon for weight loss. *Obes Surg* 2008; 18(12):1611-7.
7. Dayan D, Sagie B, Fishman S. Late Intragastric Balloon Induced Gastric Perforation. *Obes Surg* 2016;26(5):1138-40.
8. Kim H. The Location of Intragastric Balloon Induced Gastric Ulcer. *J Gastroenterol Forecas* 2018;1(1):1001.
9. Abou Hussein BM, Khammas AA, Al Ani AM, et al. Gastric Perforation following intragstric balloon insertion: combined endoscopic and laparoscopic approach for management: case series and review of literature. *Obes Surg* 2016;26(5):1127-32.
10. Yoo KI, Chun HJ, Jeon YT. Gastric Perforation Caused by an Intragstric Balloon: Endoscopic Findings: Case Report. *Clin Endosc* 2017;50(6)602-4.