

Angioleiomyoma: A Rare Cause of Anterior Knee Pain (Case Report)

Al Khalifa Nayla, MB BCh, BAO* Falamarzi Faisal, MD** Al Hashimi Hind, MB BCh, BAO*** Butt Ahsan, MBBS, FRCS TIA****

ABSTRACT

Introduction: Vascular leiomyomas or angioleiomyomas are rare benign tumors of the soft muscles within blood vessels, which are usually found in the lower extremities in females.

Case Presentation: In this case report, we discuss a rare case of subcutaneous vascular leiomyoma of the right knee of a forty-nine-year-old woman who presented with increasing anterior right knee pain and soft tissue swelling. Clinical findings, plain radiographic, ultrasonography and histopathologic findings of the tumor are discussed.

Conclusion: This paper reinforces that angioleiomyomas are rarely diagnosed by clinical features alone, and imaging modalities are essential for early detection and excision.

Keywords: Vascular leiomyoma, Angioleiomyoma, Subcutaneous tumors, Ultrasound

INTRODUCTION

Vascular leiomyoma (angioleiomyoma) is a rare benign tumor of the soft muscles within the blood vessels, typically originating from the tunica media of veins¹⁻³. Angioleiomyomas usually occur in females, during the third or fourth decade, and are commonly located in the lower extremities³. Patients typically present with a painful subcutaneous lump, which may interfere with activities of daily living^{4,5}. Angioleiomyomas make up, approximately, five percent of all soft tissue tumors. A recent systematic review found only thirty cases about angioleiomyomas published in various case reports⁵, a few of them presenting as anterior knee pain³. This case study will serve to present a case of angioleiomyoma, in a Middle Eastern female, presenting as anterior knee pain, along with the radiological, pathological, and clinical findings. The case will, therefore, add to the existing literature by proving that angioleiomyoma may rarely present as anterior knee pain.

CASE REPORT

A forty-nine-year-old female patient presented with right sided anterior knee pain. Her symptoms progressively increased in severity over the last three months. The patient was not a known case of any medical illness or allergies, nor had a past surgical history. The patient was not on any medications. The onset of pain was sporadic and increased upon excessive flexion beyond 100 degrees and kneeling on the floor for prayers. Walking or stair climbing did not affect the pain. There was no previous history of trauma.

On physical examination, patient had mild genu varum bilaterally. There was no sign of inflammation or overlying skin changes. There was no visible swelling over the anterior surface of the knee. There was a palpable nodule about 0.5 cm in size about 2 cm below the inferior pole of the patella in the region of the patellar tendon. The nodule was very tender to touch and was the source of her pain. Patient had a full range of motion and stable knee. Upon palpation, there was mild medial joint line tenderness. All blood tests were within normal range.

Plain radiographs in anteroposterior and lateral views showed mild genu varum with no other bony abnormalities (Figure 1A, 1B). Ultrasound of the knee showed right infra-patellar small subcutaneous nodule, likely benign in nature, with no intra-muscular or intra-articular extension, with presence of mild effusion (Figure 2A-2B). The initial impression was that of a lipoma.

The patient underwent complete, open excision of the soft tissue mass under general anesthesia. Gross examination showed a 10 x 8 x 7 mm solid, well-circumscribed, nodular, and firm tissue with a tan, white cut surface (Figure 3). Microscopic examination showed encapsulated leiomyoma composed of fascicles of bland smooth muscle cells. There was no nuclear atypia, increased mitotic activity, or necrosis identified (Figure 4A-4D).

* Senior House Officer
Internal Medicine Department
Royal College of Surgeons in Ireland
Medical University of Bahrain. E-mail: najlakhalfifa@gmail.com

** Orthopedics Department
Arabian Gulf University
Bahrain

*** Intern
Orthopedics Department
Medical University of Bahrain

**** Consultant Trauma & Orthopedic Surgeon
Fellowship in Adult Reconstruction Surgery
University of Toronto
Canada

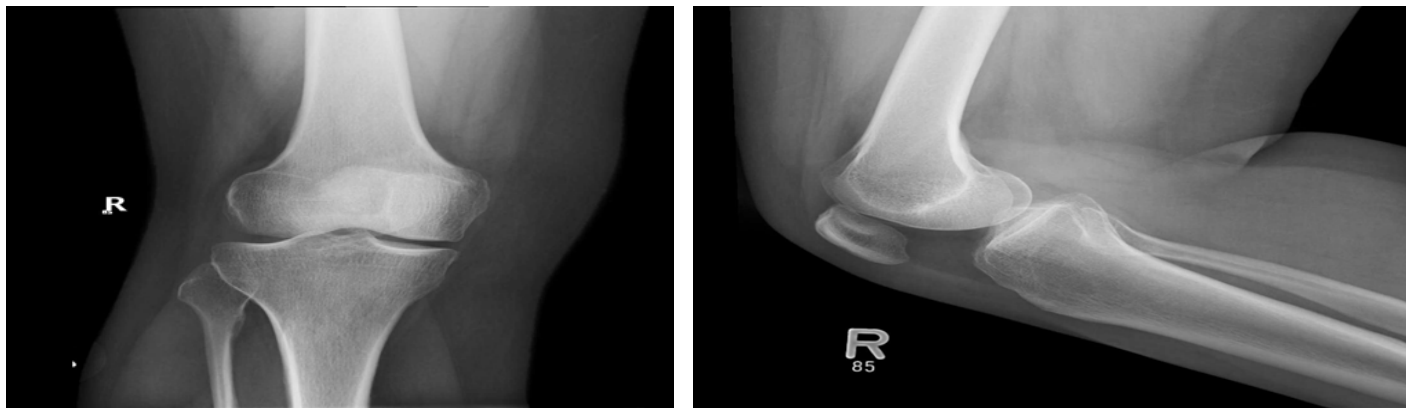

Figure 1A-B: Plain Radiograph of the Right Knee Joint - Pre-operative plain radiograph of the right knee joint, in antero-posterior and lateral views, showed no bony or articular abnormalities, maintained joint space, normal bone density, no fractures, normal soft tissue shadow

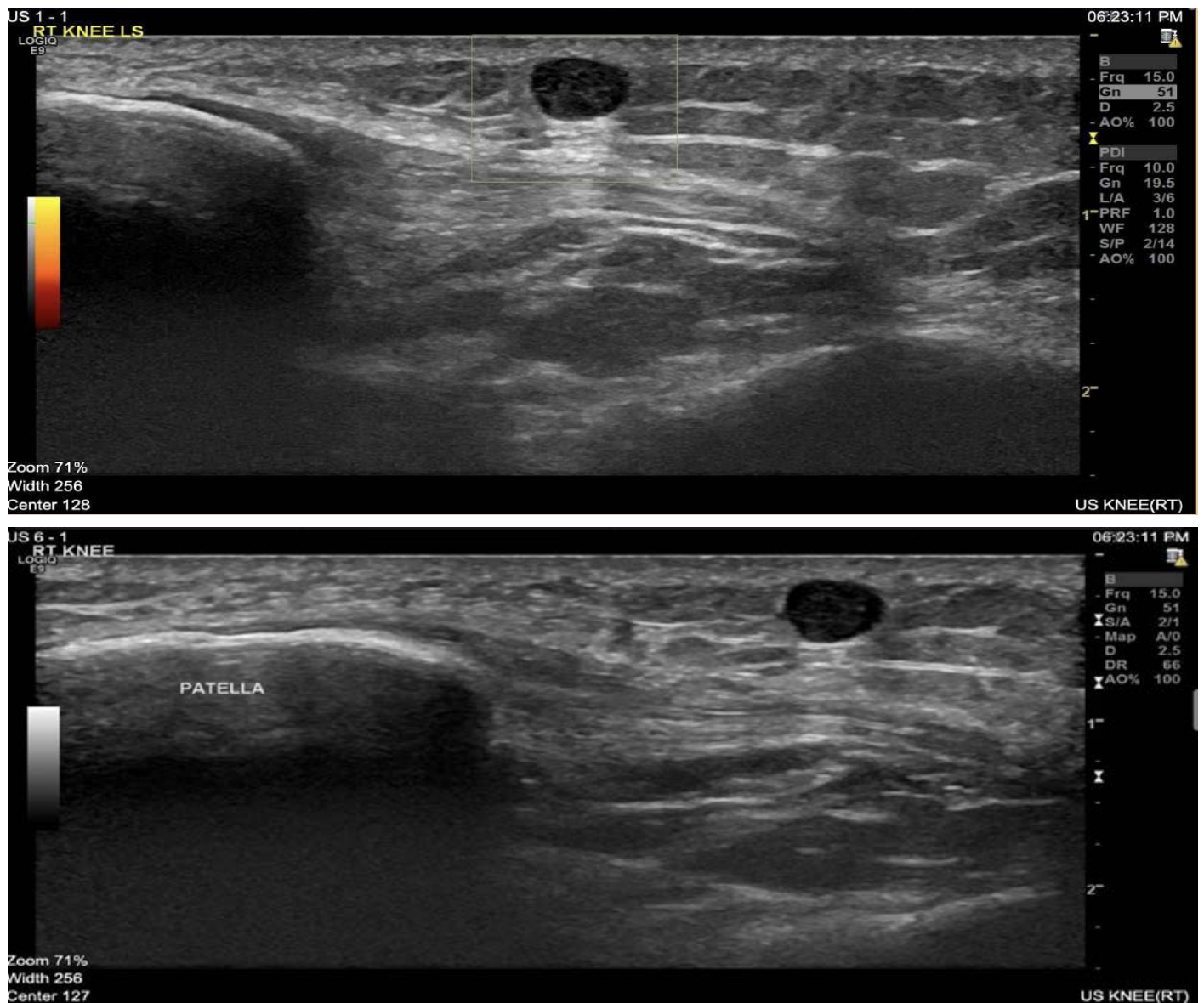


Figure 2 A-B: Ultrasonography of the Right Knee Joint - Pre-operative ultrasonography of the right knee joint showed a right infra-patellar small subcutaneous nodule measuring 4.8 x 3.6 mm in diameter showing hypoechoic contents with no vascularity. Likely benign in nature, with no intra-muscular or intra-articular extension

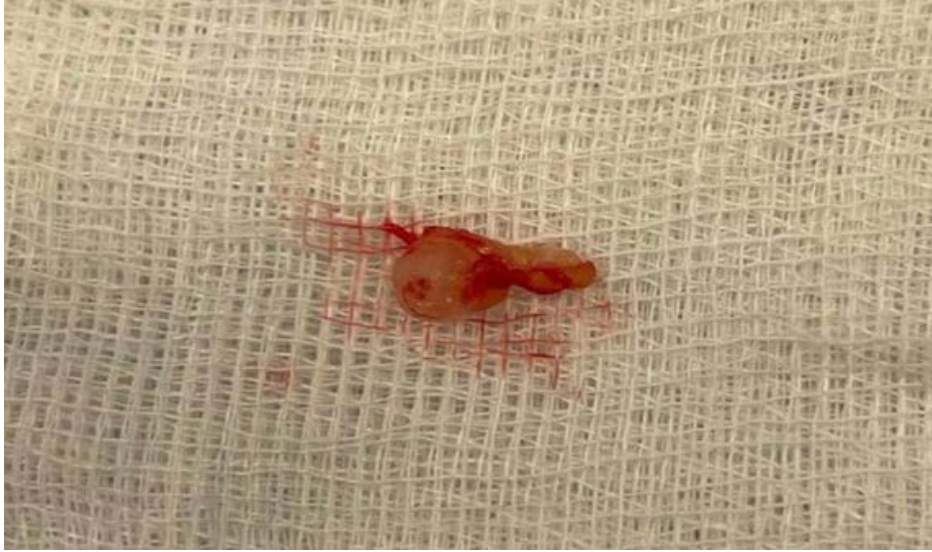

Figure 3: Gross Examination of the Tumor - Post-operative gross examination showed a 10x 8x 7mm solid, well-circumscribed, nodular, and firm tissue with a tan, white cut surface.

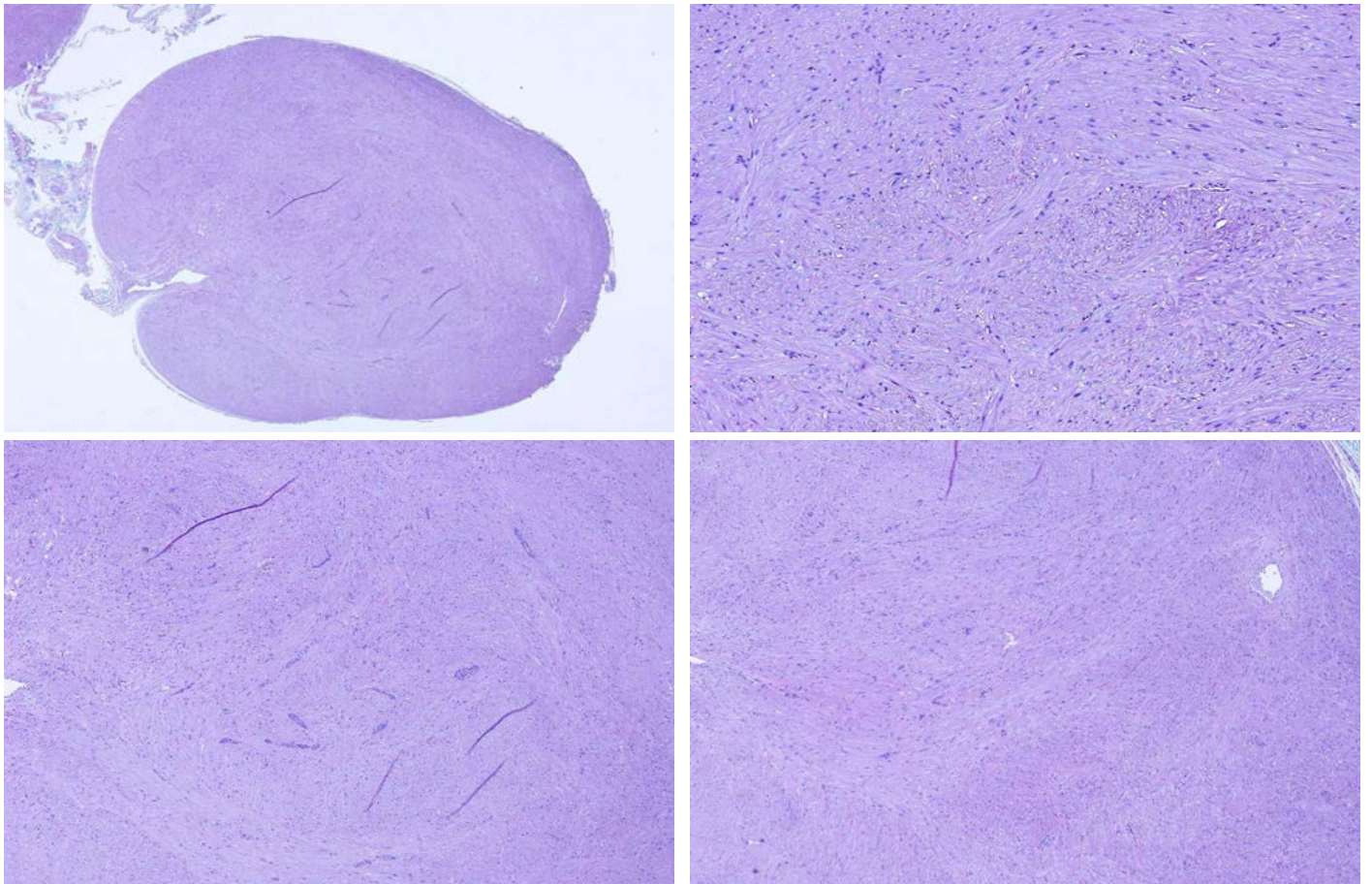


Figure 4A-D: Microscopic Examination of the Tumor - Post-operative microscopic examination showed encapsulated leiomyoma composed of fascicles of bland smooth muscle cells. There was no nuclear atypia, increased mitotic activity, or necrosis identified

DISCUSSION

Vascular leiomyomas or angioleiomyomas, first described by Stout in 1937 are benign tumors of the subcutaneous tissues which originate from the smooth muscles of blood vessels predominantly affecting the lower extremities. In seventy five percent of the cases, lower extremities are involved. Several cases have been reported around the knee^{6,7}. Commonly occurring between the third to fourth decade of life, vascular leiomyomas commonly affect females more than males⁴.

The tumor commonly arises in the deep layers of the dermis and subcutaneous tissue and is histologically composed of smooth muscle bundles contained within a thin fibrous capsule⁶. As described by Morimoto, there are three subtypes: solid, cavernous, and venous, with solid being the most common form⁷.

Commonly presenting with pain and tenderness, glomangiomas do not typically present with the classic triad of glomus tumors, which include pain, tenderness and temperature sensitivity⁸. Differential diagnoses of a leiomyoma include glomus tumor, hemangiomas, angioliopoma, ganglion, schwannoma, giant cell tumor, neurilemoma, traumatic neuromas, and eccrine spiradenoma⁹.

With no specific imaging technique described for definite diagnosis, ultrasound remains the cheapest and most commonly used imaging technique to confirm the presence of a mass and its nature³. Magnetic Resonance Imaging is one of the best choices of imaging as described by Hwang et al¹⁰. Excision of the mass remains the management of choice and aids both in diagnosis and symptoms resolution³.

CONCLUSION

In conclusion, vascular leiomyomas although rare, can occur in the extremities and should be kept in mind when assessing any patient with painful swelling or subcutaneous mass in the lower extremity. It commonly originates from the subcutaneous tissues and is more common in females. No specific imaging technique is unique in the diagnosis, and early detection using imaging modalities is essential for diagnosis and excision of the tumor. Additionally, ultrasound and MRI help in defining the presence of the lesion and surgical planning. Excision of the mass remains the definite plan of management both for diagnosis and relief of symptoms.

Authorship Contribution: All authors share equal effort contribution towards (1) substantial contributions to conception and design,

acquisition, analysis and interpretation of data; (2) drafting the article and revising it critically for important intellectual content; and (3) final approval of the manuscript version to be published. Yes.

Clinical Message: This article is relevant in its confirmation that angioleiomyomas are rarely diagnosed by clinical features alone, and imaging modalities are essential for early detection and excision.

Potential Conflict of Interest: None

Competing Interest: None

Acceptance Date: 24 January 2022

REFERENCES

1. Santucci A, Albini M, Ventura A, et al. Clinical and histological features of vascular leiomyoma of the foot: case report and literature review. *Foot Ankle Surg* 2000;6(4):267-74.
2. Sayit E, Sayit AT, Zan E, et al. Vascular leiomyoma of an extremity: Report of two cases with MRI and histopathologic correlation. *J Clin Orthop Trauma* 2014;5(2):110-4.
3. Aydın E, Coban G, Coşkunoğlu EZ, et al. Vascular Leiomyoma Presenting as Anterior Knee Pain (Case Report). *J Belg Soc Radiol* 2016;100(1):50.
4. Hachisuga T, Hashimoto H, Enjoji M. Angioleiomyoma. A clinicopathologic reappraisal of 562 cases. *Cancer* 1984;54(1):126-30.
5. Montemurro N, Ortenzi V, Naccarato GA, et al. Angioleiomyoma of the knee: An uncommon cause of leg pain. A systematic review of the literature. *Interdisciplinary Neurosurg* 2020;12:100877.
6. Stout AP. Solitary cutaneous and subcutaneous leiomyoma. *Am J Cancer* 1937;29:435-69.
7. Morimoto N. Angiomyoma: a clinicopathologic study. *Med J Kagoshima Univ* 1973;24:663-83.
8. Tony G, Hauxwell S, Nair N, et al. Large plaque-like glomangioma in a patient with multiple glomus tumours: review of imaging and histology. *Clin Exp Dermatol* 2013;38(7):693-700.
9. Cantisani V, D'Ambrosio OM, Marsecano GI, et al. Vascular leiomyoma presenting as medial joint line pain of the knee. *J Ultrasound* 2009;12(4):163-5.
10. Hwang JW, Ahn JM, Kang HS, et al. Vascular leiomyoma of an extremity: MR-imaging-pathology correlation. *Am J Roentgenol* 1998;171:981-5