

Medical Quiz

Saeed Alhindi, MD, CABS, FRCSI*

A one-year-old male patient presented with abdominal distention, vomiting, pain and obstipation of 4 days duration. The patient underwent a transanal pull-through operation shortly after birth. The patient had radiological investigations. Look at the figures below and answer the following questions:

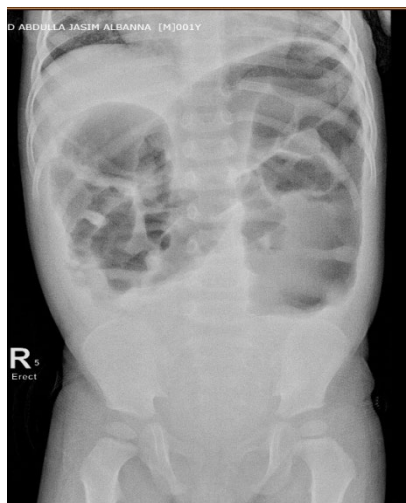


Figure 1

- Q1. Mention the radiological examination in the figure and describe the findings.
- Q2. What is the diagnosis for transanal pull-through surgery?
- Q3. What are the diagnosis and management?

Answers on page 396

* Assistant Professor, Arabian Gulf University
Consultant Pediatric Surgeon, Salmaniya Medical Complex
P.O. Box 12
Kingdom of Bahrain
E-mail: sjalhindi@yahoo.com, sjalhindi@gmail.com