

## **A Teen Lesion of Confluent and Reticulated Papillomatosis (CRP)**

Basem Al Ubaidi, FMAB, MHPE\*

**A nineteen-year-old Bahraini male with a diagnosis of confluent and reticulated papillomatosis received numerous treatments with minimal response. The patient responded favorably to the treatment of oral minocycline for 6 weeks plus topical mupirocin and has remained since then in remission.**

**Confluent and reticulated papillomatosis (CRP) is a rare chronic skin disease which usually affects adolescents. The patient seeks treatment only for cosmetic reasons.**

**The diagnosis of CRP should be considered if the lesion does not respond to antifungal treatment.**

---

\* Consultant

Family Physician

Ministry of Health

Kingdom of Bahrain

Email: bahmed1@health.gov.bh

Confluent and reticulated papillomatosis (CRP) is also known as Gougerot-Carteaud syndrome; it is a rare skin disease typically affecting teenagers. CRP is characterized by small grayish blue hyperkeratotic papillomatosis located on the trunk<sup>1</sup>. Lesions typically begin as hyperkeratotic small papules (1-2 mm) which enlarge and coalesce (4-5 mm) to form grayish brown papules and plaques in a confluent pattern centrally (on the midline region) and with a reticular pattern peripherally. Commonly, it begins on the skin of the intermammary or epigastric region, spreading over a period of weeks or months to axillae, groin, face, neck, arms, trunk, cheeks, pubic area, interscapular region, shoulders, the proximal extremities, and forehead<sup>1-4</sup>. The mucous membranes are spared. Skin markings are sometimes exaggerated, especially in the neck and the axillae (dirty neck and axillae), where the skin may be thickened. Scraping of the lesions produces a fine powdery scale<sup>1</sup>.

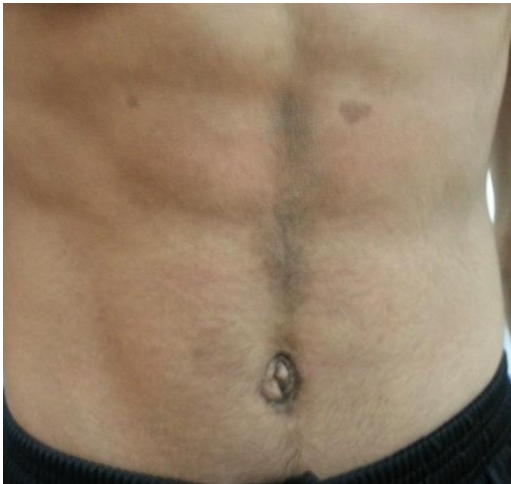CRP may rarely signify an underlying disease (endocrine disturbance, associated obesity, rapid weight gain, disorder of keratinization, ultraviolet reaction or hereditary familial disorder<sup>5,6</sup>). The eruption is a chronic disorder which responds well to treatment, but it has history of exacerbations and relapse; it affects both black and white people<sup>1</sup>.

The ratio of females to males has been reported 2.8:1, but Schwartz thought that the ratio is probably closer to 1.4:1<sup>7</sup>. The onset usually occurs shortly after puberty (18.5-21 years); the mean age of the affected patients in Middle East is 19 years. Most patients are asymptomatic and usually seek treatment for cosmetic reasons<sup>1</sup>.

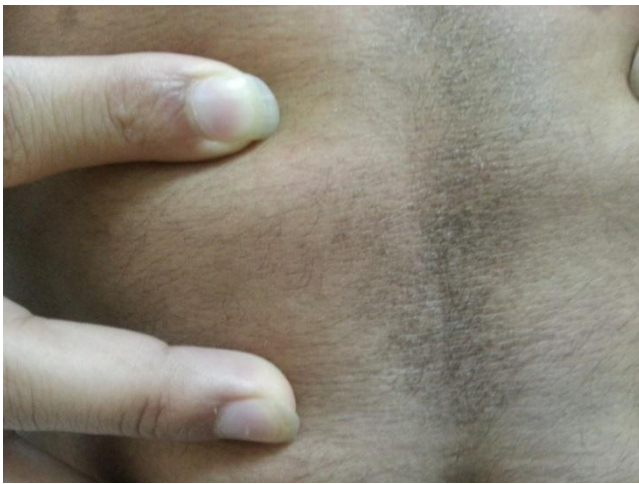The aim of this report is to highlight the clinical and histopathological diagnostic criteria for confluent and reticulated papillomatosis (CRP).

## **THE CASE**

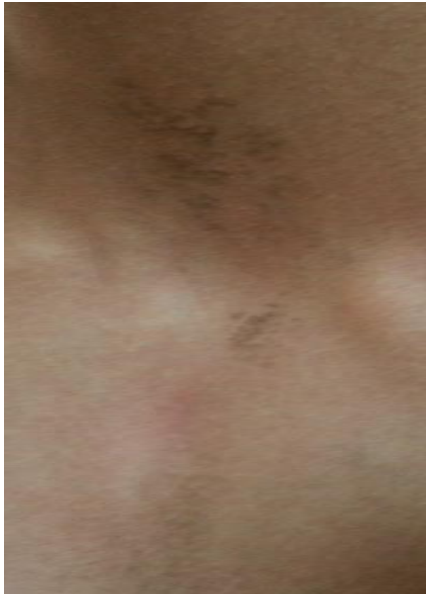A nineteen-year-old Bahraini male presented with grayish blue hyperkeratotic small papillomatosis at midline of the abdominal region as confluent lesion which spread to form a reticular lesion over the suprasternal notch and on the left supraclavicular fossa. The patient was asymptomatic for 6 months, see figures 1, 2, and 3. He had no response to multiple local antifungal treatments. In addition, there was negative potassium hydroxide fungal test for *Pityrosporum orbiculare* or *Pityrosporum ovale* spores.



**Figure 1: Grayish Blue Papules and Plaques in a Confluent Pattern on the Midline of Abdominal Region**

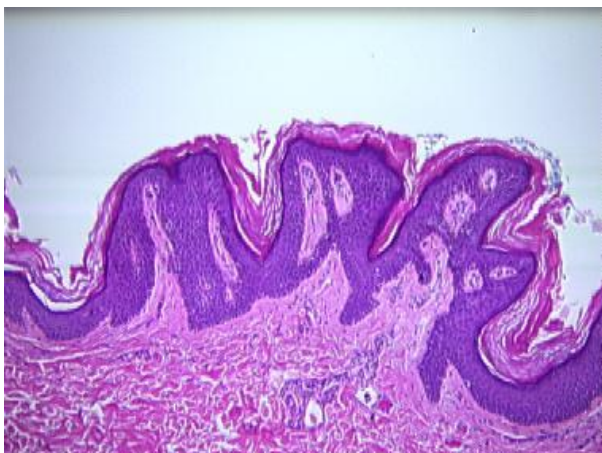


**Figure 2: Close View of Grayish Blue Papules and Plaques in a Confluent Pattern on the Midline Abdominal Region**



**Figure 3: Grayish Brown Papules and Plaques in Reticular Pattern Peripherally (Suprasternal Notch and Supraclavicular Fossa)**

The diagnosis of CRP was confirmed histopathologically and clinically, see figure 4<sup>8</sup>.



**Figure 4: Histopathology Showing Basket-Weave Horn, Papillomatosis of Epiderms With Deep Depressions, Thin Epidermis and Rete Ridges, Fusion of Adjacent Rete Ridges Forming X and Y Configurations and Slight Hyperpigmentation of the Basal Layer**

The patient responded favorably on treatment of oral minocycline 100 mg twice daily for 6 weeks with topical mupirocin 2% (bactroban).

## **DISCUSSION**

The main criteria for diagnosis of CRP are the following: grayish brown macules and the patches appearing as reticulated and papillomatous involving the upper trunk and neck, fungal staining of scales is negative, no response to antifungal treatment and excellent response to minocycline<sup>8</sup>.

Educating the patient that CRP is a disorder of the skin which results in cosmetic disfigurement and has no adverse systemic effects is essential<sup>1</sup>. Our patient showed successful response to the treatment of oral minocycline 100 mg twice daily for 6 weeks with topical mupirocin 2% (bactroban)<sup>9,10</sup>.

Other modalities of antibacterial treatments include fusidic acid 1000 mg daily, clarithromycin 500 mg daily, erythromycin 1000 mg daily, tetracycline 500 mg twice daily, and cefdinir 300 mg twice daily. Other treatments include isotretinoin, acitretin, and etretinate, selenium sulfide, ketoconazole cream, tazarotene, tacalcitol, and calcipotriene (calcipotriol)<sup>11</sup>.

## CONCLUSION

**CRP is skin disease typically affecting adolescents. Family physician should be familiar with the criteria of CRP diagnosis. The presented case of CRP showed good response to the treatment with minocycline.**

---

**Potential Conflicts of Interest:** None.

**Competing Interest:** None.

**Sponsorship:** None.

**Submission Date:** 21 May 2014.

**Acceptance Date:** 5 January 2015.

**Ethical Approval:** Approved by North Muharraq Health Center, MOH, Bahrain.

## REFERENCES

1. Tamraz H, Raffoul M, Kurban M, et al. Confluent and Reticulated Papillomatosis: Clinical and Histopathological Study of 10 Cases from Lebanon. *J Eur Acad Dermatol Venereol* 2013; 27(1):e119-23.
2. Bhagwat PV, Tophakhane RS, Shashikumar BM, et al. Three Cases of Dowling Degos Disease in Two Families. *Indian J Dermatol Venereol Leprol* 2009; 75(4):398-400.
3. Lee D, Cho KJ, Hong SK, et al. Two Cases of Confluent and Reticulated Papillomatosis with an Unusual Location. *Acta Derm Venereol* 2009; 89(1):84-5.
4. Kim BS, Lim HJ, Kim HY, et al. Case of Minocycline-Effective Confluent and Reticulated Papillomatosis with Unusual Location on Forehead. *J Dermatol* 2009; 36(4):251-3.
5. Zhang CH, Zhang C, Wu J, et al. Confluent and Reticulated Papillomatosis Associated with Hyperthyroidism. *Eur J Dermatol* 2010; 20(6):833-5.
6. İnalöz HS, Patel GK, Knight AG. Familial Confluent and Reticulated Papillomatosis. *Arch Dermatol* 2002; 138(2):276-7.
7. <http://emedicine.medscape.com/article/1106748-differential>. Accessed on December 2013.
8. Davis MD, Weenig RH, Camilleri MJ. Confluent and Reticulate Papillomatosis (Gougerot-Carteaud Syndrome): A Minocycline-Responsive Dermatoses without Evidence for Yeast in Pathogenesis. A Study of 39 Patients and a Proposal of Diagnostic Criteria. *Br J Dermatol* 2006; 154(2):287-93.

9. Rodriguez-Carreón AA, Arenas-Guzmán R, Fonte-Avalos V, et al. Confluent and Reticulated Gougerot-Carteaud Papillomatosis: A Case Report of an Excellent Response to Minocycline. *Gac Med Mex* 2008; 144(1):67-70.
10. Gonul M, Cakmak SK, Soylu S, et al. Successful Treatment of Confluent and Reticulated Papillomatosis with Topical Mupirocin. *J Eur Acad Dermatol Venereol* 2008; 22(9):1140-2.
11. Scheinfeld N. Confluent and Reticulated Papillomatosis: A Review of the Literature. *Am J Clin Dermatol* 2006; 7(5):305-13.