

Pulmonary Tuberculosis Associated with Autoimmune Hemolytic Anemia

Rana Al-Taweel, MD* Dalal Burshaid, MB, BCh, BAO**

Shams Al-Turky, MD, MBBS, PhD***

Pulmonary tuberculosis could be associated with certain types of anemia, such as normocytic normochromic anemia and microcytic hypochromic anemia; however, it is rarely associated with autoimmune hemolytic anemia.

We report a case of a child with pulmonary tuberculosis associated with autoimmune hemolytic anemia and iron deficiency anemia which was resolved with anti-tuberculosis medications, isoniazid, pyrazinamide, rifampicin and ethambutol.

Bahrain Med Bull 2017; 39(3): 187 - 188

Pulmonary tuberculosis is considered a common disease worldwide. According to the WHO in 2013, 9 million people had TB and 1.5 million died globally^{1,2}. In 2014, WHO reported that approximately 550,000 of the 9 million were children under 15 years of age and the estimated TB death among that group was 80,000; approximately 75% of those cases occurred in developing countries^{3,4}. Similar cases were reported in adult and pediatric age groups in the Kingdom of Saudi Arabia⁵.

Mycobacterium tuberculosis (MTB) could cause pulmonary and extra-pulmonary manifestations; among the extrapulmonary features is the involvement of the hematology system and it is manifested as anemia.

Pulmonary tuberculosis cases were associated with normocytic normochromic anemia even though hypochromic microcytic anemia is not uncommon⁶. However, there were a few reported cases of autoimmune hemolytic anemia.

The aim of this report is to present a case of pulmonary tuberculosis in a twelve-year-old female who had autoimmune hemolytic anemia as well as iron deficiency anemia. To the best of our knowledge, it is one of few pediatric reported cases worldwide.

THE CASE

A twelve-year-old Saudi female presented with a history of intermittent high-grade fever, productive cough of brownish to greenish sputum, pallor and weight loss (5 kg) for three weeks.

A history of increased pallor, palpitation, malaise, fatigue, reduced activity and appetite with a history of bilateral wrists, right knee and ankle pain was documented.

No history of abdominal pain, vomiting, night sweats, shortness of breath, cyanosis, joint erythema, joint swelling or any change in neurological status was elicited.

The patient gave a history of recent travel to the west provenance of KSA and a history of contact with a pulmonary TB patient.

On physical examination, the patient appeared pale with a temperature of 39.4C° and tachycardia of 140 b/min. Chest auscultation revealed equal bilateral air entry with crepitation on the left lower lung. The remainder of her examination was normal with no organomegaly or palpable lymph nodes.

Laboratory tests were as follows: WBC 9.5 k/uL (neutrophils 68%, band 1%, lymphocytes 24%, monocyte 7%), platelet count 657,000, hemoglobin 6.4 g/dL, hematocrit 24%, MCV 49.3 fL, MCH 13.1 pg, reticulocyte count 1.3%, direct Coombs test positive for IgG and negative for C3d, albumin 2.9 g/dL, LDH 530 u/L, ESR 120 mm/h, HIV screen negative, malaria smear negative, brucellosis antibodies and culture negative; virus serology, such as EBC, CMV, Hepatitis B and C were negative; iron level and ferritin were low with high TIBC. Chest X-ray revealed cavitation in the posterior left lower lobe and chest CT revealed cavitation and tree-in-bud pattern, see figures 1 and 2.

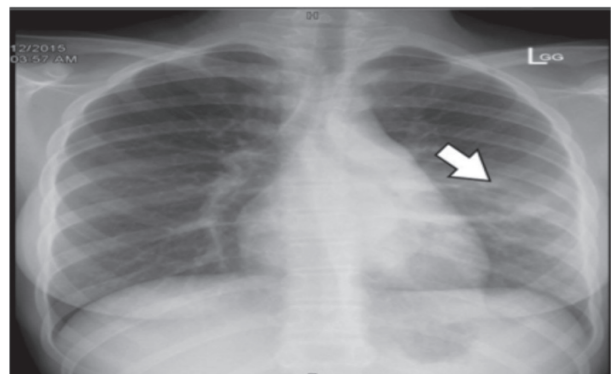


Figure 1: CXR Showing Cavitation in the Posterior Left Lower Lobe

* Senior Resident
** Junior Resident
*** Consultant Pediatrician
Department of Pediatrics
King Fahd Hospital of the University
Al Khobar, Kingdom of Saudi Arabia
E-mail: dalal.burshaid@gmail.com

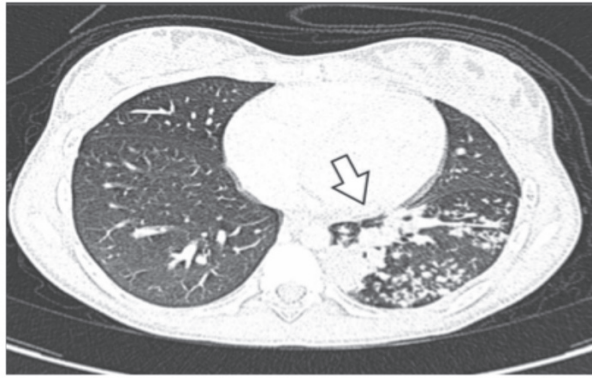


Figure 2: Cavitation with Tree-in-Bud Pattern

Sputum for acid-fast bacilli and mycoplasma culture was positive for both. Tuberculin skin test was 22 mm; therefore, the patient was diagnosed pulmonary TB with autoimmune hemolytic anemia. Anti-TB medications were initiated (isoniazid, pyrazinamide, rifampicin and ethambutol); the patient became afebrile within one week.

The patient was transfused with packed RBC twice upon admission and one week later, with no subsequent decline of hemoglobin. She did not require any further medication other than anti-TB. Coombs test normalized after two months of anti-TB medication.

DISCUSSION

Anemia is one of the extra-pulmonary TB complications; normocytic normochromic anemia is a common complication compared to microcytic hypochromic anemia. Anemia is a result of nutritional deficiency, malabsorption, inflammatory mediator and iron deficiency^{6,7}.

The most common type of anemia associated with TB is normocytic normochromic anemia and it is rarely associated with autoimmune hemolytic anemia. Few cases were reported in Pediatrics age group⁸⁻¹⁰. In our patient, the diagnosis of open TB was confirmed by clinical, radiological and microbiological evidence. Laboratory tests revealed low hemoglobin with positive Coombs test and high LDH which confirms autoimmune hemolytic anemia. However, MCV was low, which was supposed to be high in autoimmune hemolytic anemia; therefore, iron profile was performed and revealed iron deficiency anemia which explain the low MCV and low MCH which indicates that the patient had two types of TB associated anemia, autoimmune hemolytic anemia and microcytic hypochromic anemia due to iron deficiency anemia. Coombs test was positive for IgG and negative for C3d, which indicated warm autoantibodies but not cold agglutinin which is usually positive to C3d. The mechanism of autoantibody formation and hemolysis in TB still unclear¹¹.

CONCLUSION

The association of autoimmune hemolytic anemia and pulmonary TB is rare. In our case, the patient condition resolved with anti-tuberculosis medications alone without the need to use further medications, such as corticosteroid

or immunoglobulin; that supports that hemolytic anemia is autoimmune in nature.

Author contribution: All authors share equal effort contribution towards (1) substantial contributions to conception and design, acquisition, analysis and interpretation of data; (2) drafting the article and revising it critically for important intellectual content; and (3) final approval of the manuscript version to be published. Yes.

Potential Conflicts of Interest: None.

Competing Interest: None.

Sponsorship: None.

Acceptance Date: 7 July 2017.

Ethical Approval: Approved by Department of Pediatrics, King Fahd Hospital of the University, Al Khobar, KSA.

REFERENCES

1. World Health Organization. Global Tuberculosis Report 2013. http://apps.who.int/iris/bitstream/10665/91355/1/9789241564656_eng.pdf Accessed on 18 November 2013.
2. Horsburgh CR, Jr. Epidemiology of Tuberculosis. UpToDate 2015. <https://www.uptodate.com/contents/epidemiology-of-tuberculosis> Accessed in March 2016.
3. World Health Organization. Global Tuberculosis Report 2014. http://www.who.int/tb/publications/global_report/gtbr14_executive_summary.pdf Accessed on 7 July 2015.
4. Adams LV, Starke JR. Tuberculosis Disease in Children. UpToDate 2015. <https://www.uptodate.com/contents/tuberculosis-disease-in-children> Accessed on 7 July 2015.
5. Al-Orainey I, Alhedaithy MA, Alanazi AR, et al. Tuberculosis Incidence Trends in Saudi Arabia over 20 Years: 1991-2010. *Ann Thorac Med* 2013; 8(3):148-52.
6. Lee SW, Kang YA, Yoon YS, et al. The Prevalence and Evolution of Anemia Associated with Tuberculosis. *J Korean Med Sci* 2006; 21(6):1028-32.
7. Baynes RD, Flax H, Bothwell TH, et al. Red Blood Cell Distribution Width in the Anemia Secondary to Tuberculosis. *Am J Clin Pathol* 1986; 85(2):226-9.
8. Bakhshi S, Rao IS, Jain V, et al. Autoimmune Hemolytic Anemia Complicating Disseminated Childhood Tuberculosis. *Indian J Pediatr* 2004; 71(6):549-51.
9. Gupta V, Bhatia BD. Abdominal Tuberculosis with Autoimmune Hemolytic Anemia. *Indian J Pediatr* 2005; 72(2):175-6.
10. MKhemiri, SZouari, SBarsaoui. Autoimmune Bicytopenia in Pulmonary Tuberculosis. Report of a Pediatric Case. *Respiratory Medicine CME* 2008; 1(4):281-3.
11. Shetty SK, Joshi SS, Shenoy VM, et al. An Interesting Presentation of Auto Immune Hemolytic Anemia & Review of Literature. *International Journal of Biomedical Research* 2013; 4(7): 355-7.